

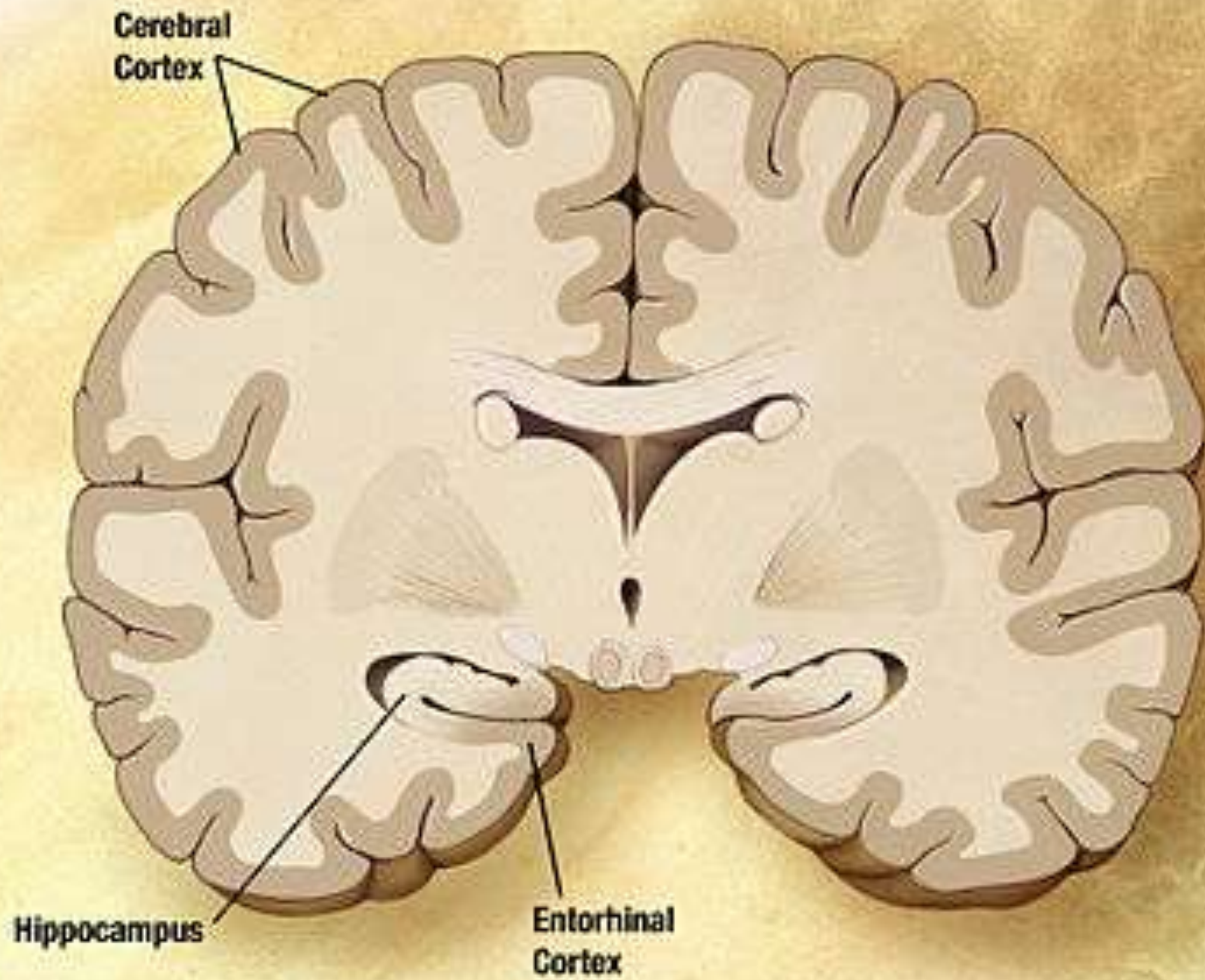


Fantastic Removable Prosthodontics

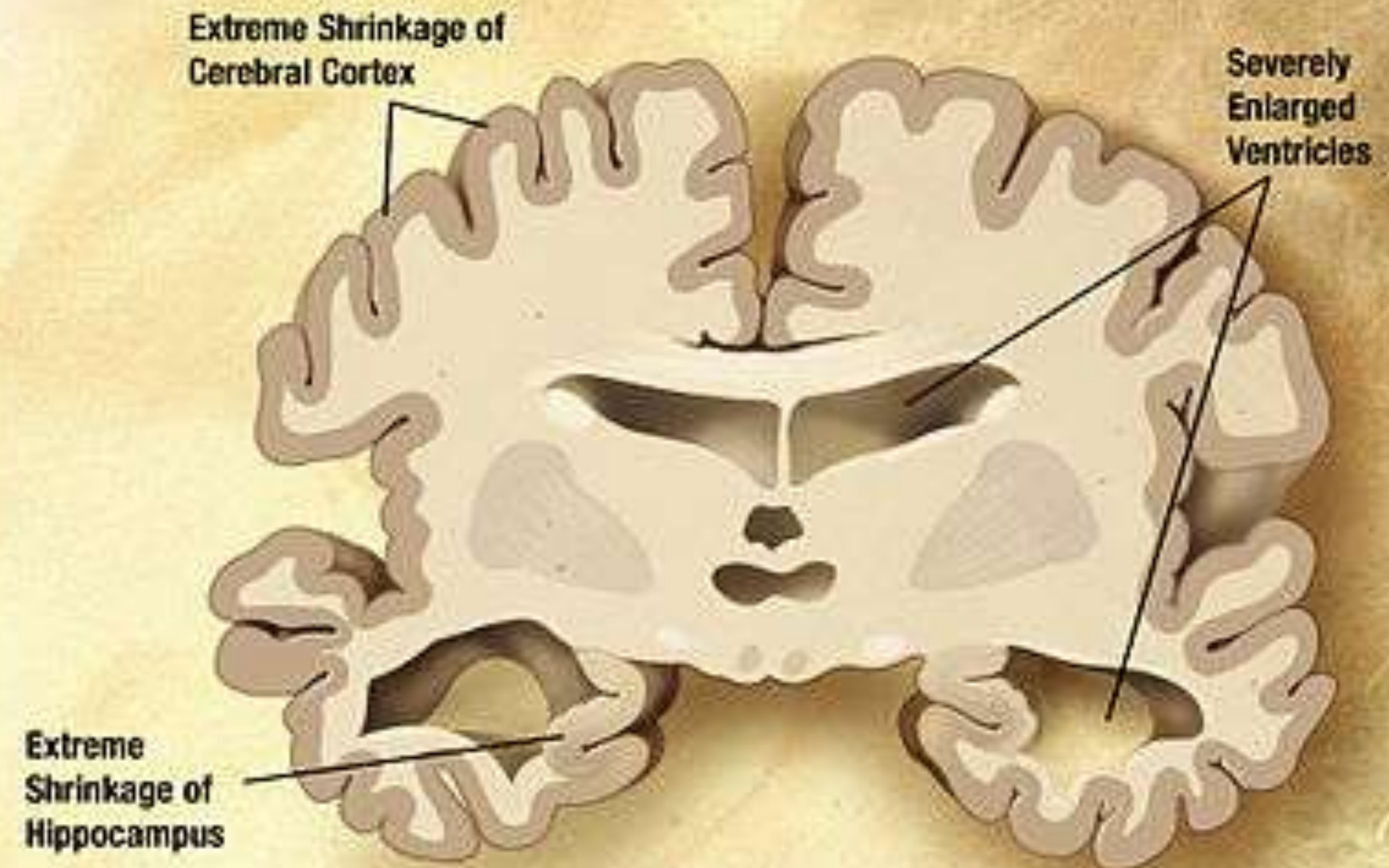
Finlay Sutton


Removable prosthodontics
is difficult

Normal



Alzheimers





1


Technician



Rowan Garstang



Sam Hesketh

A large, stylized number 2 is centered within a white, 3D-rendered column structure. The column has a wide base, a narrower shaft, and a wide top. The number 2 is black and serifed. The entire structure is set against a solid black background.

2

Mentor



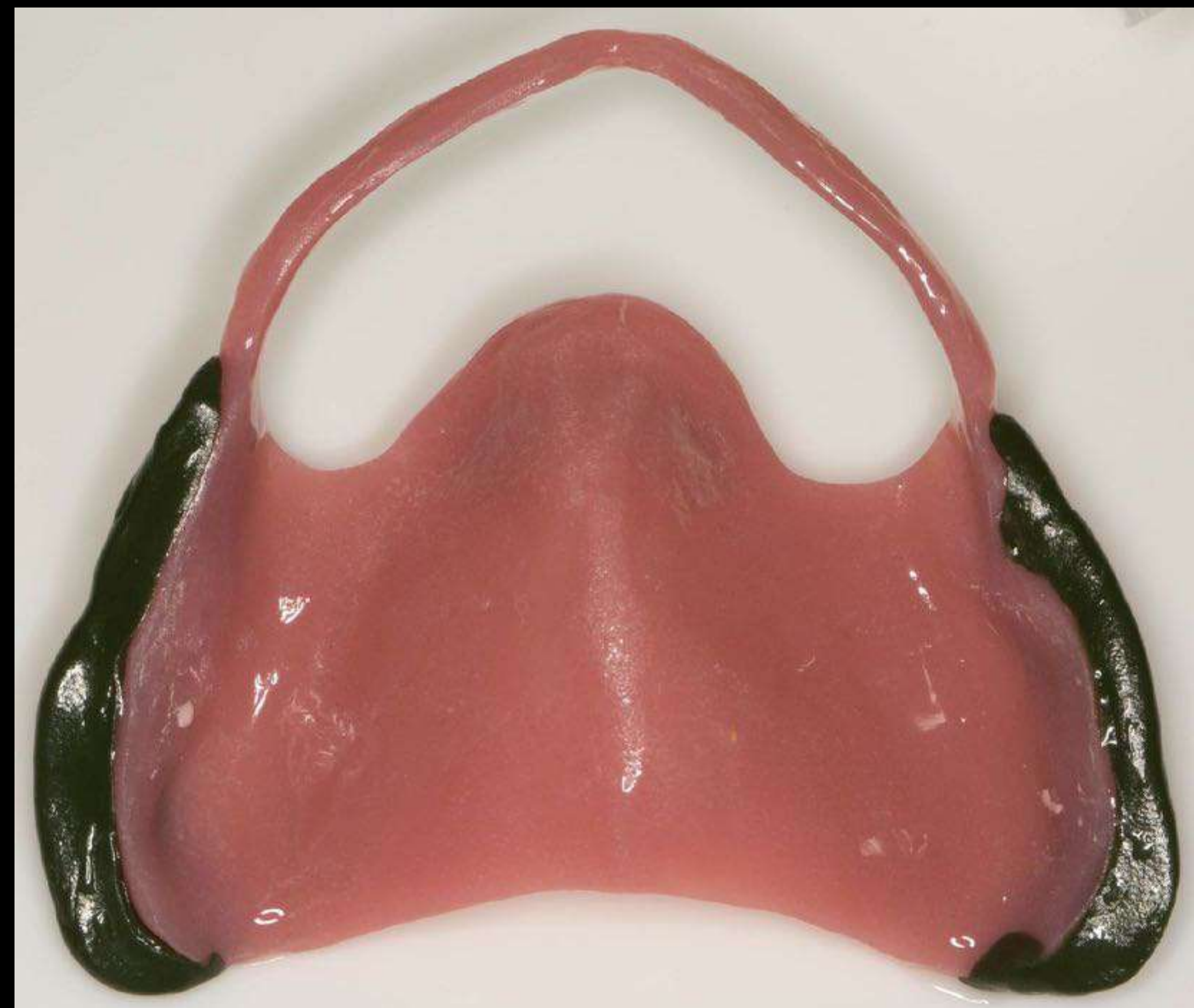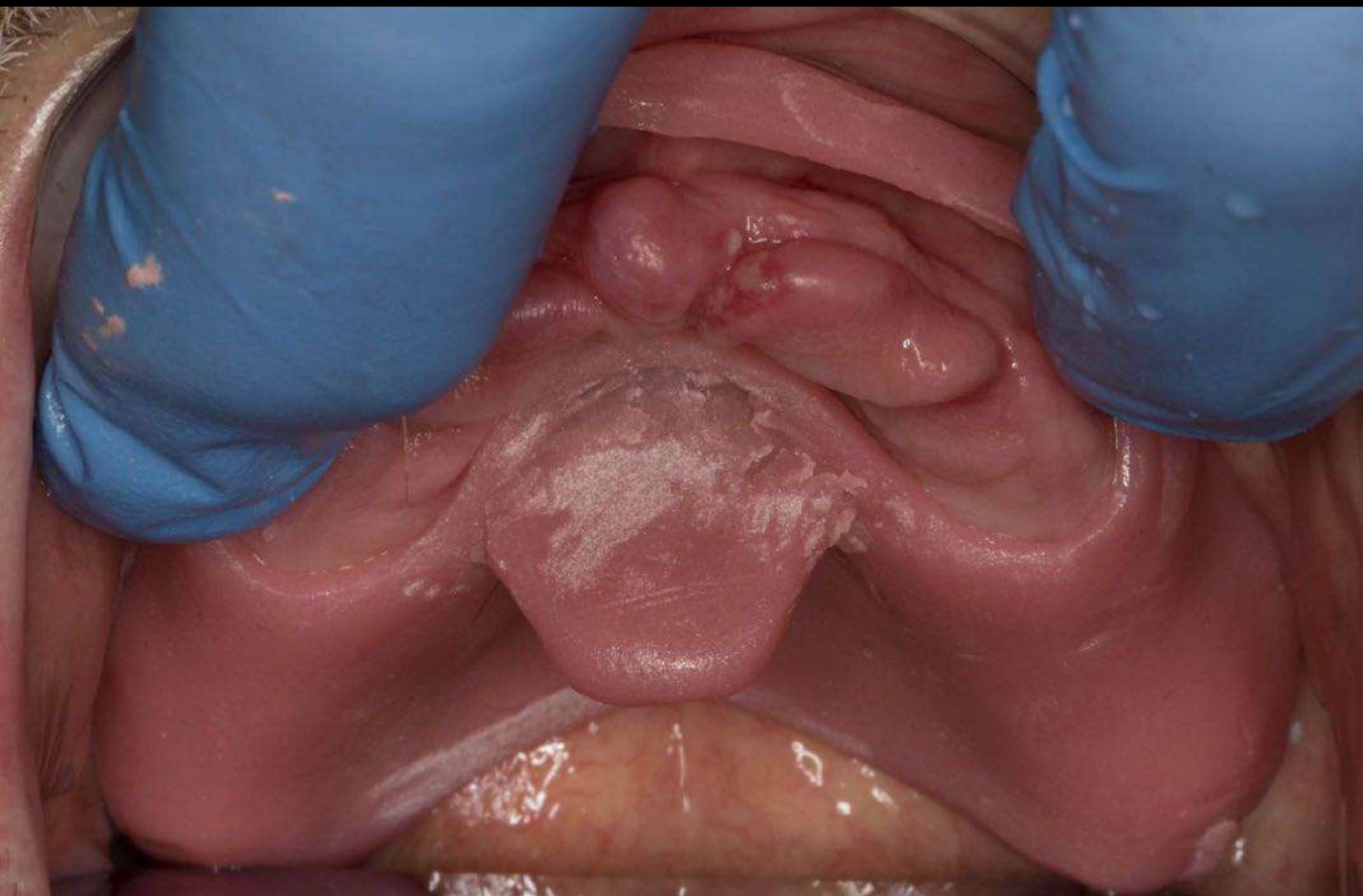
Dr John Besford

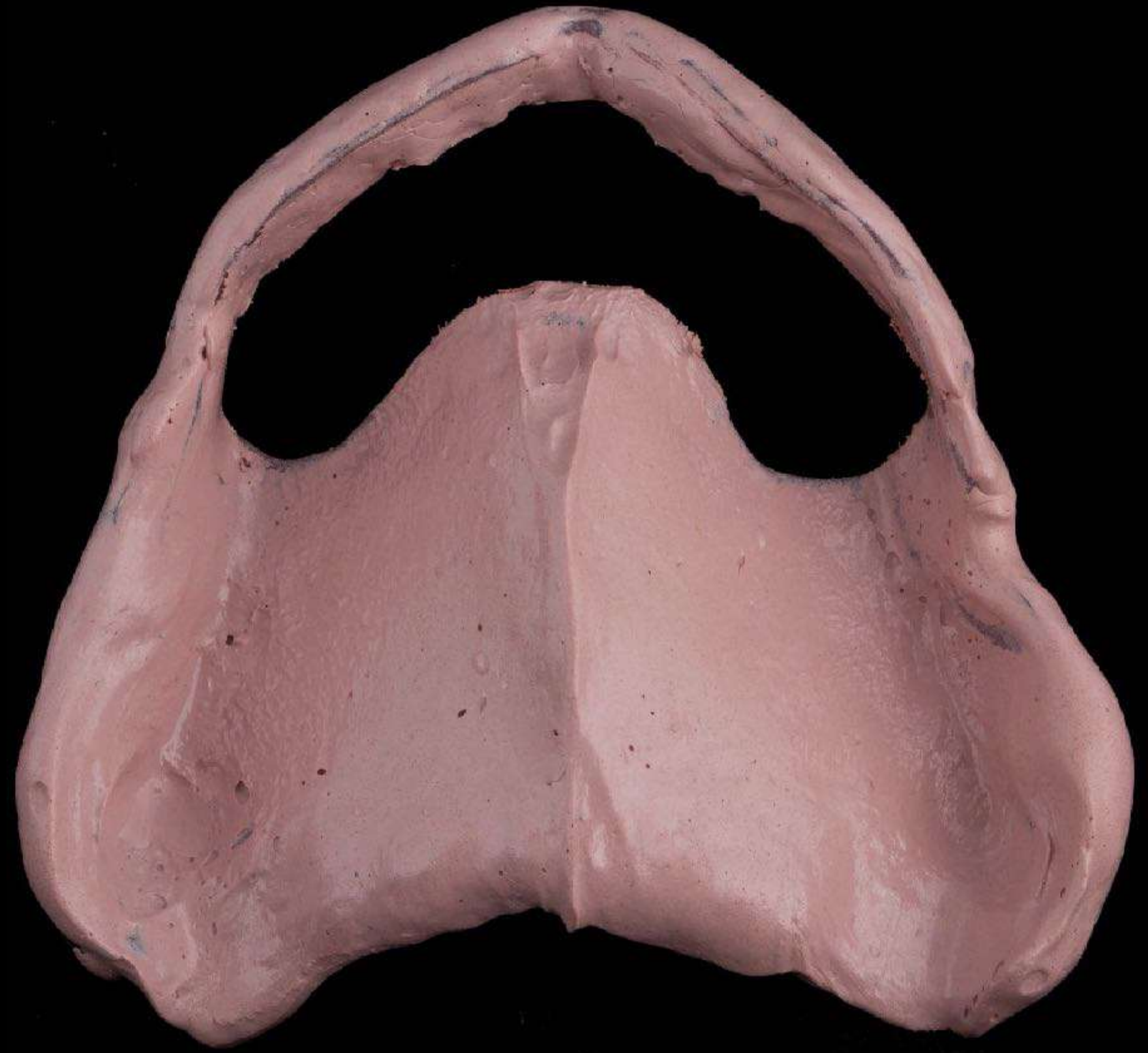
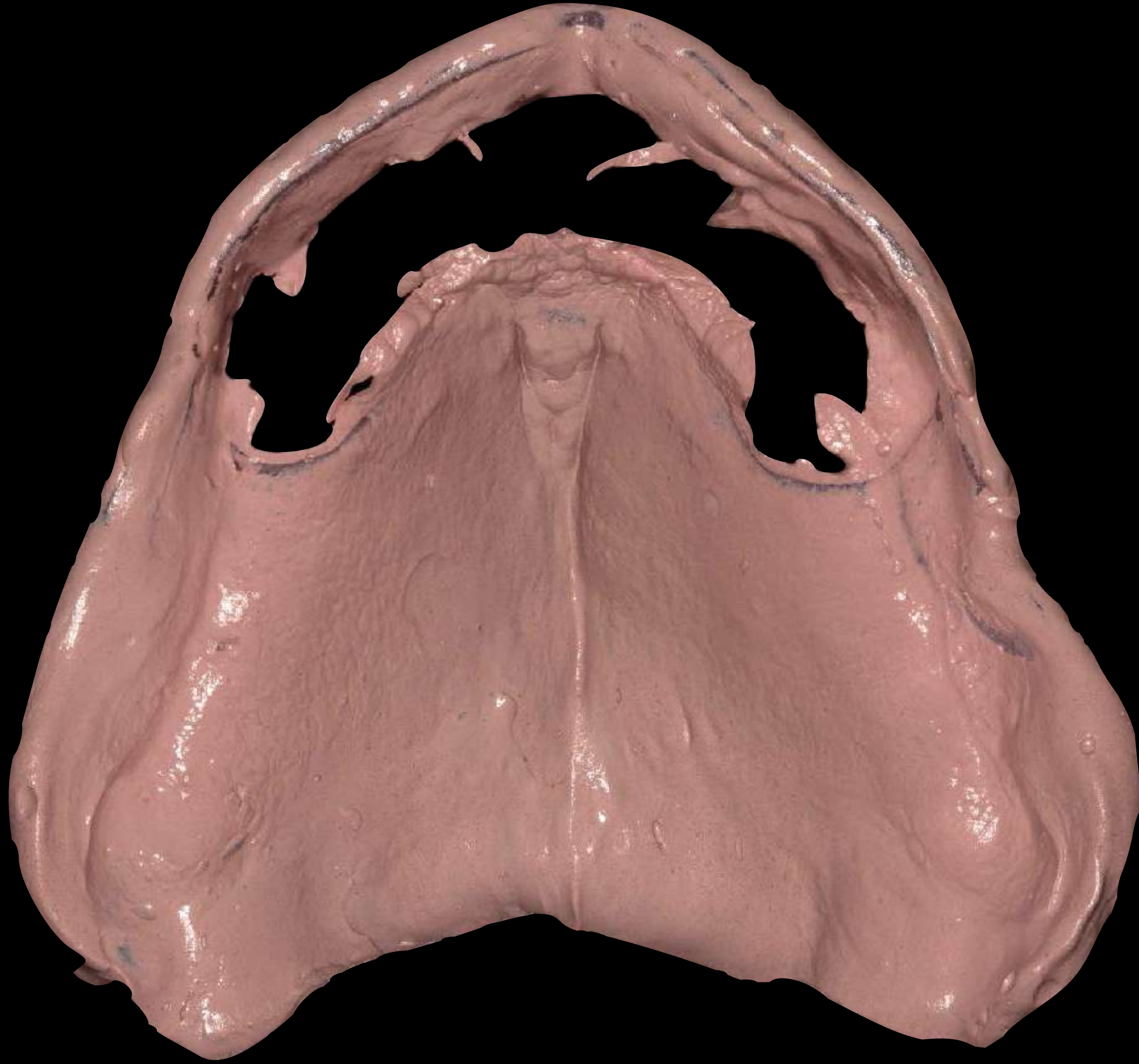My mentor

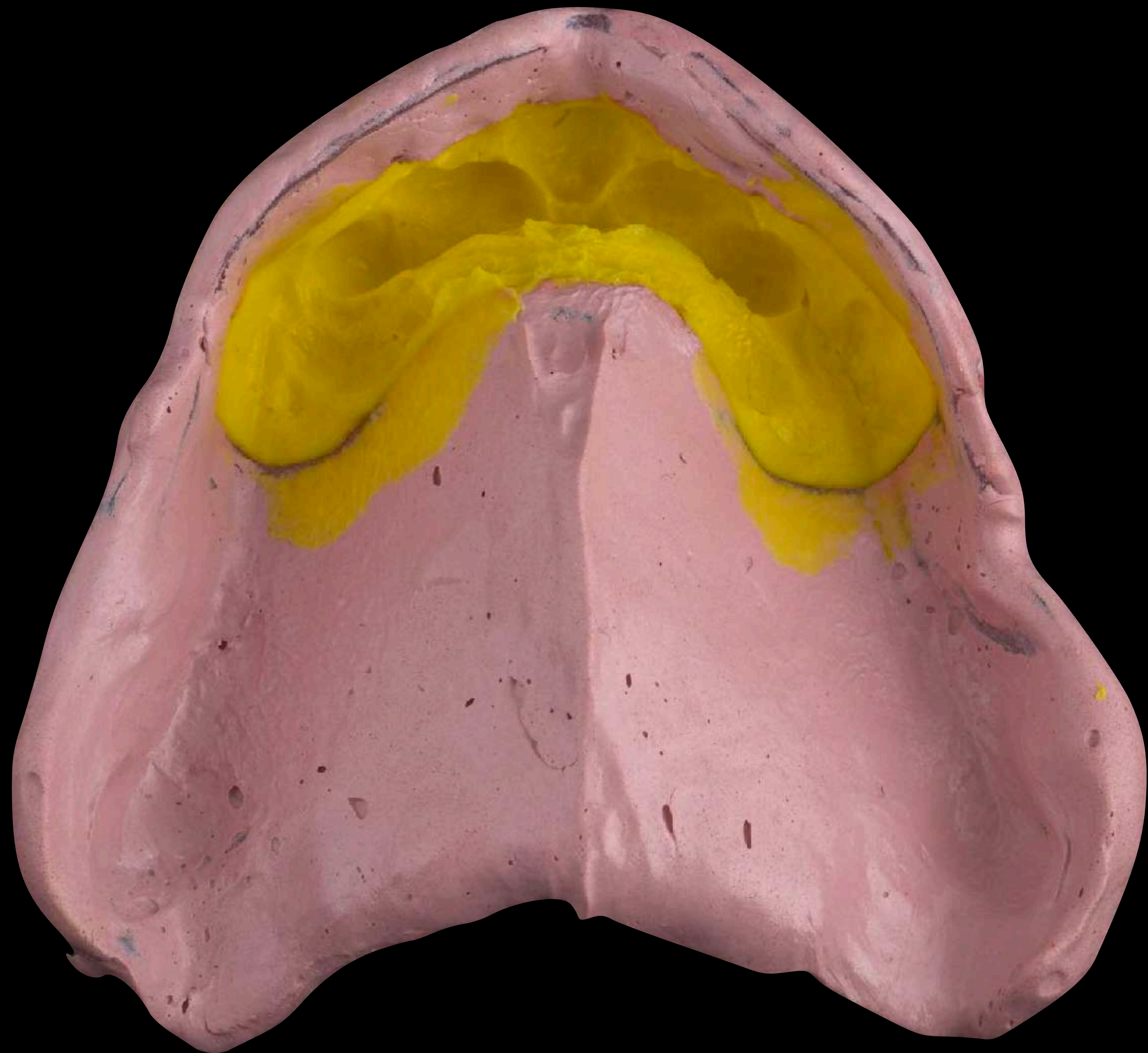
A large, stylized number 3 is centered within a white, 3D-rendered column structure. The column has a wide base, a narrower middle section, and a wide top section, all with a slight gradient and shadow. The background is solid black.

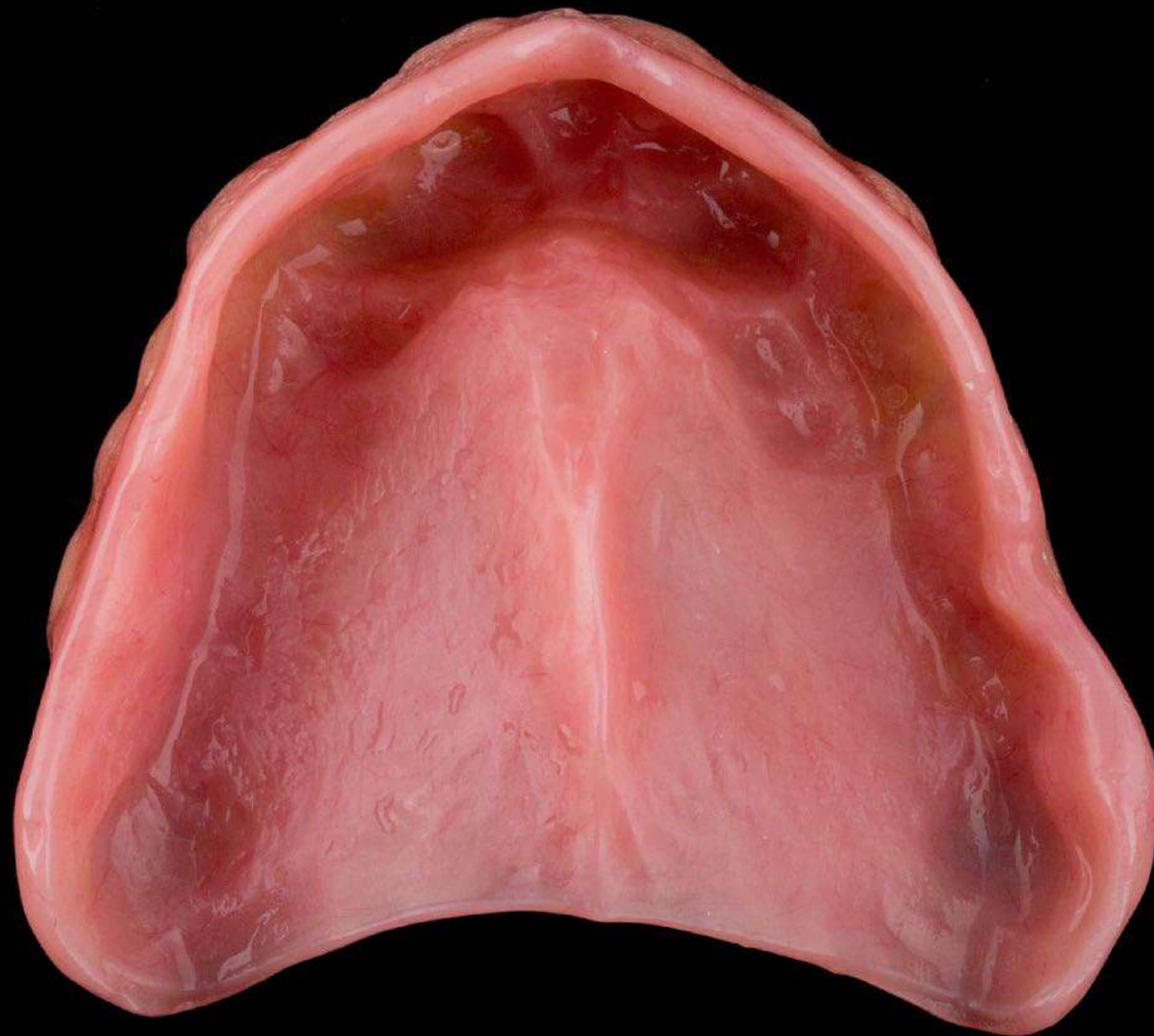
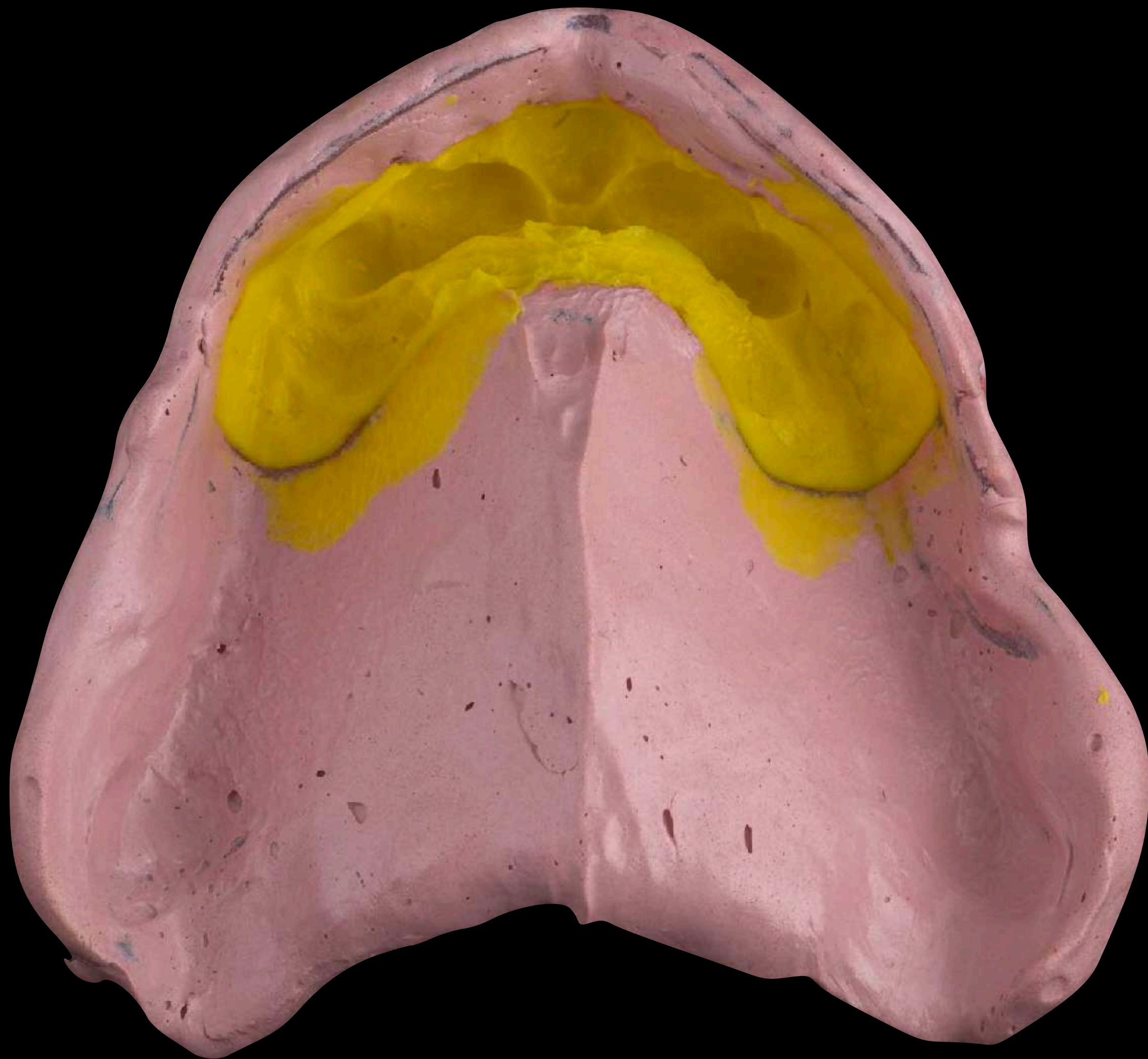
3

Impression
making

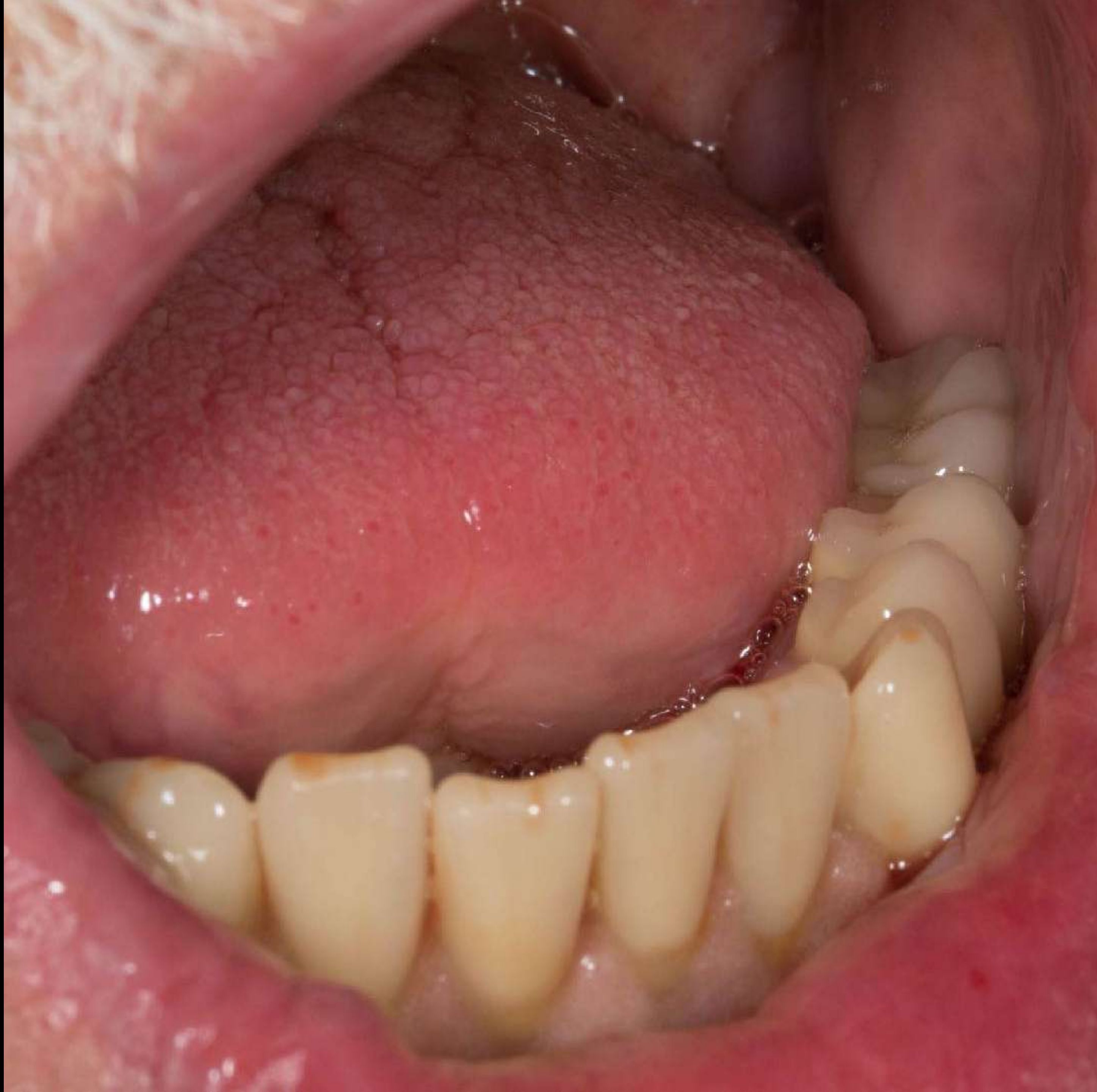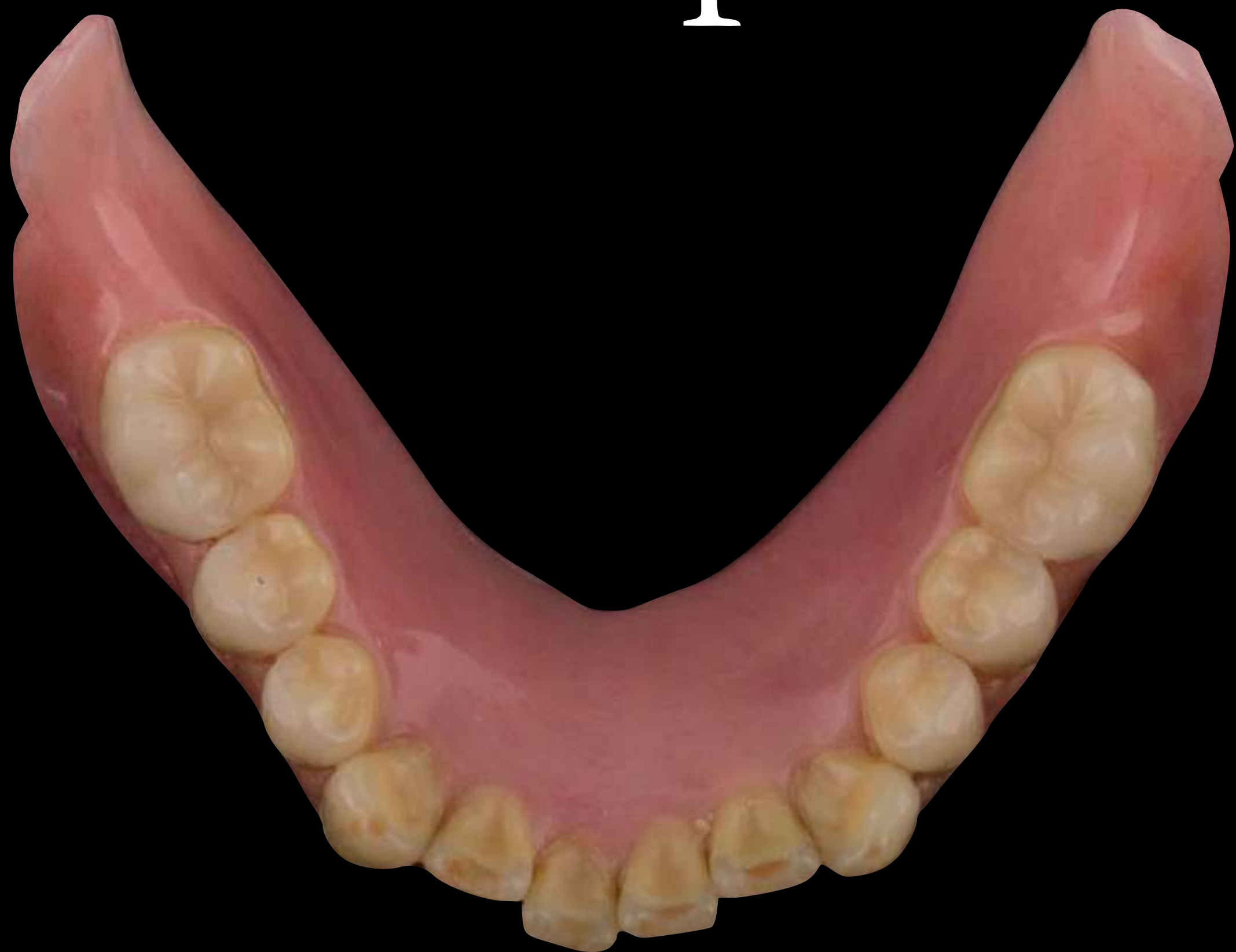



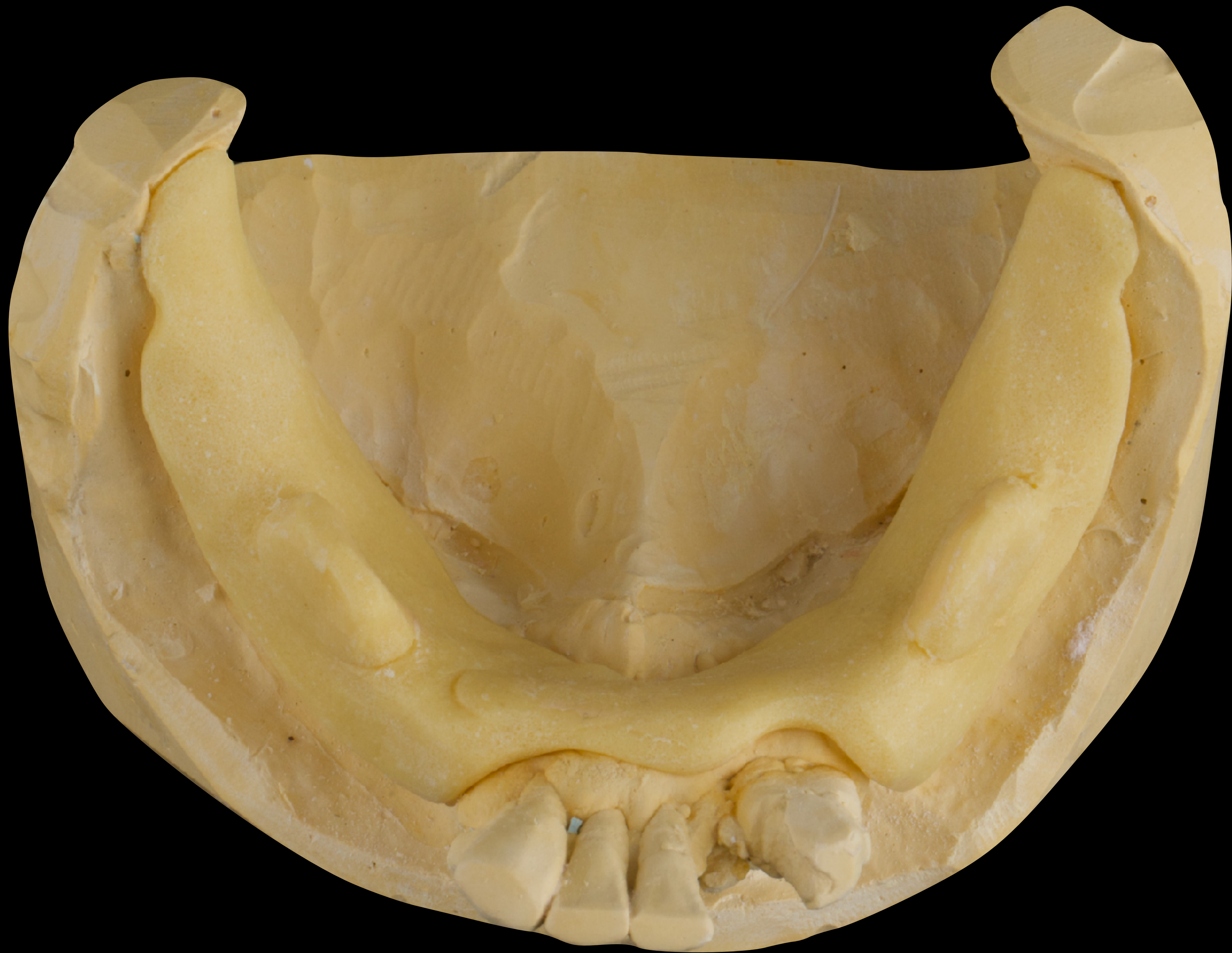


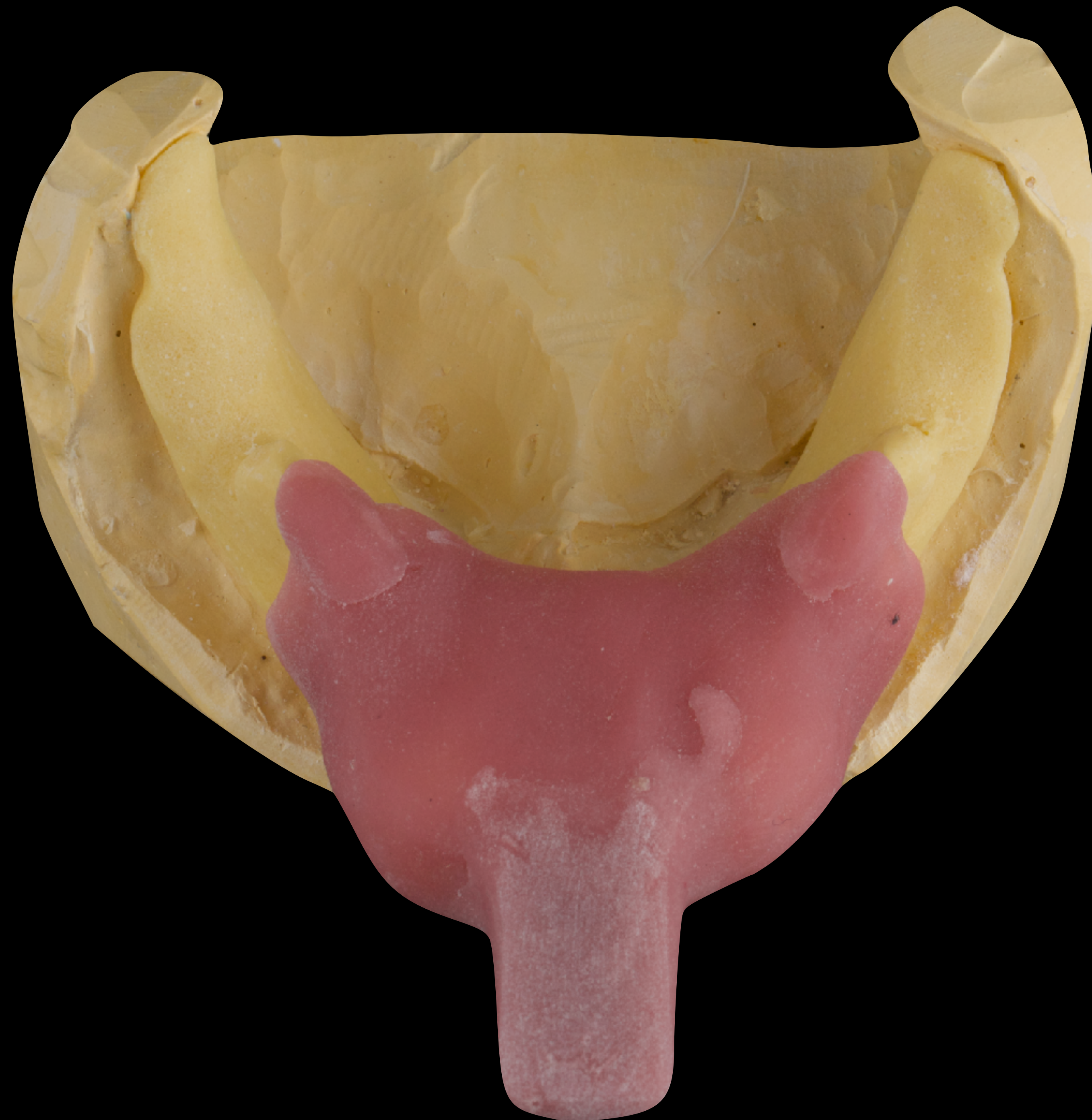

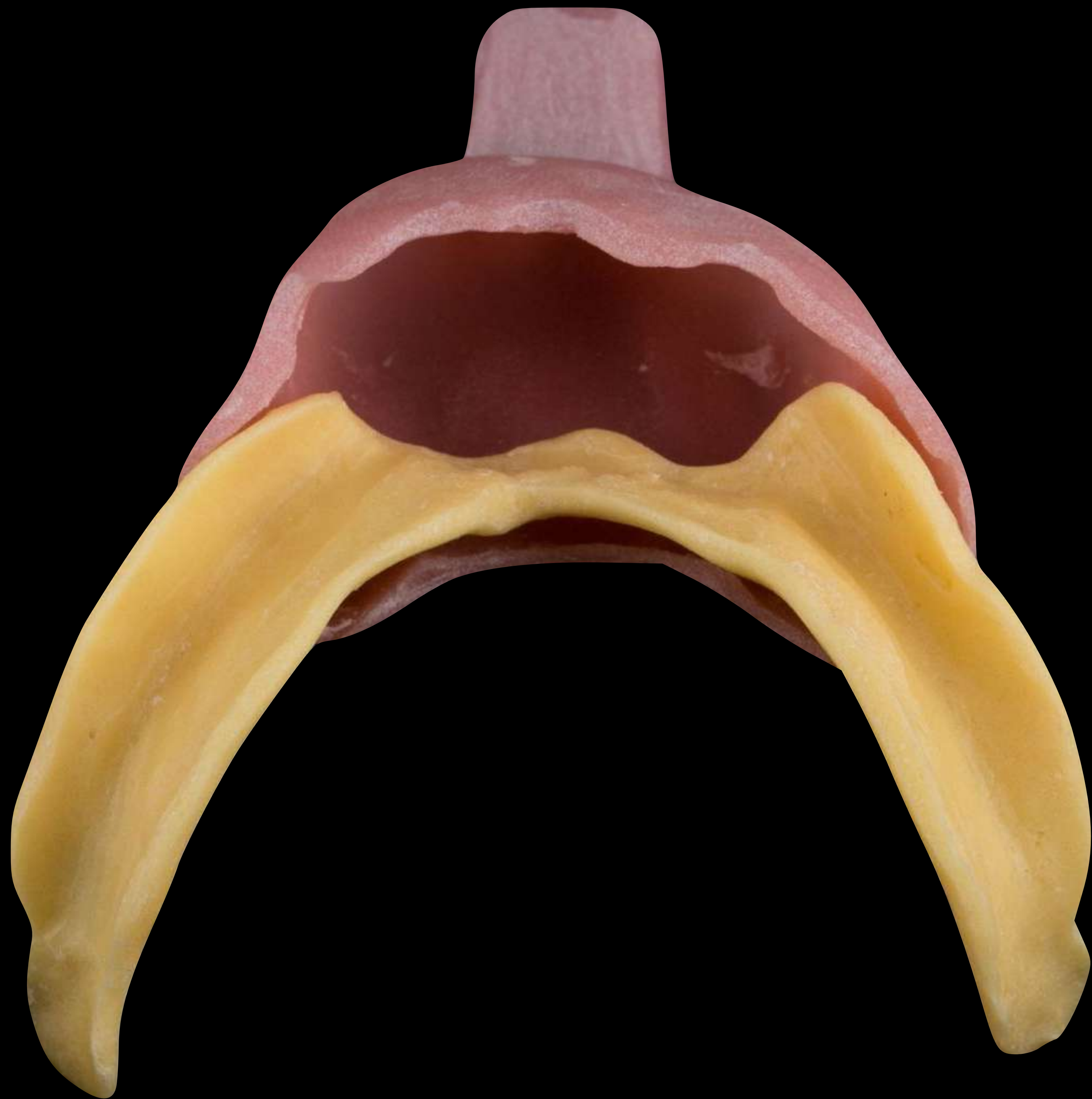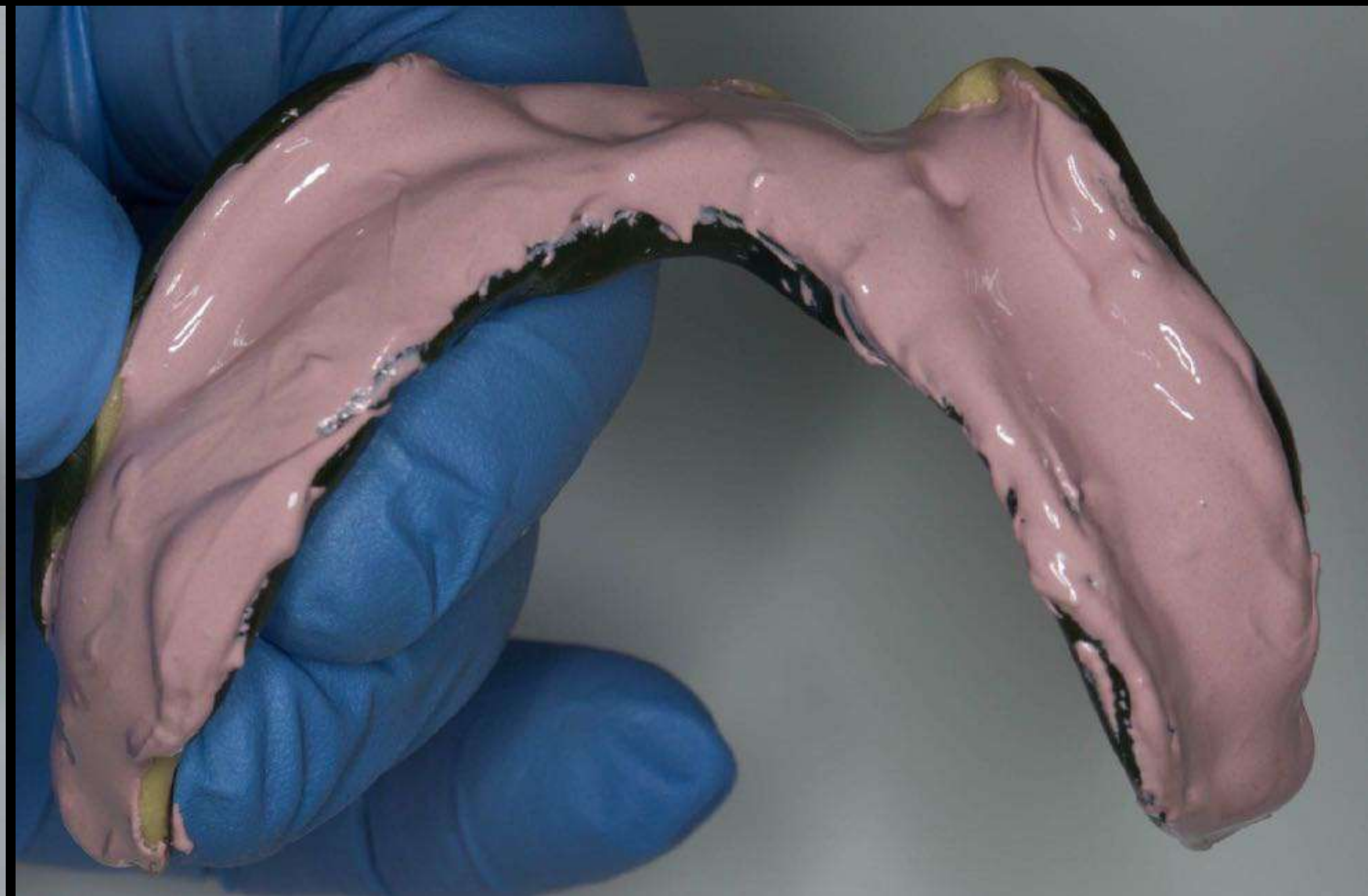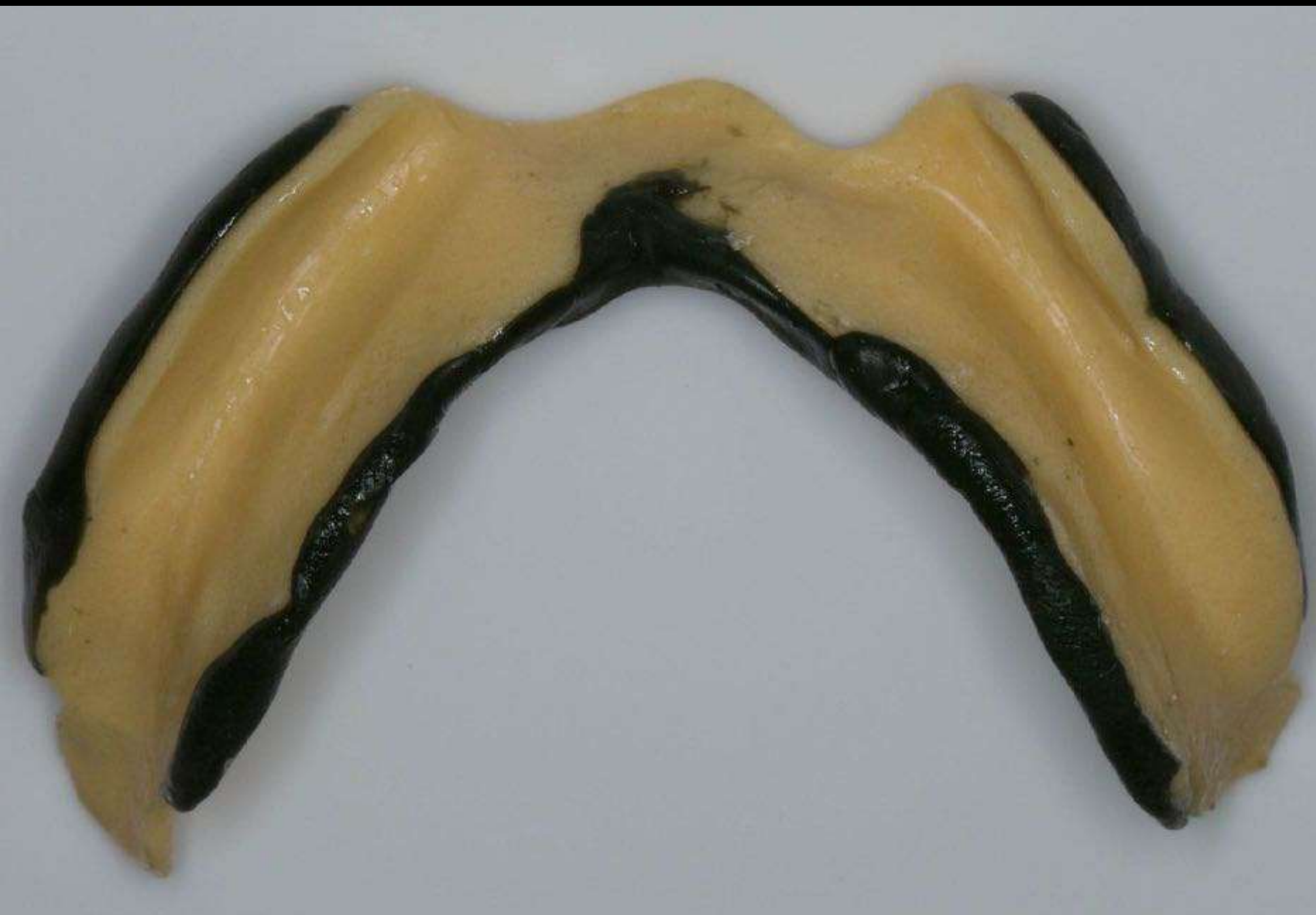Shape

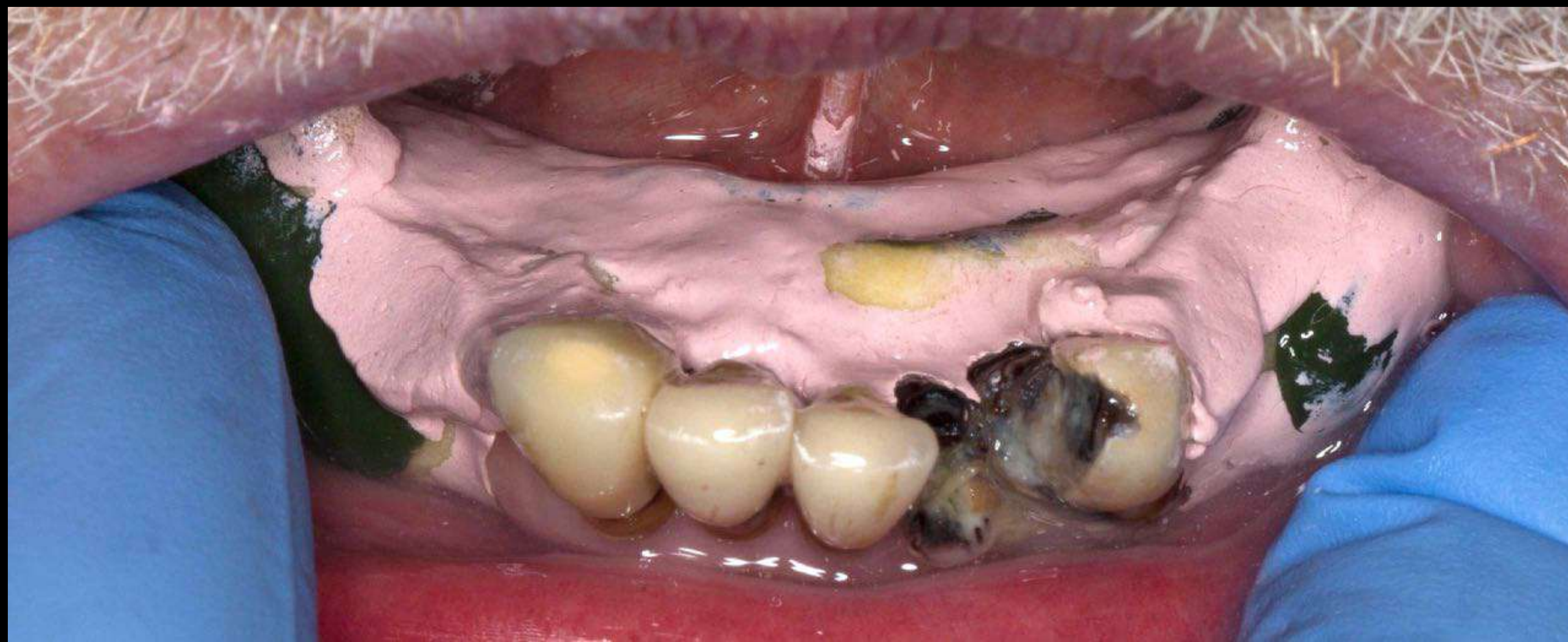
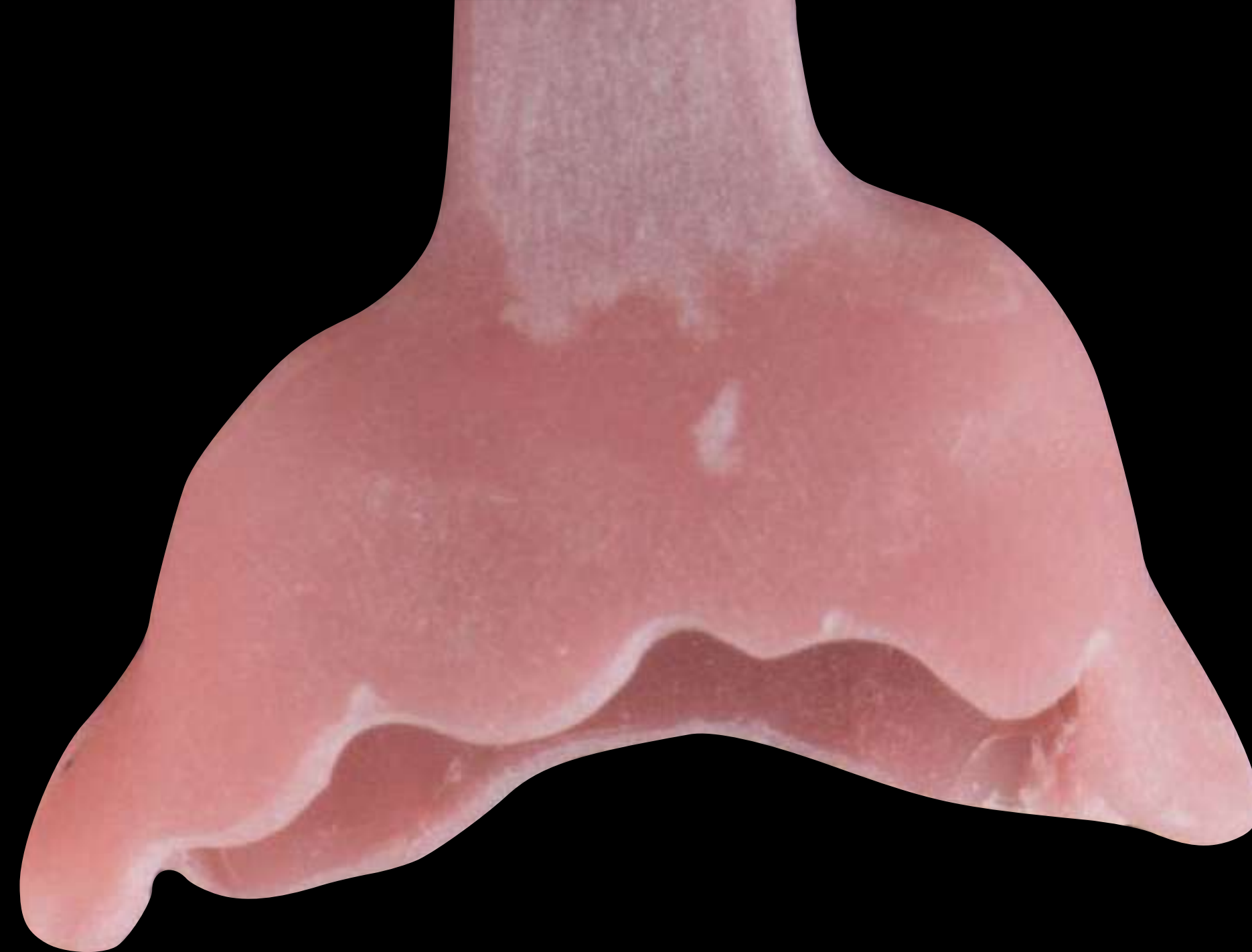
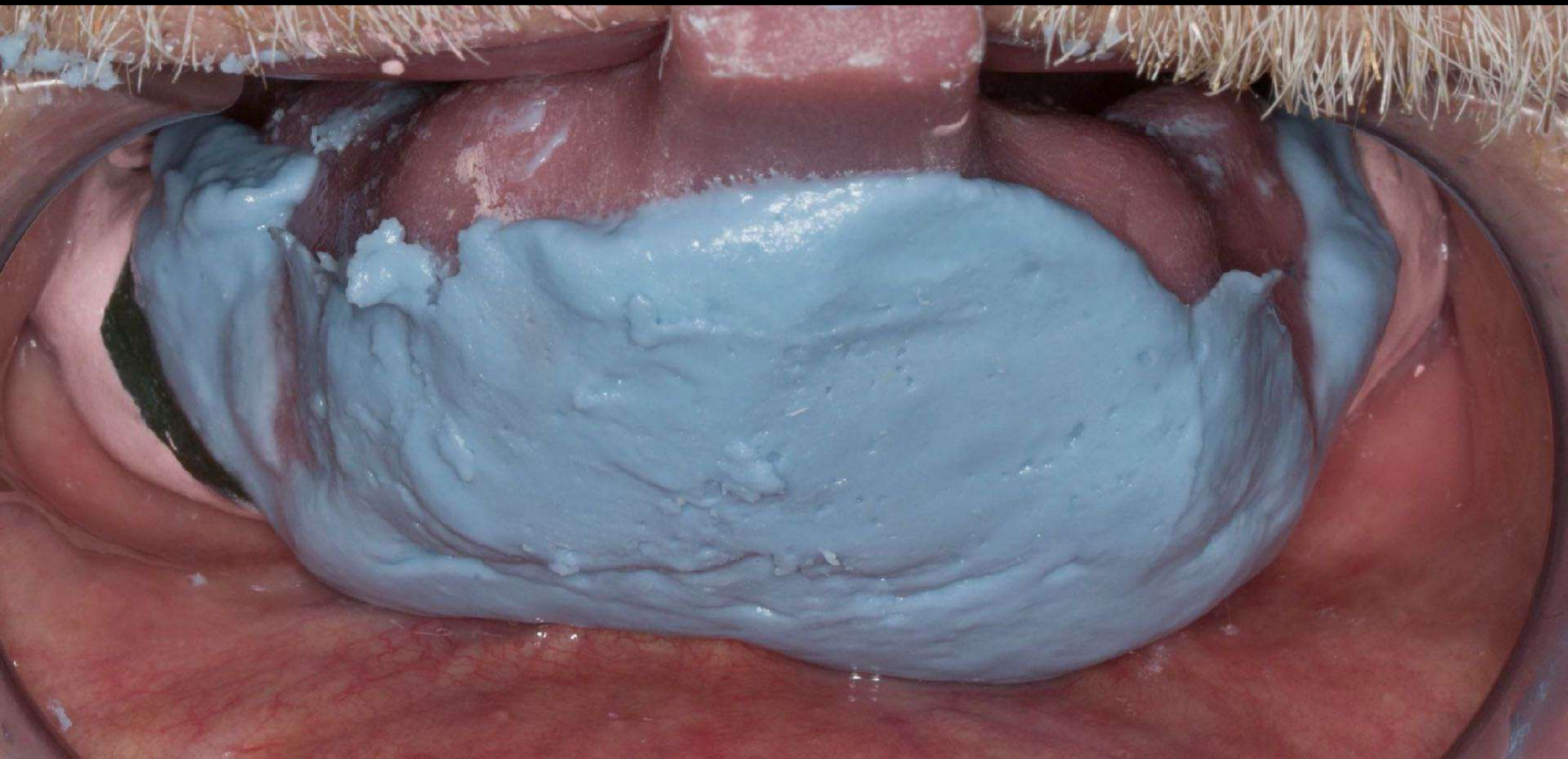




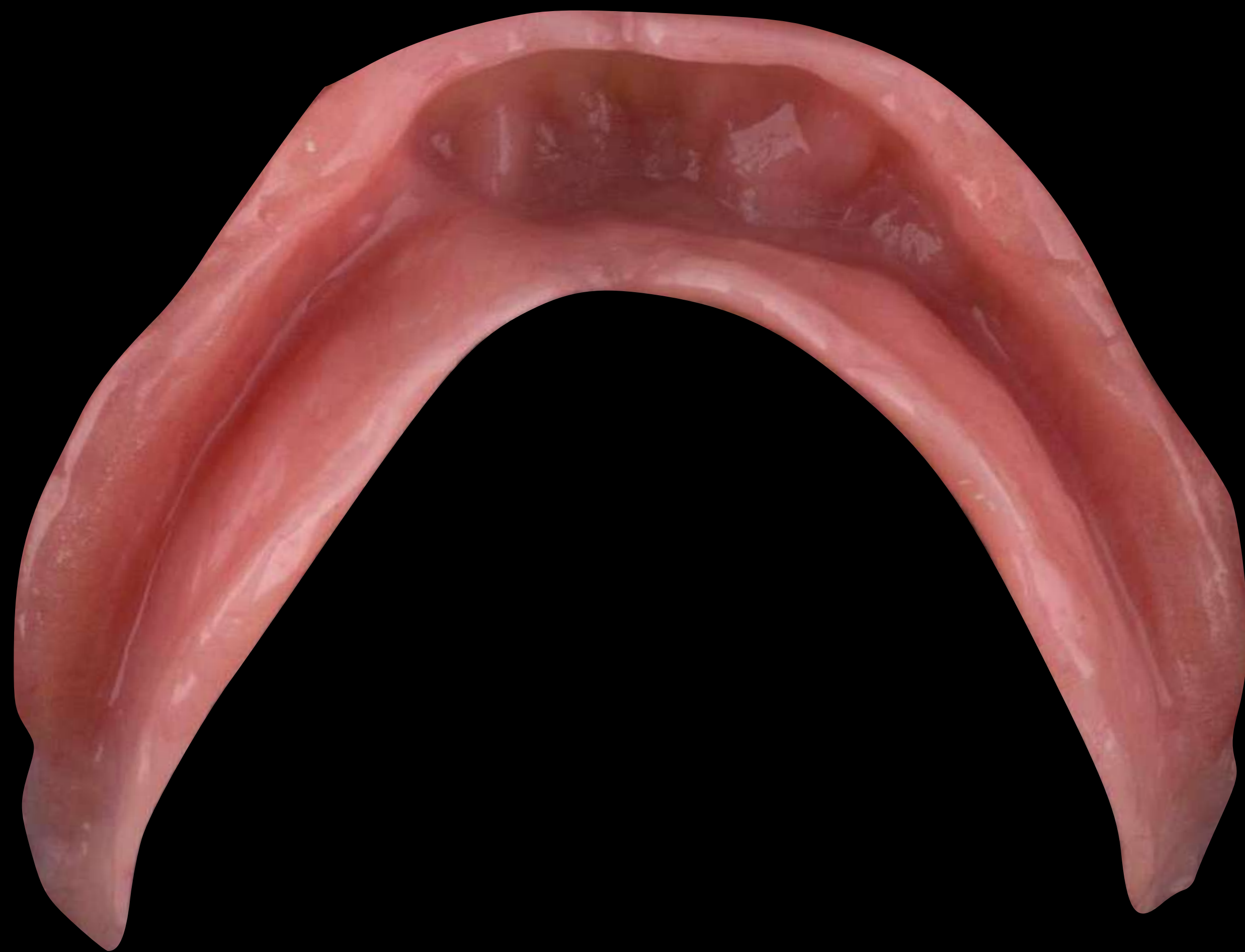
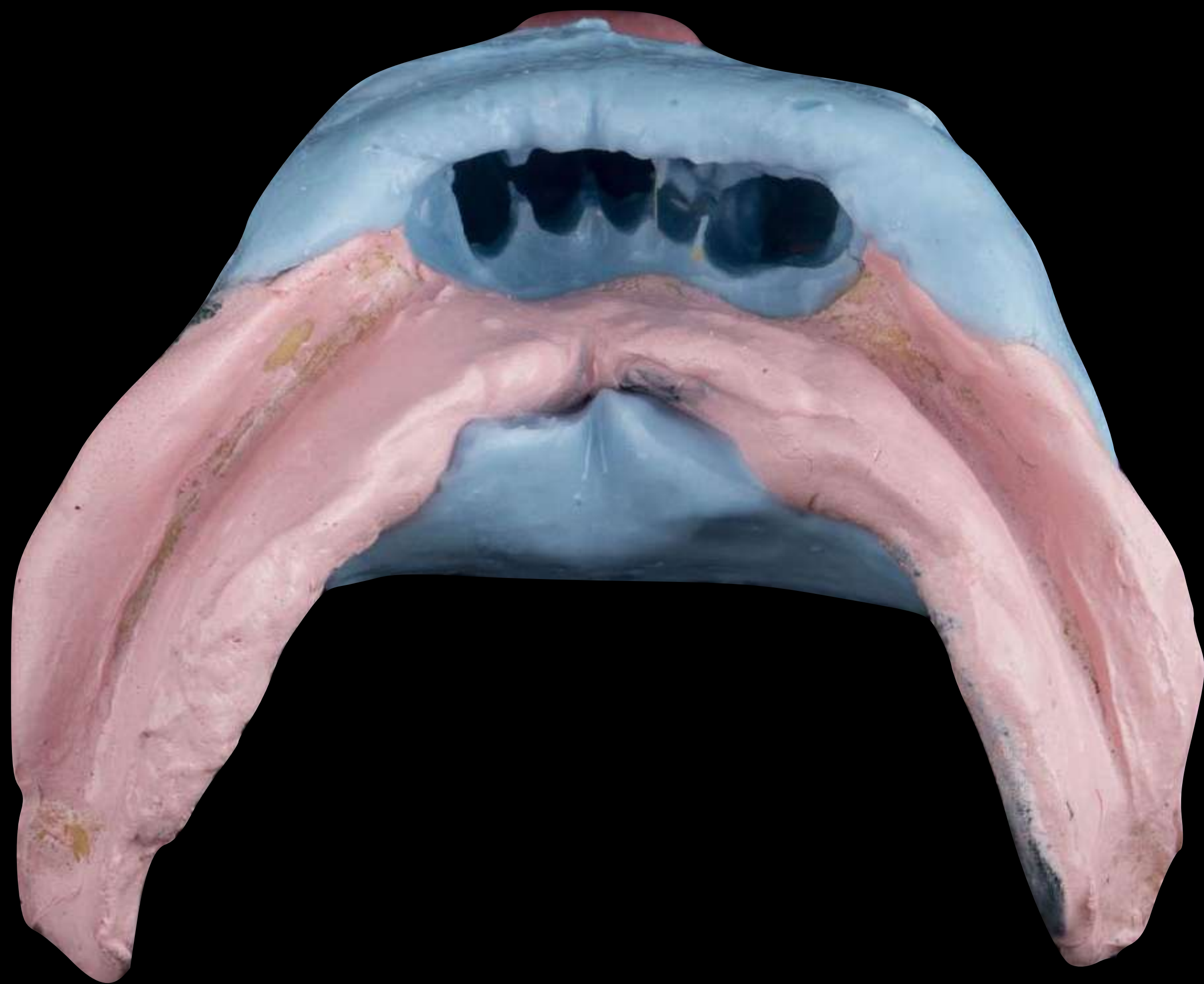




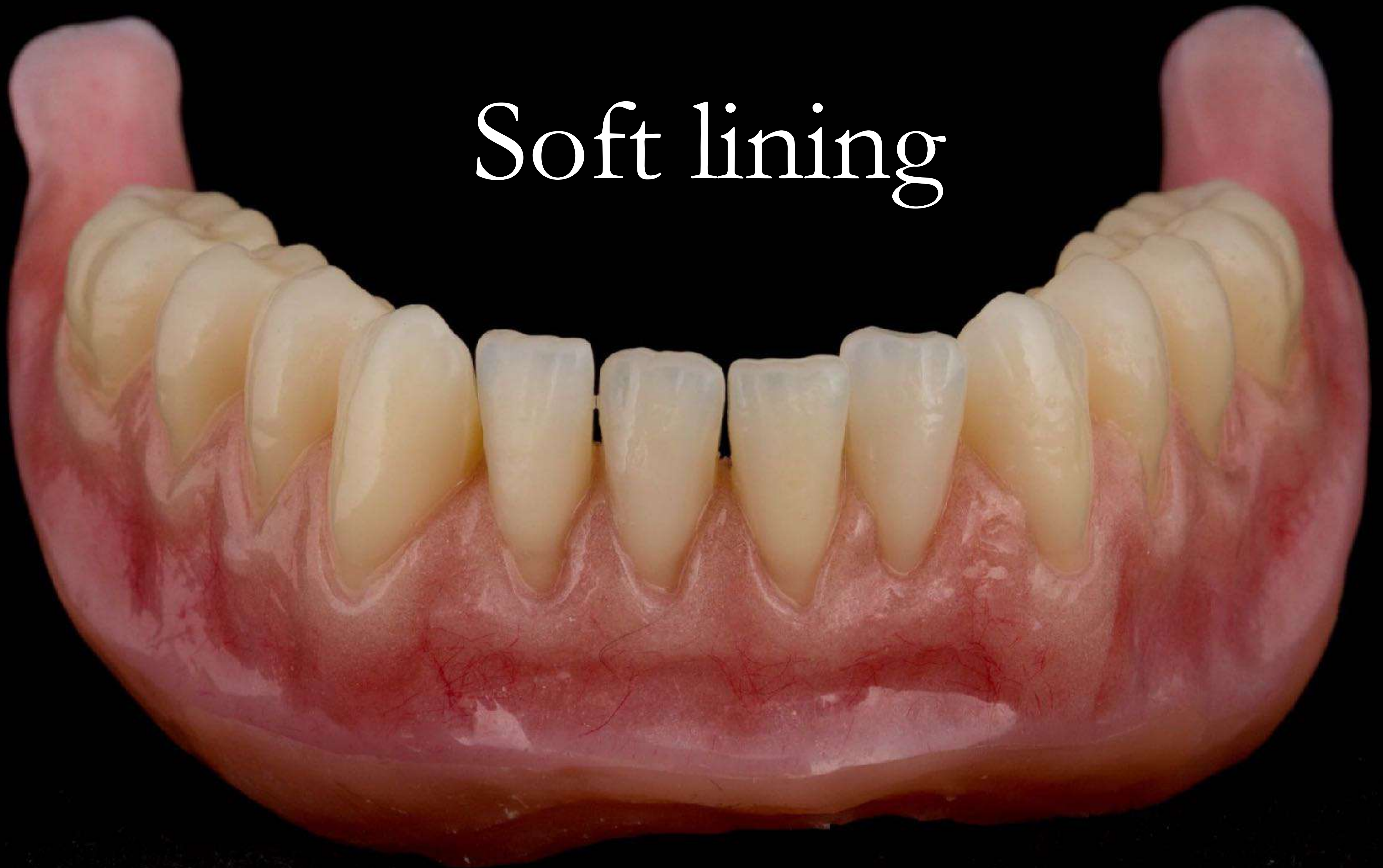


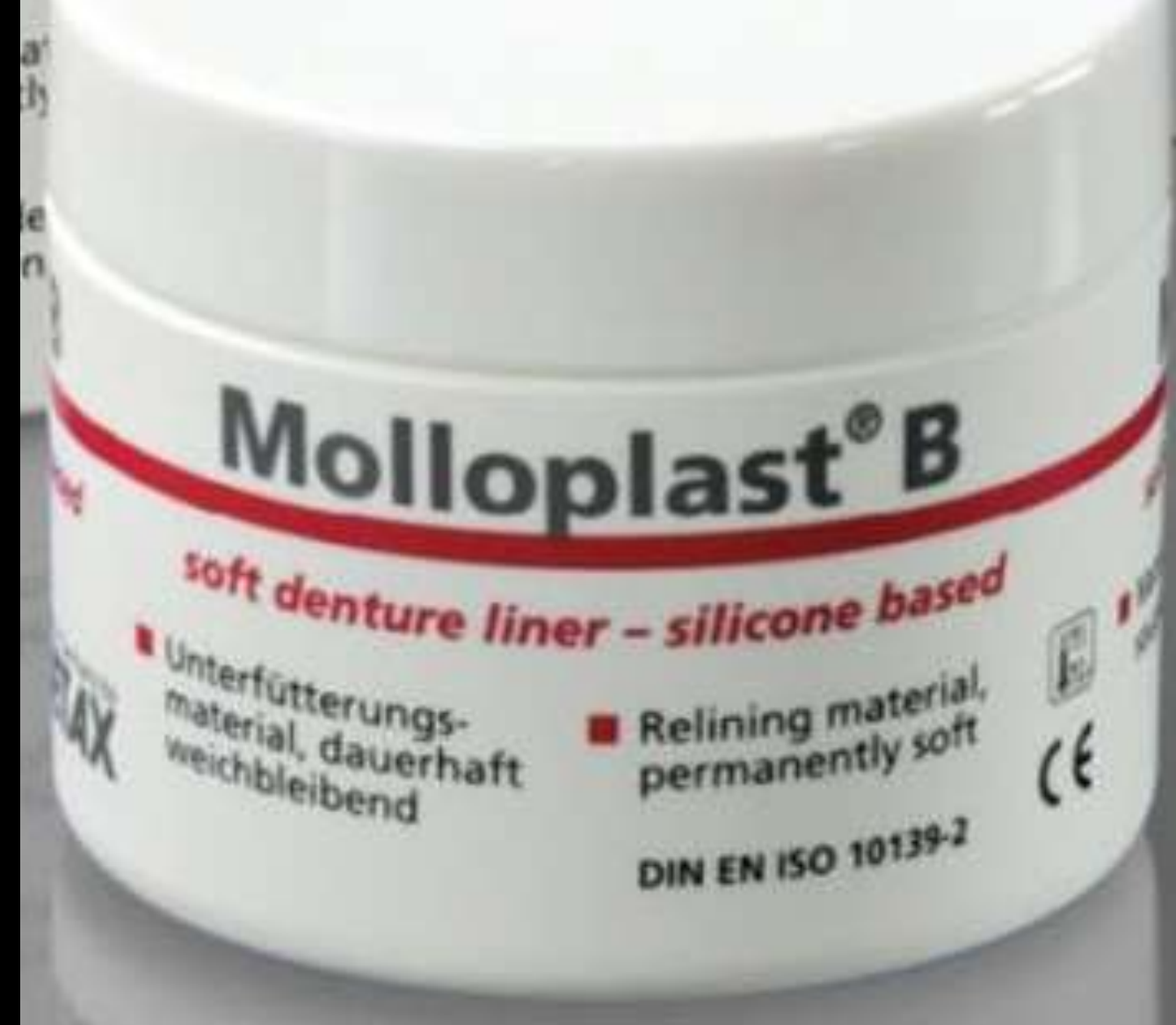
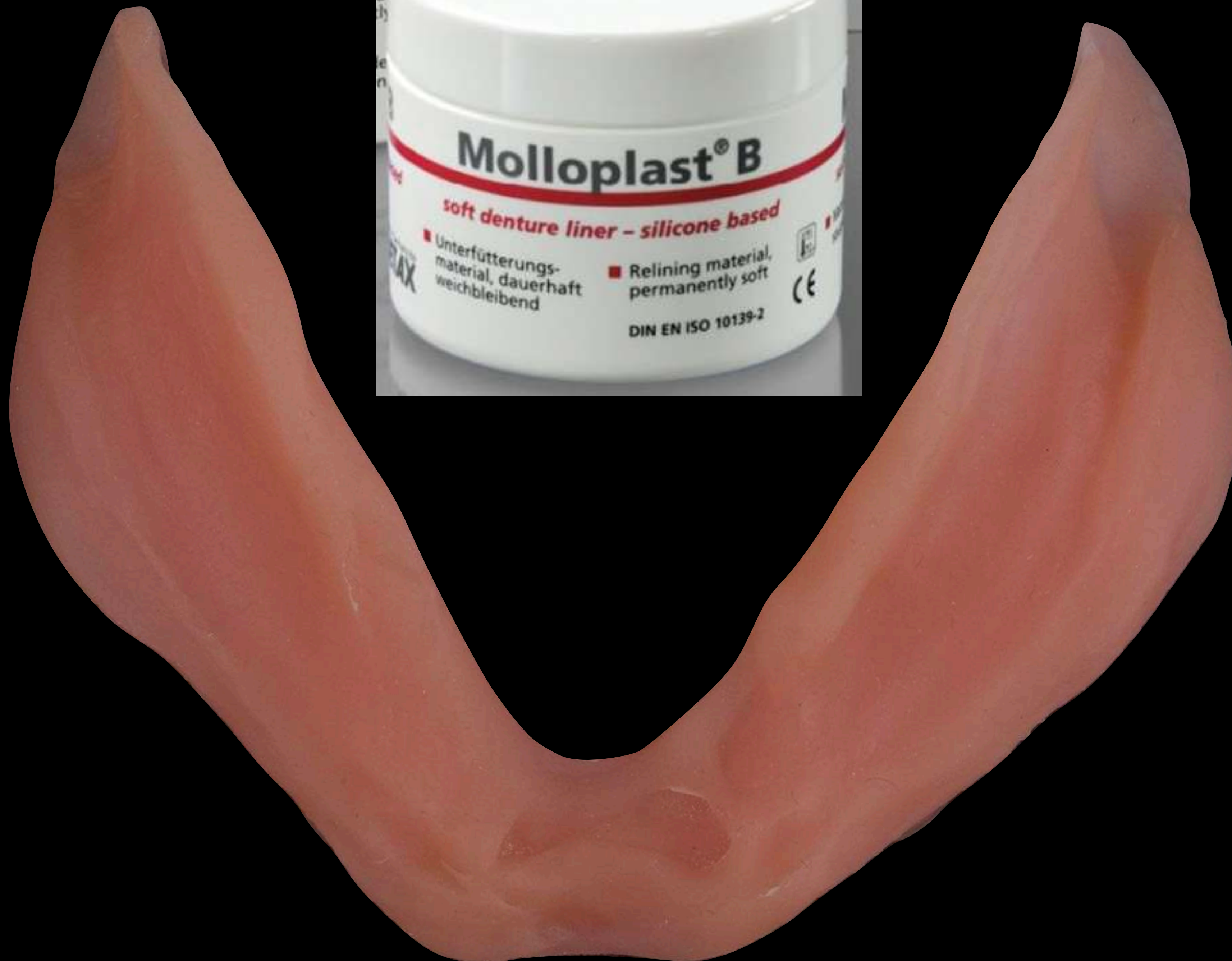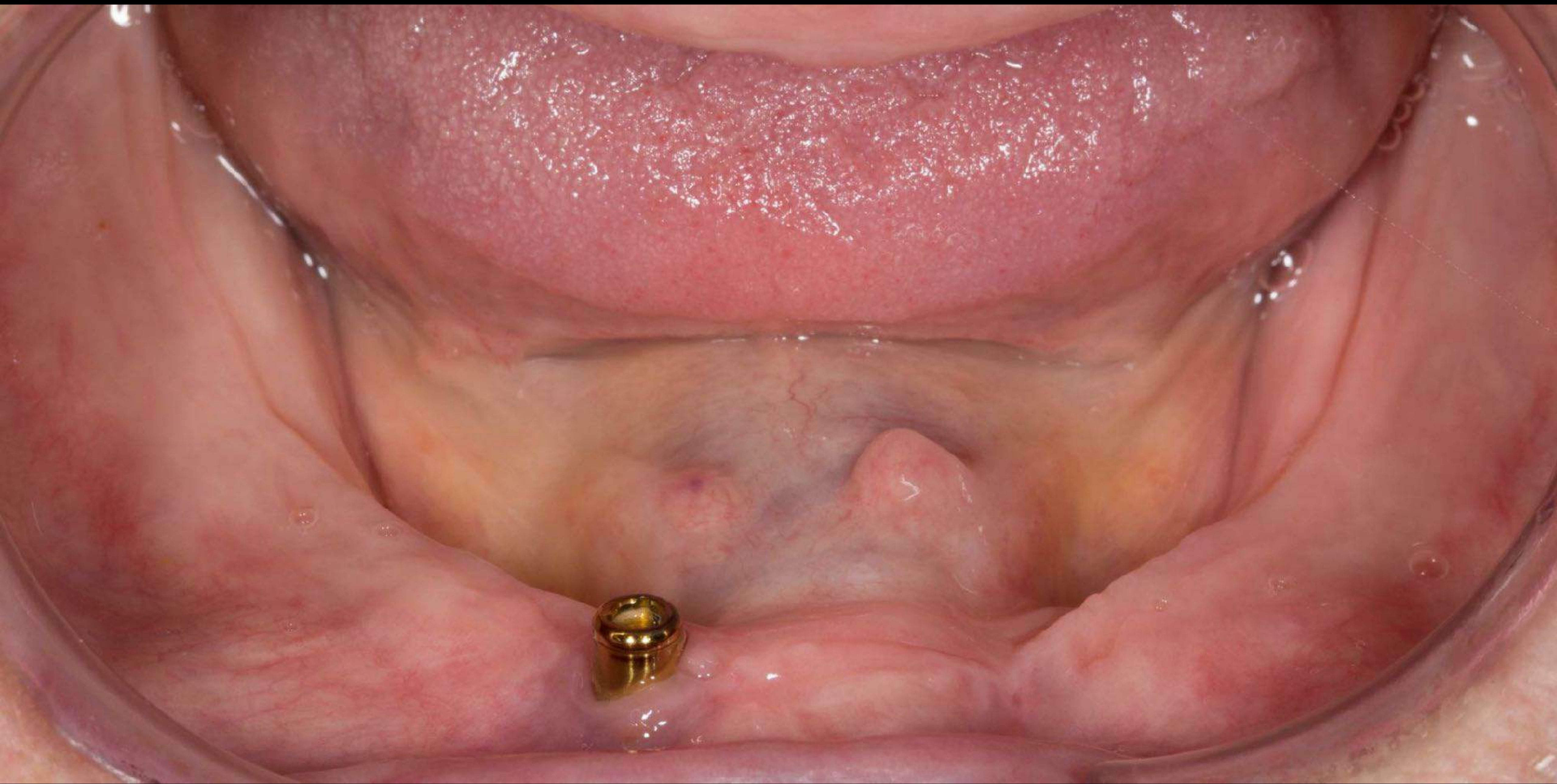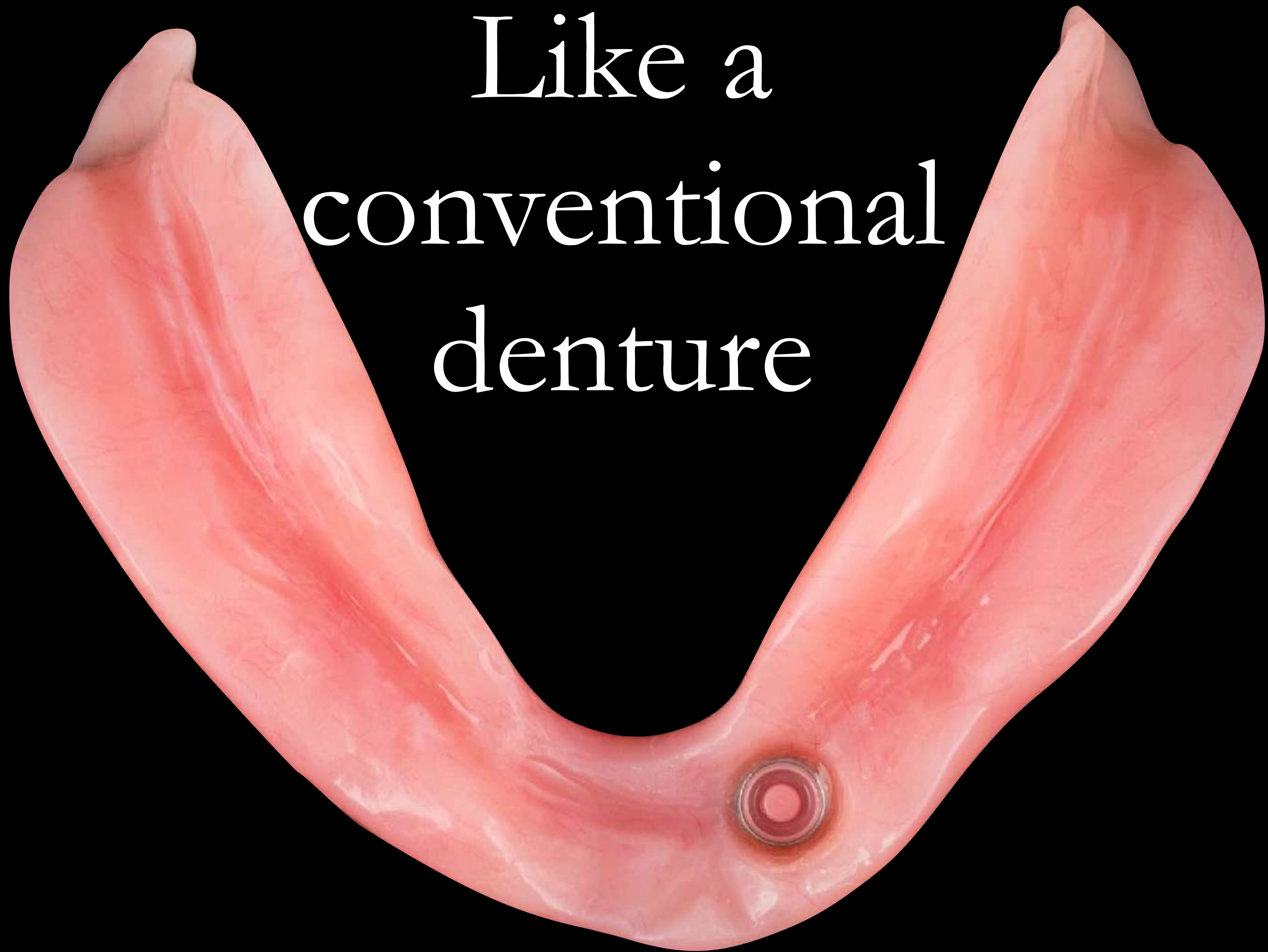
Soft lining








Like a
conventional
denture

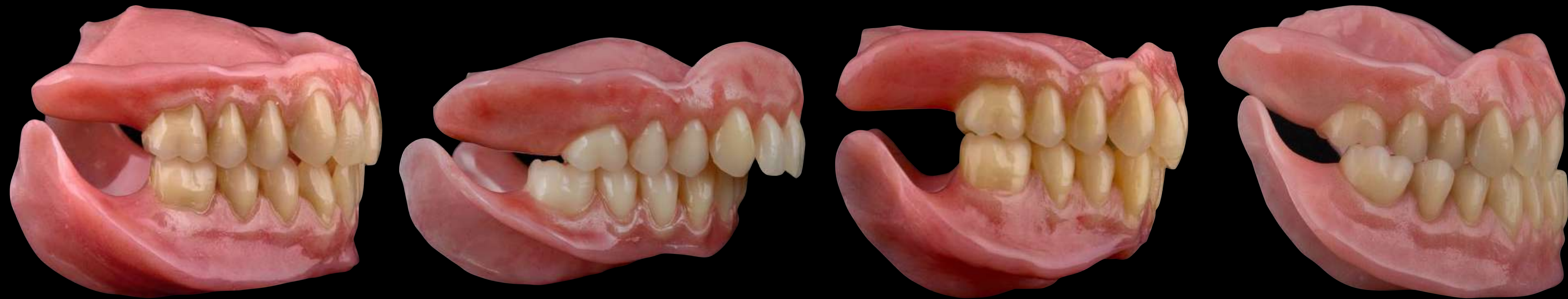



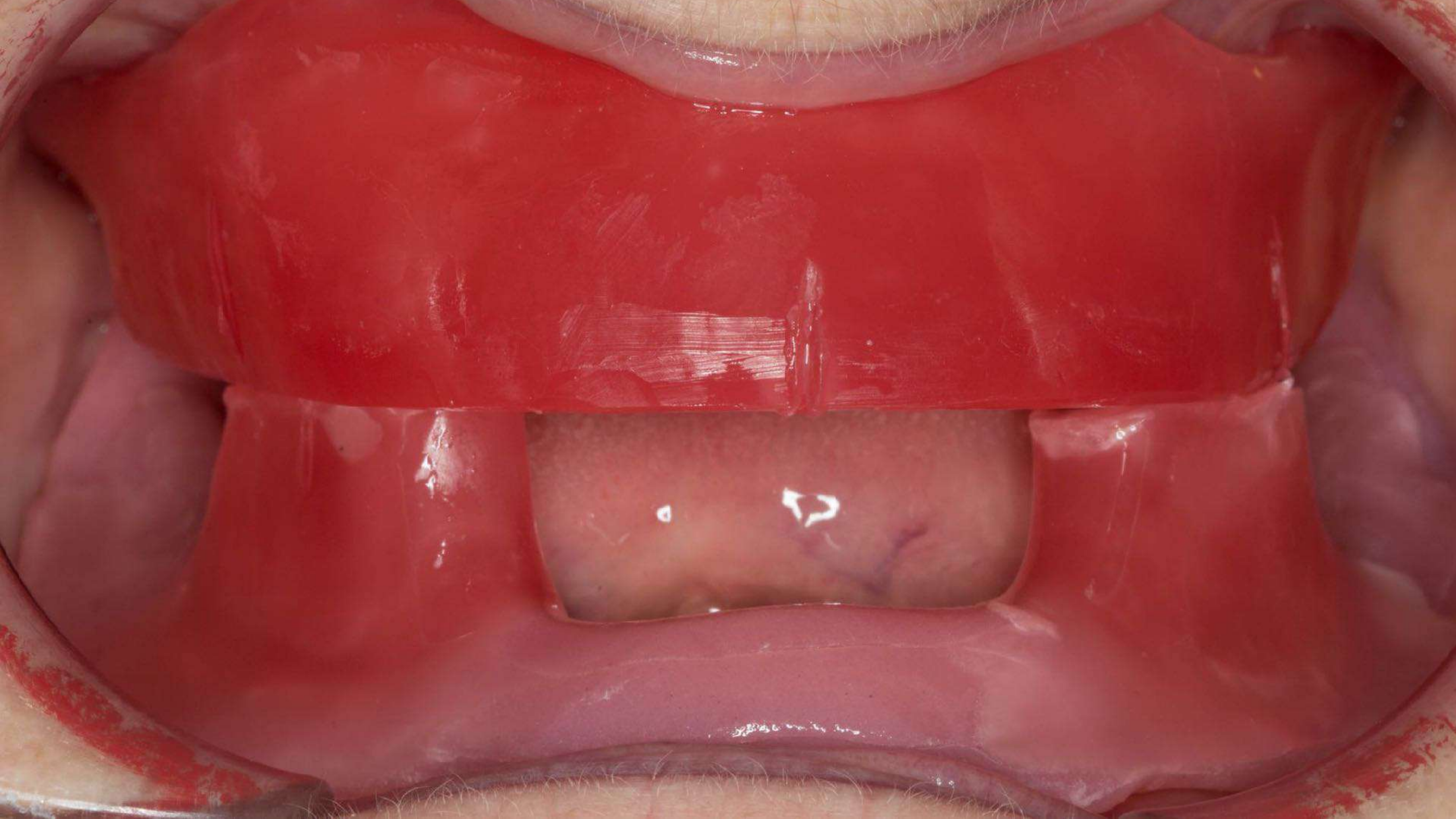4

Tooth positioning

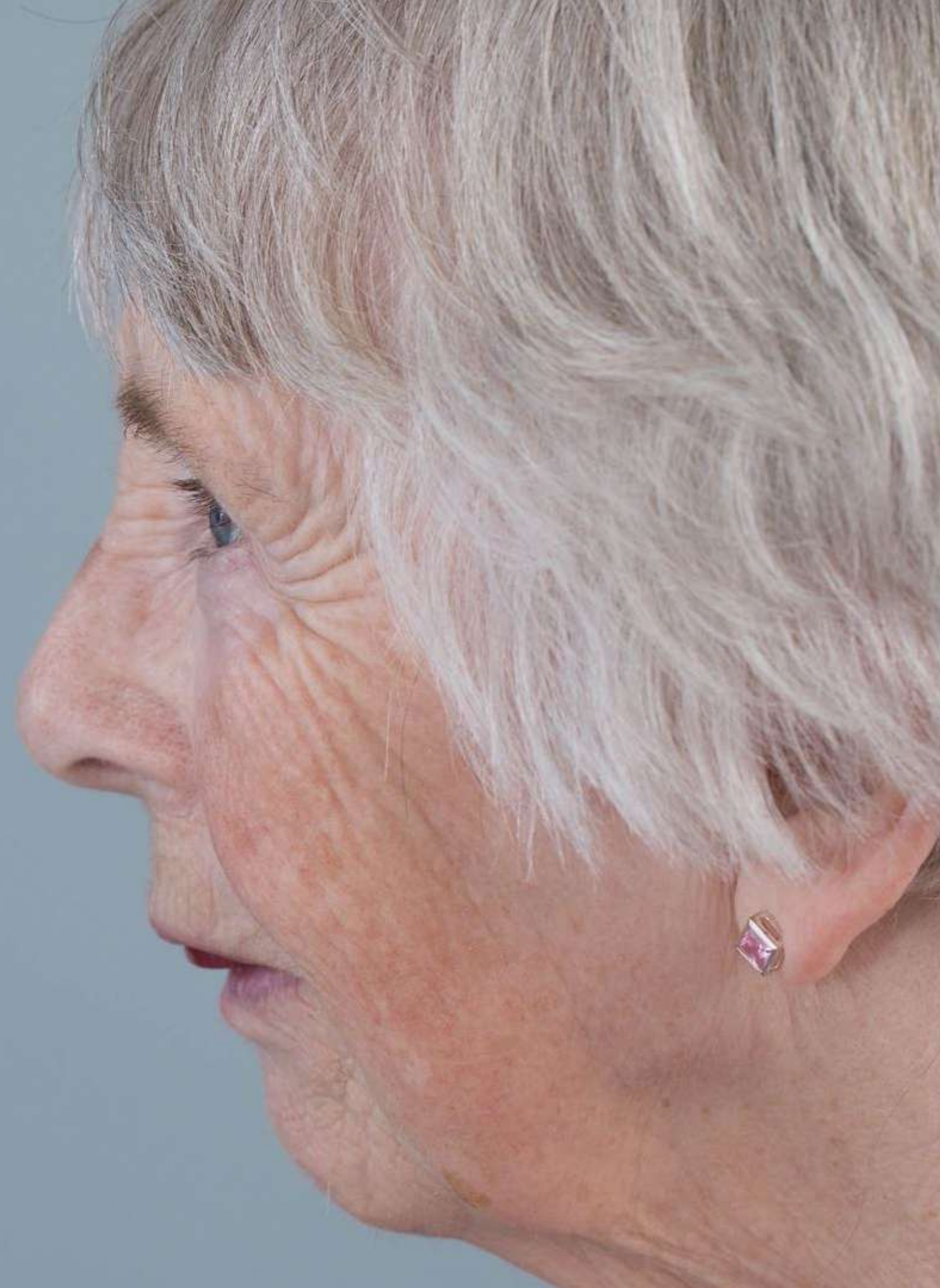Increased stability




Replace teeth/gums in same place as natural predecessors

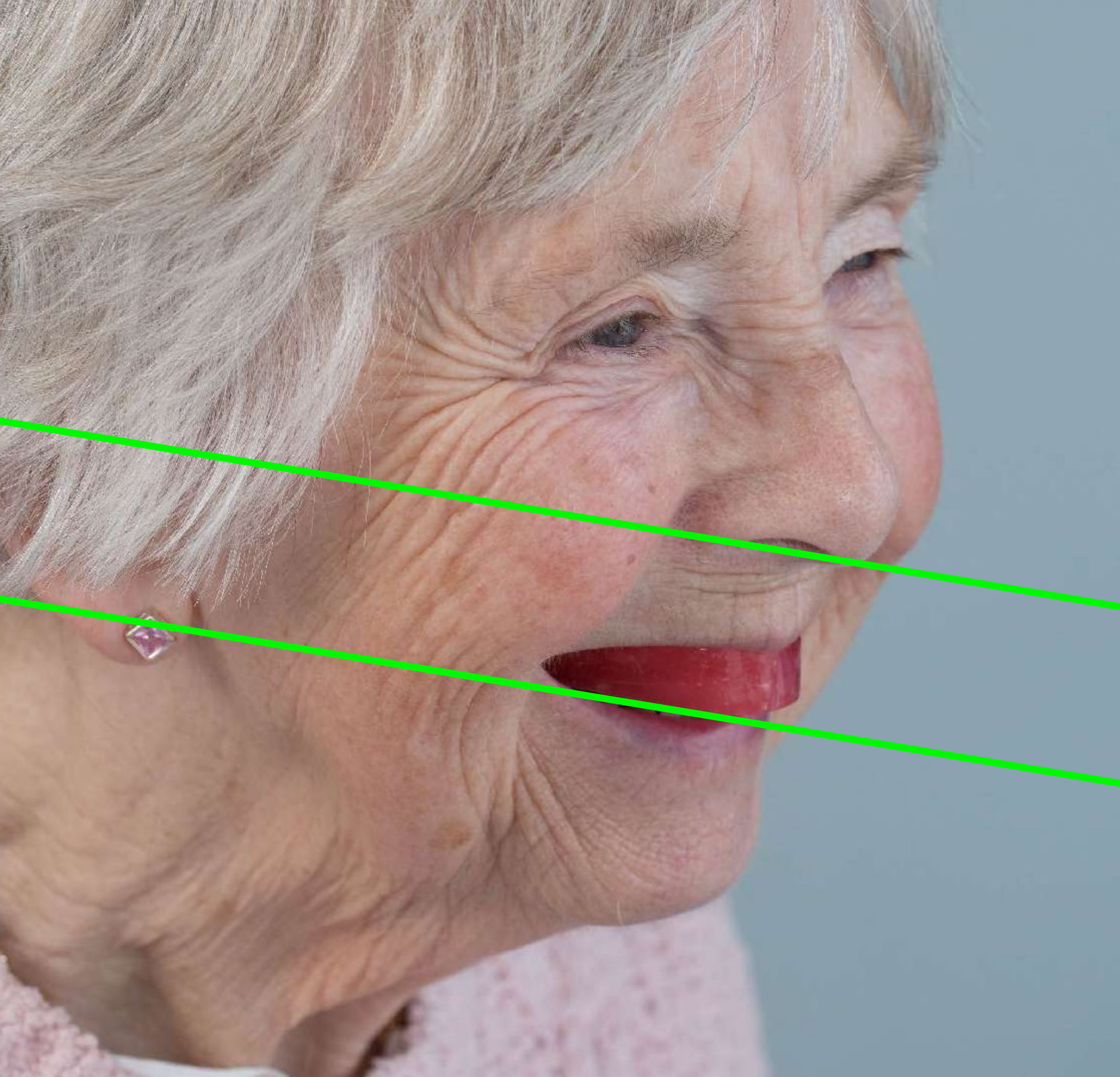


1. Lip Support




2. Incisal plane




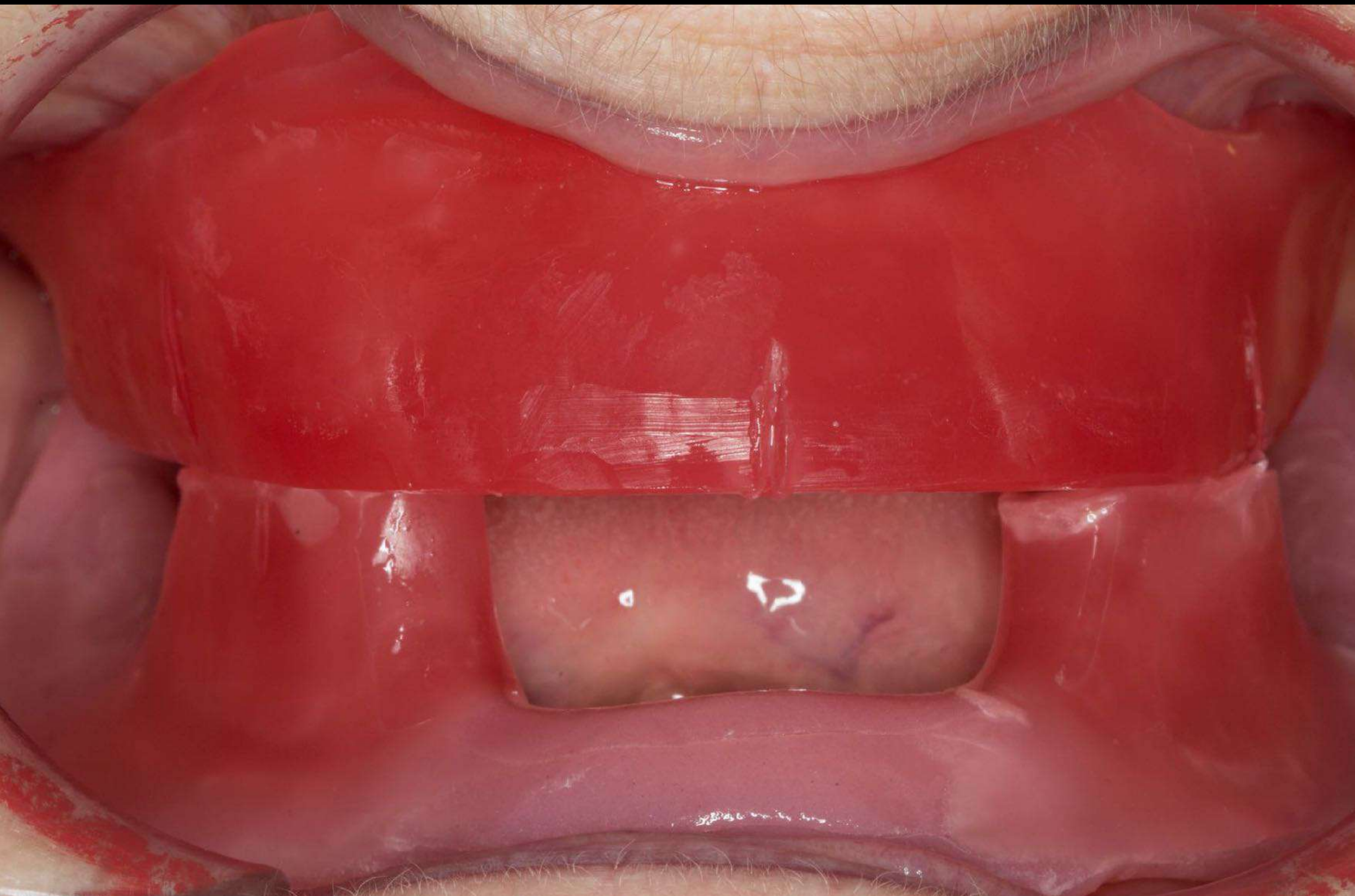


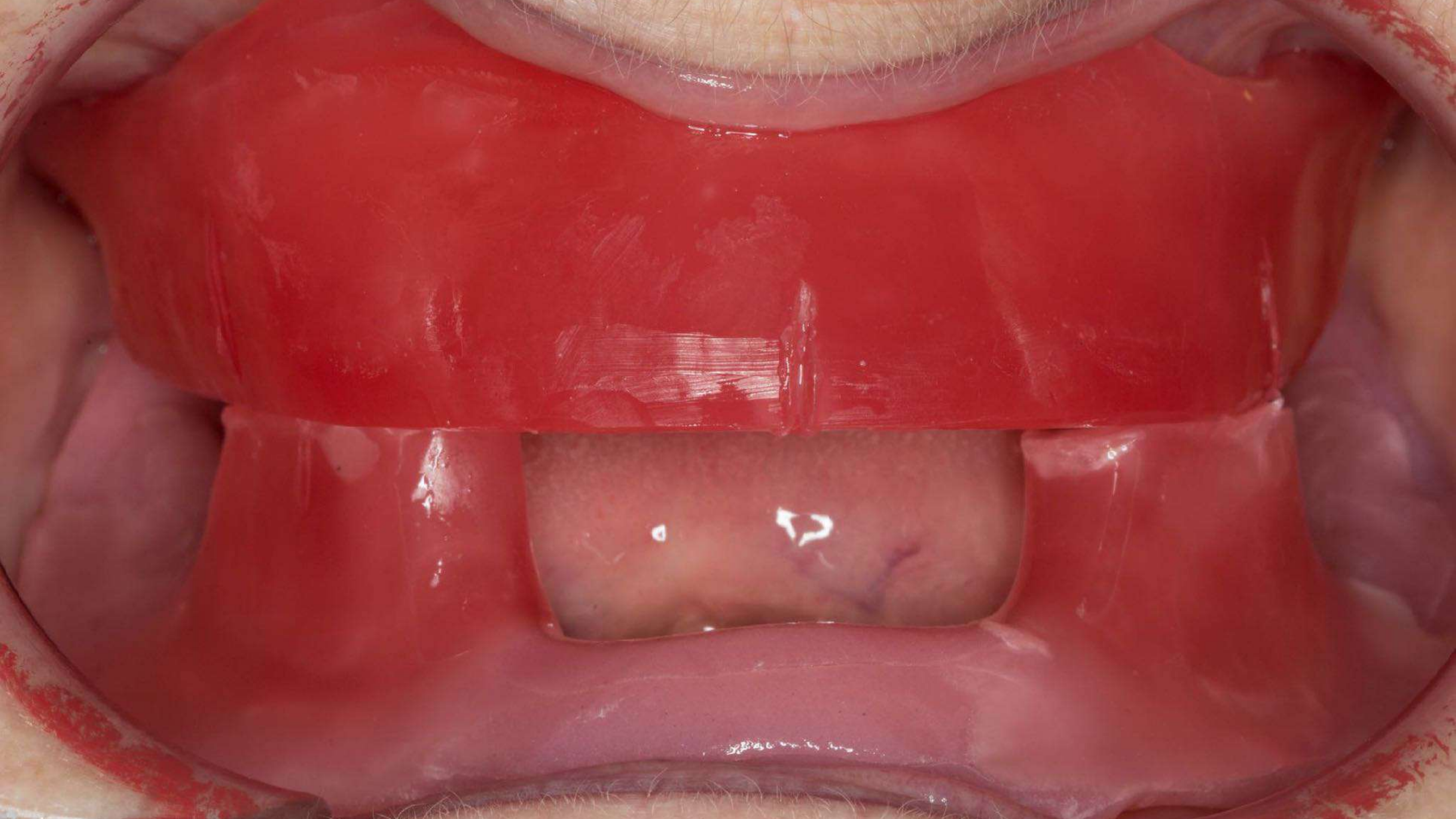
3. Occlusal plane

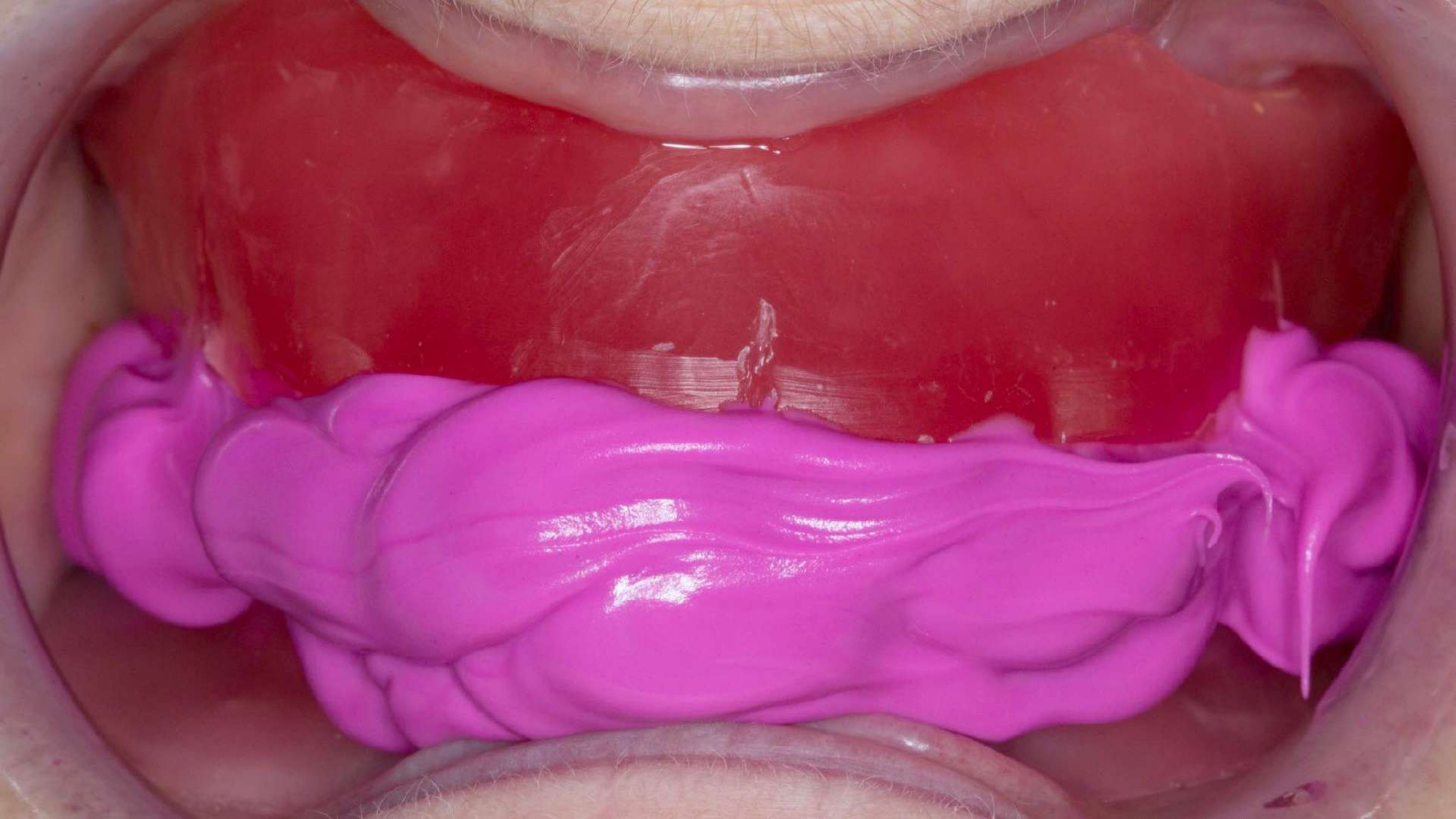


4 & 5 Buccal corridors and centre line

6. Occlusal Vertical Dimension

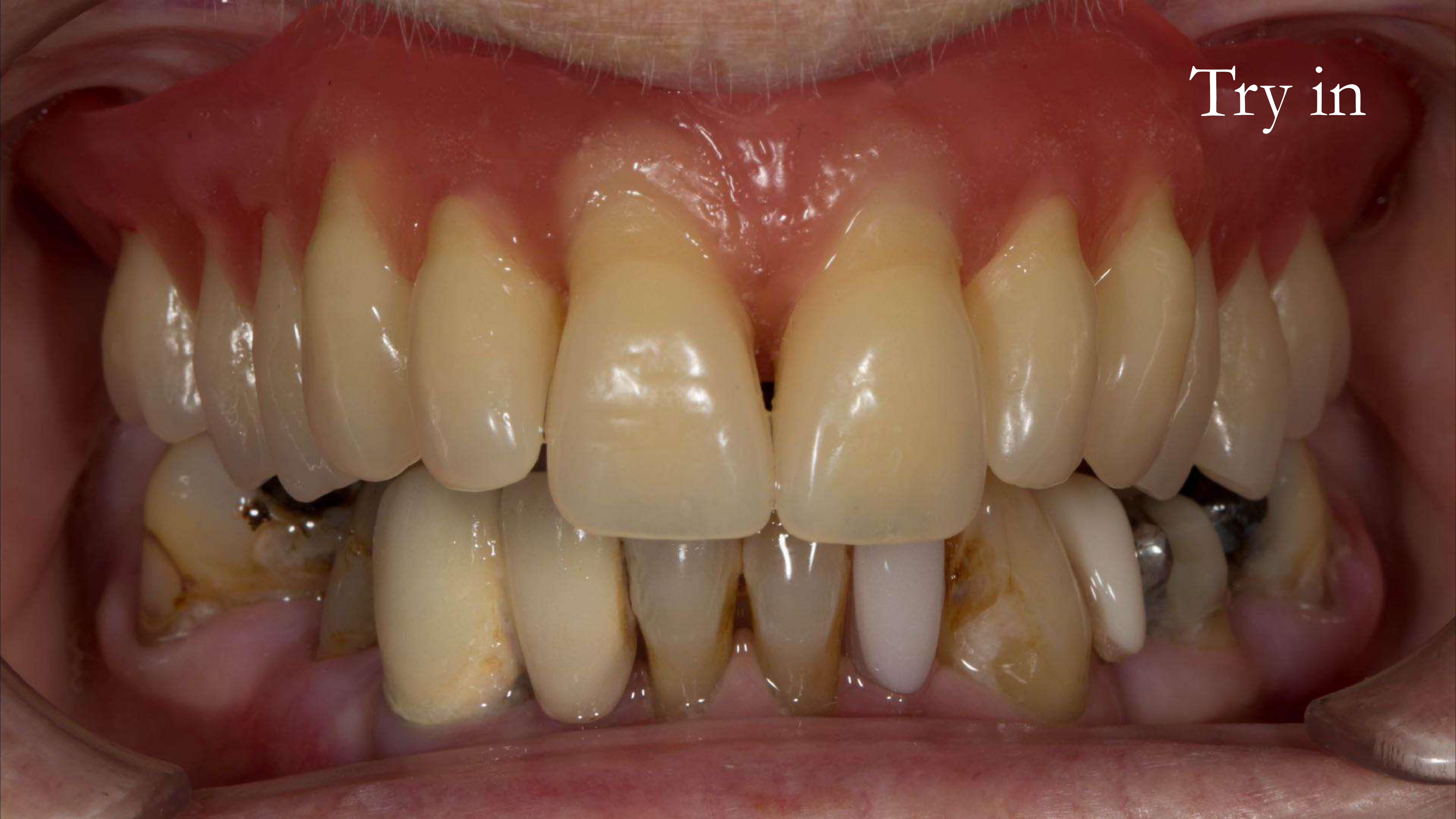




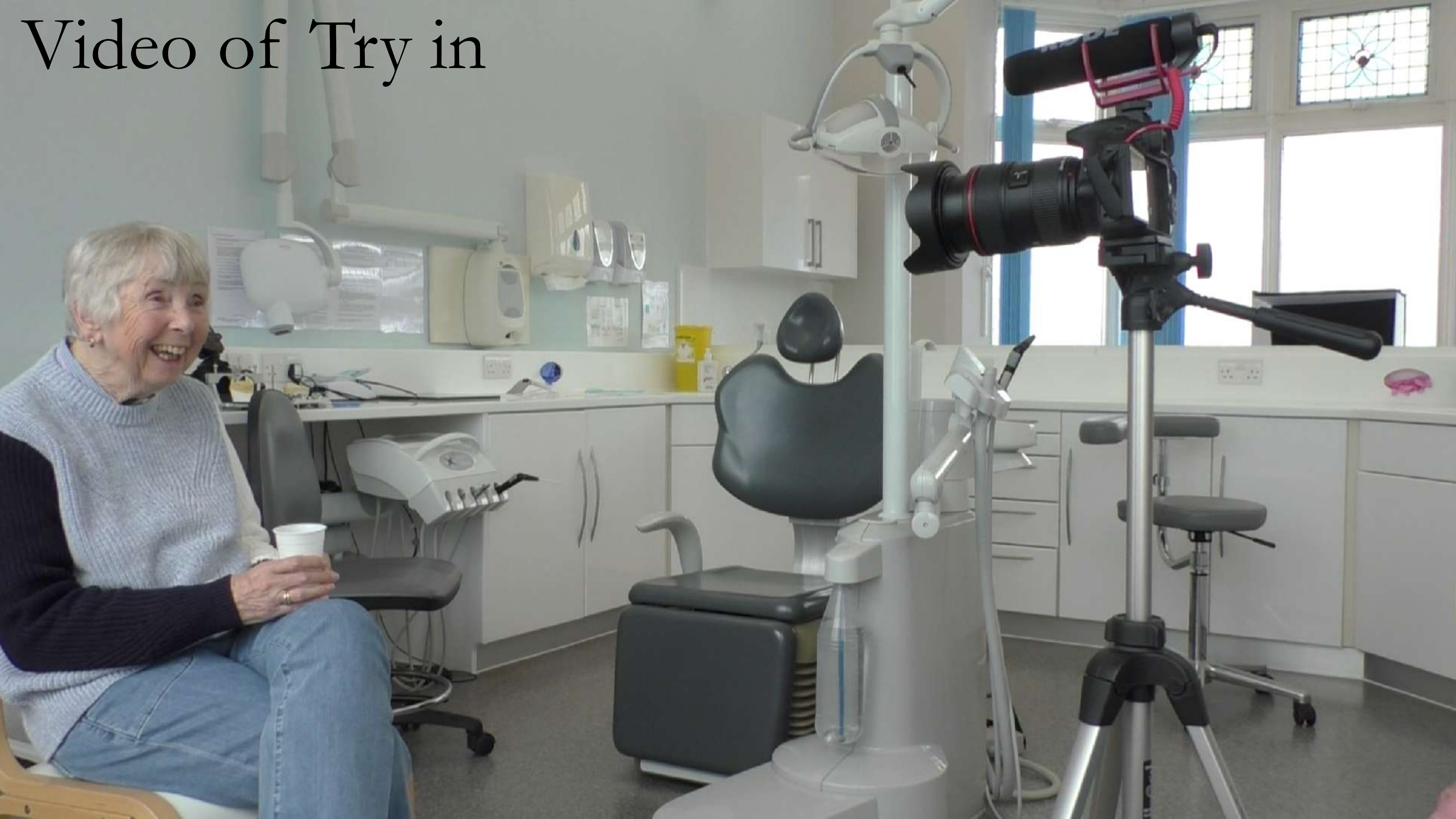


Try in



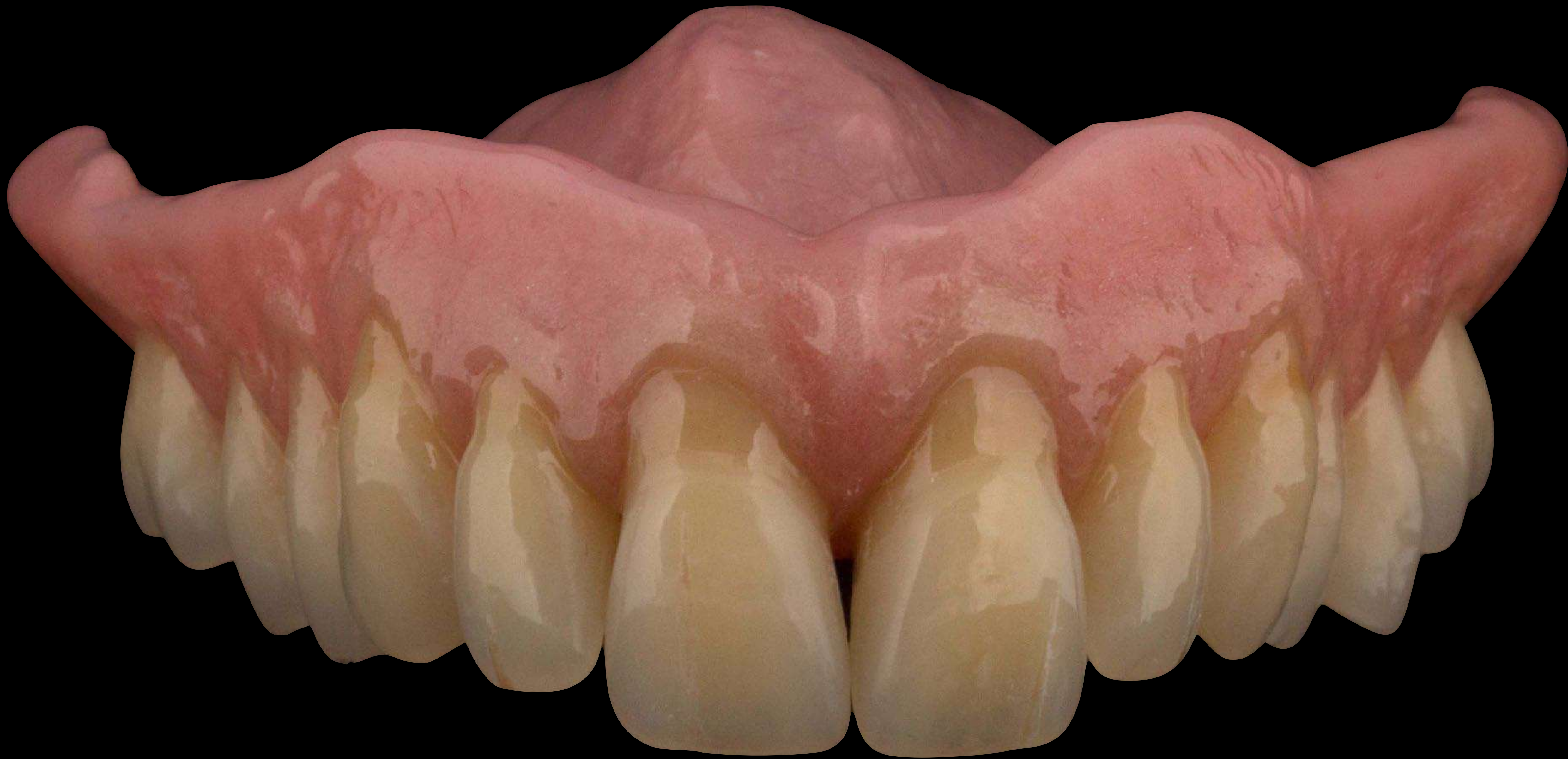Video of Try in










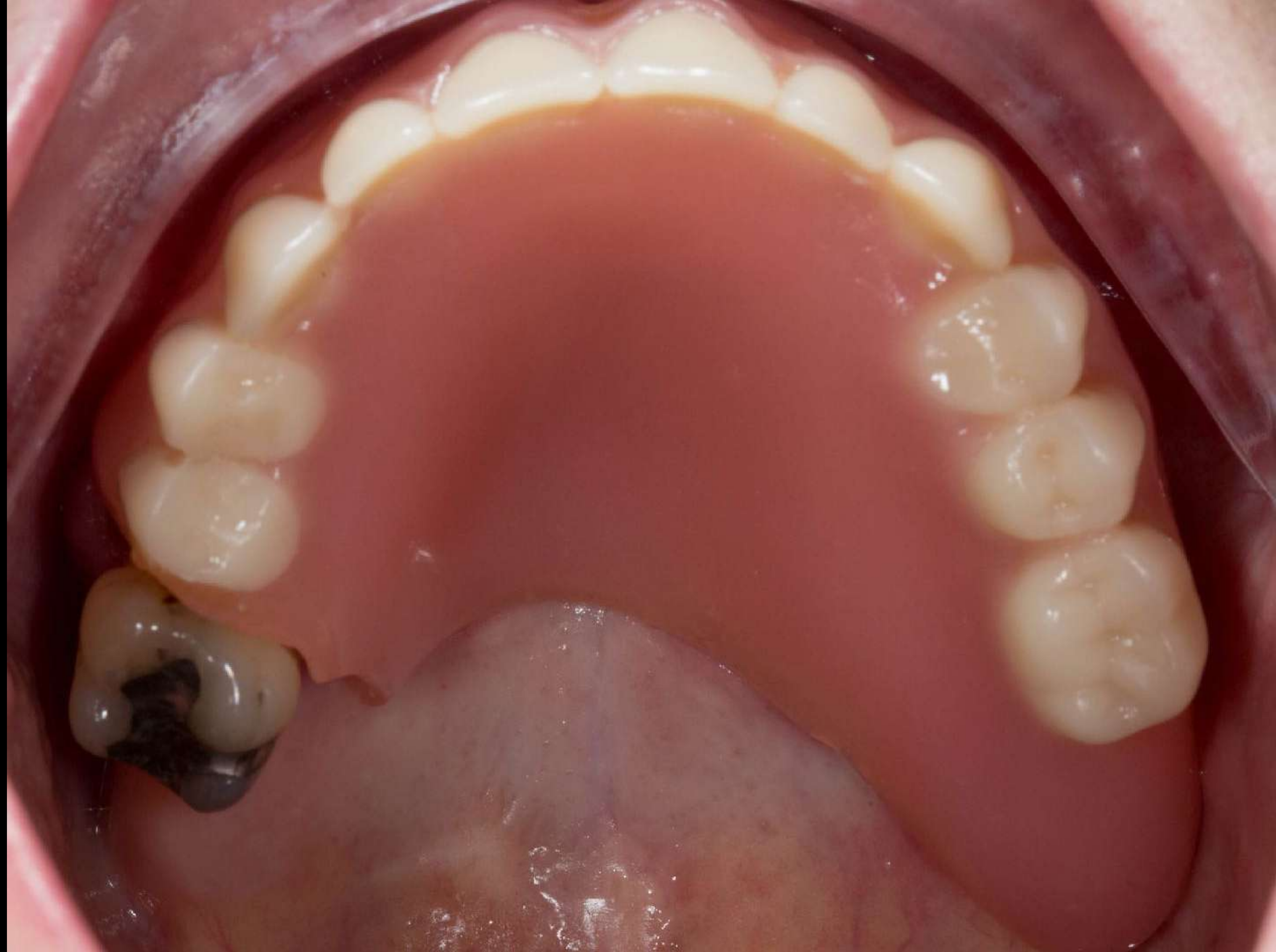


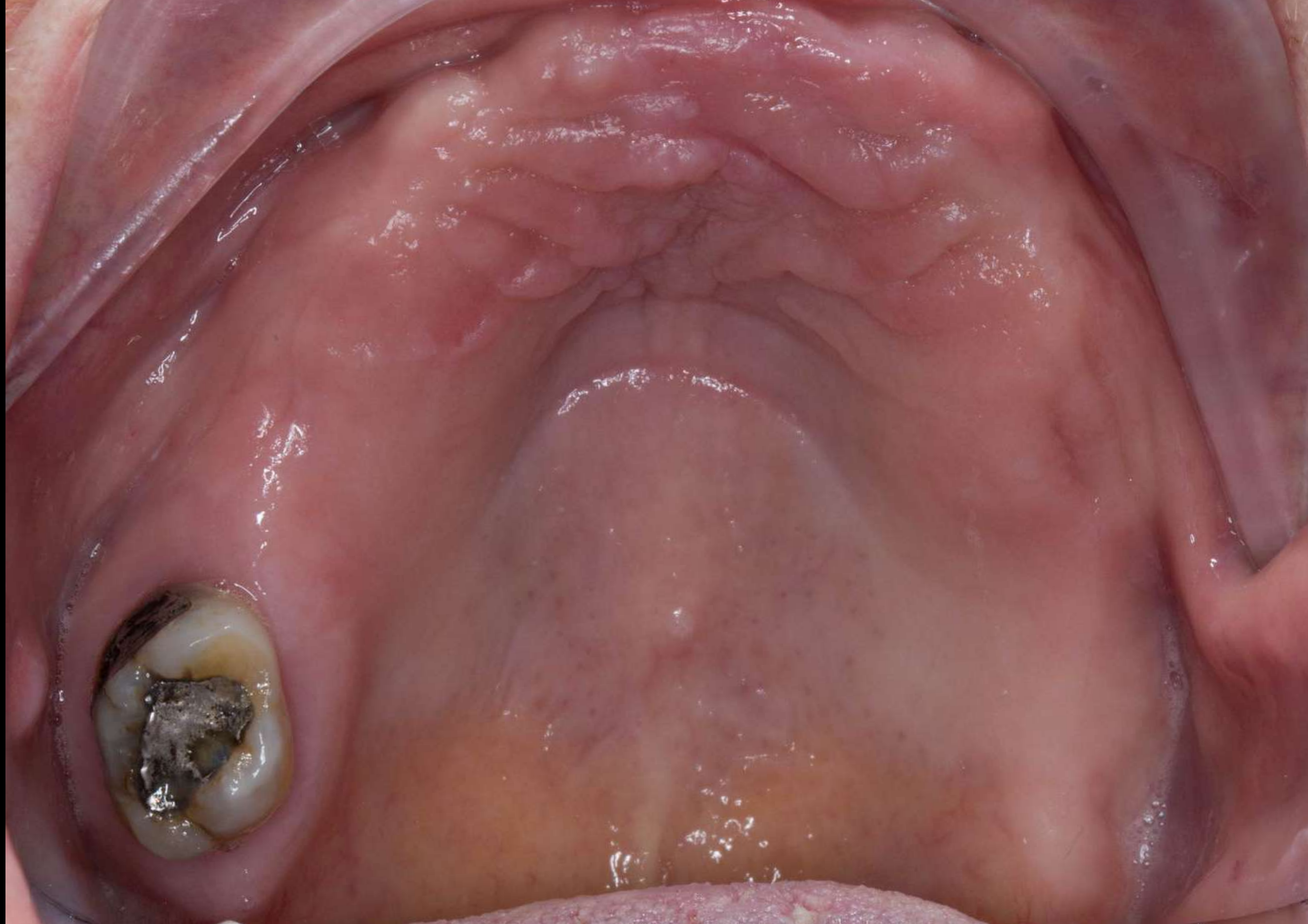
Schottlander Enigmallife + K24B



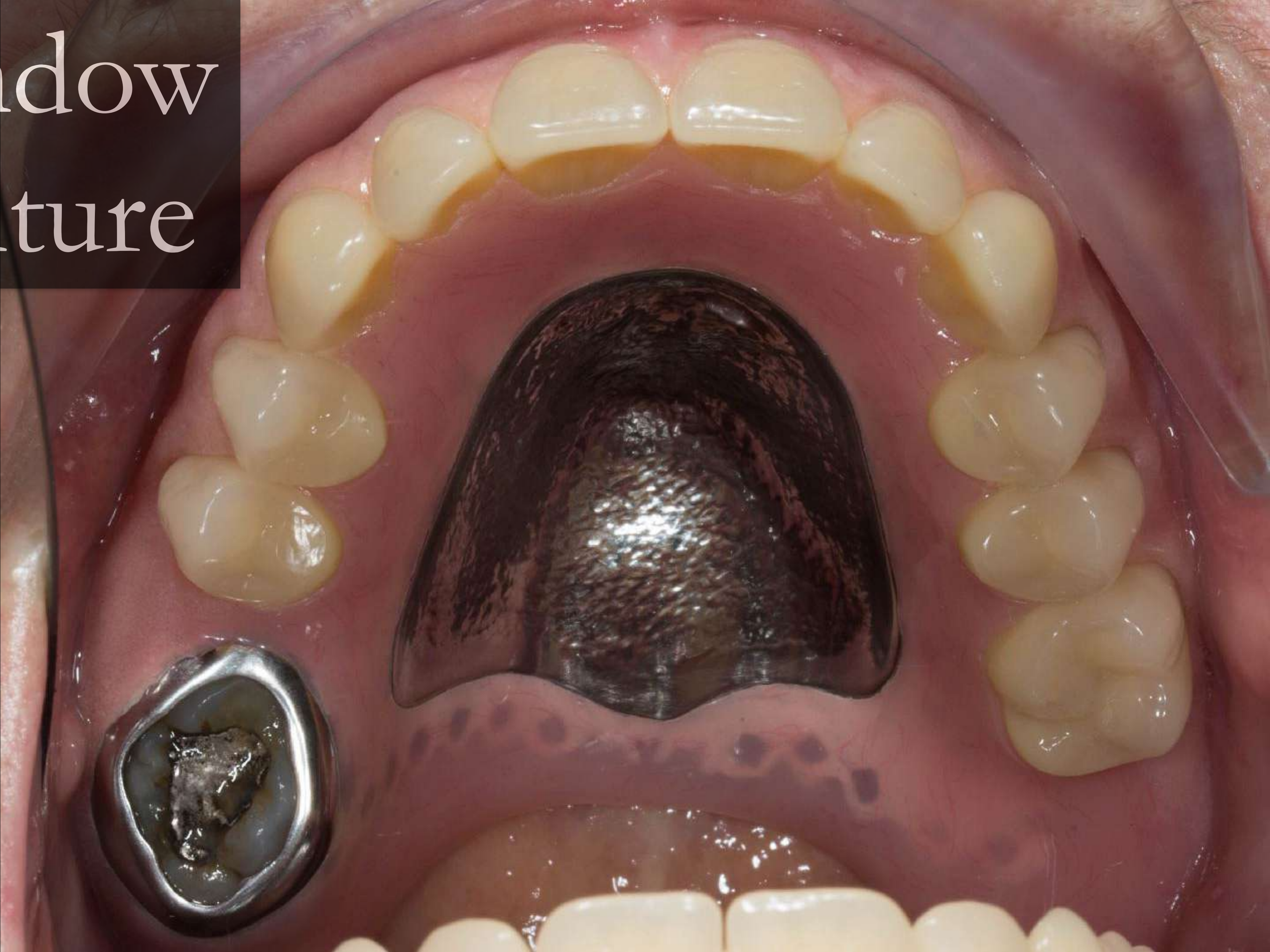5

Partial dentures

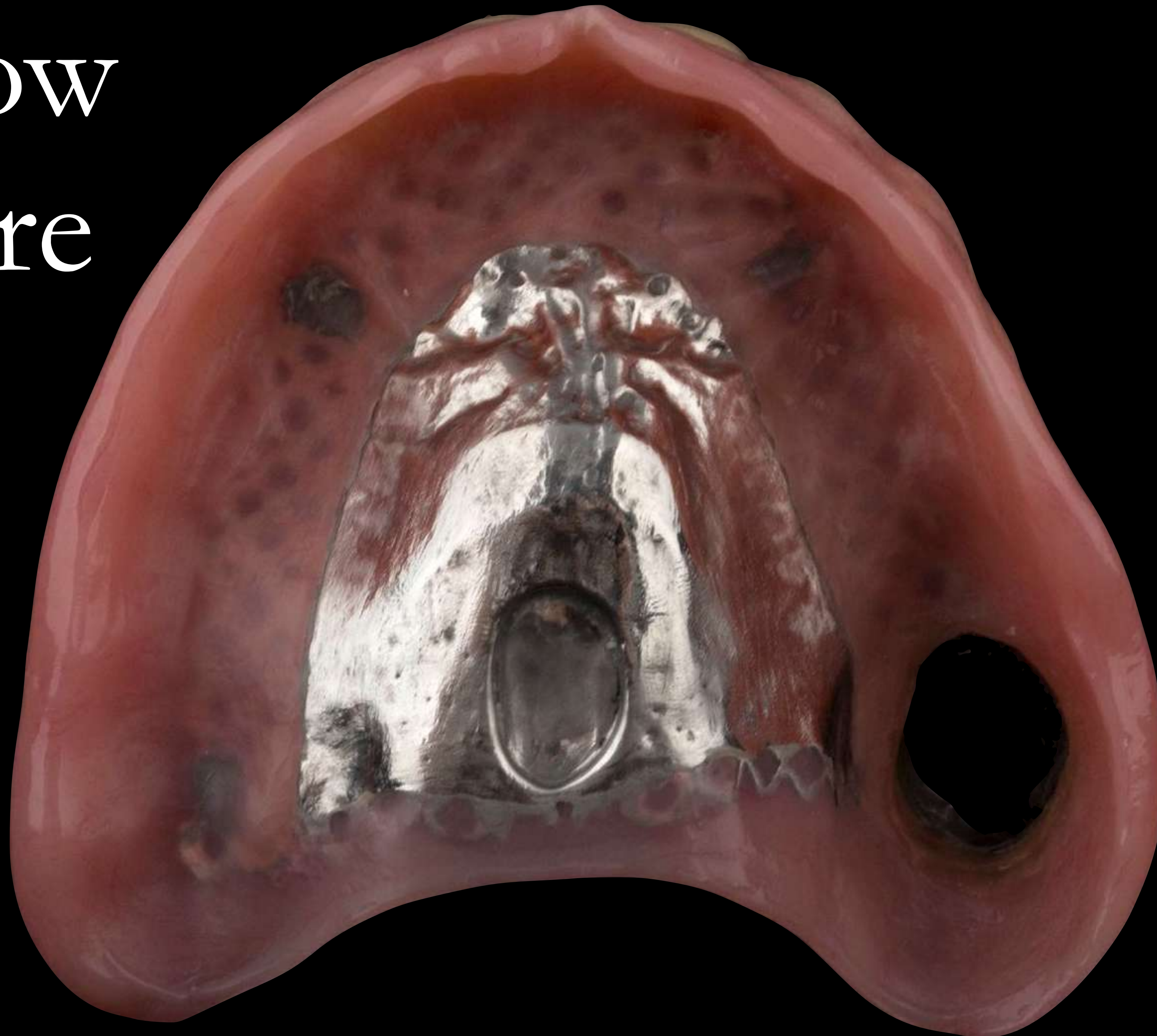

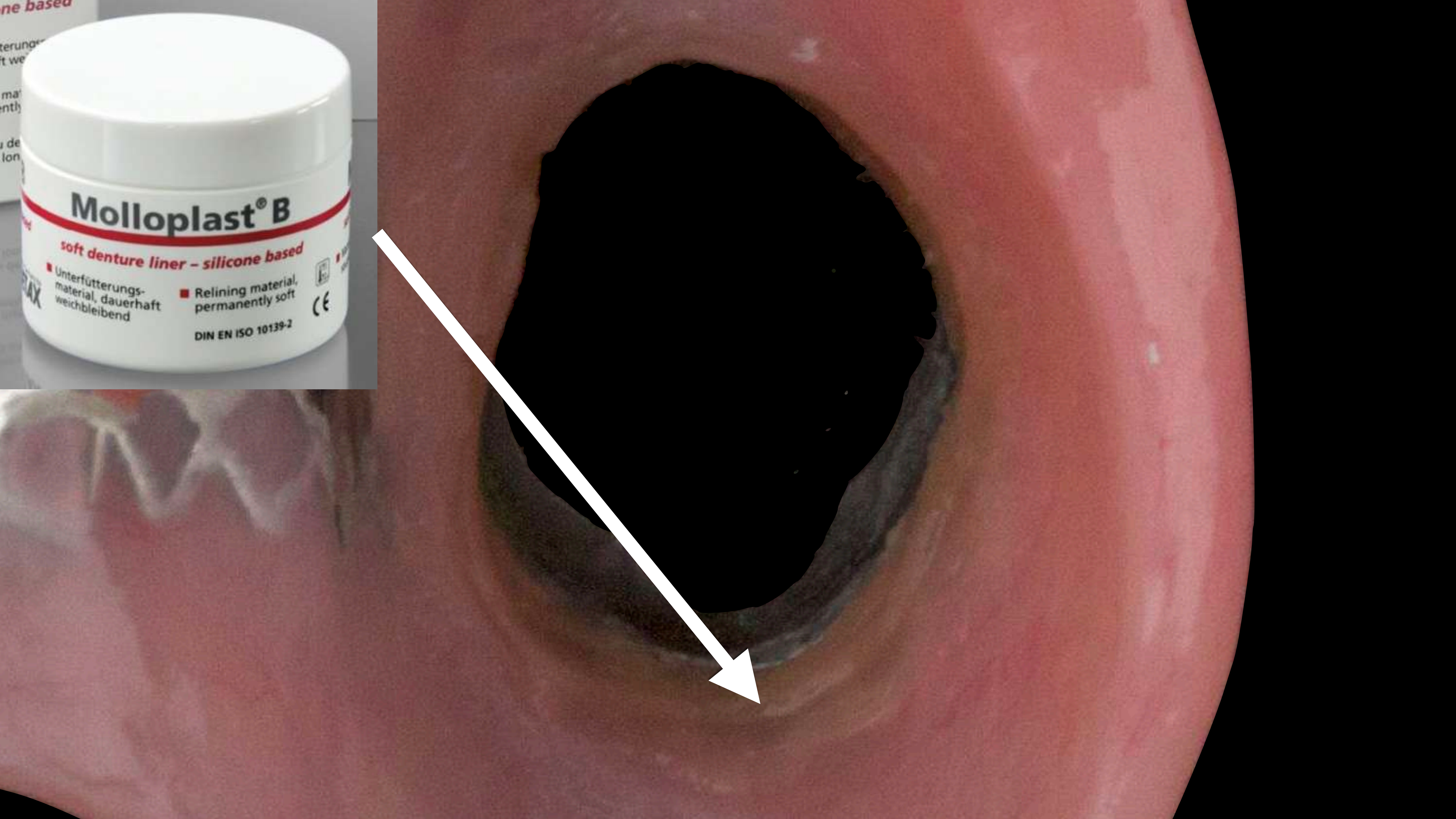

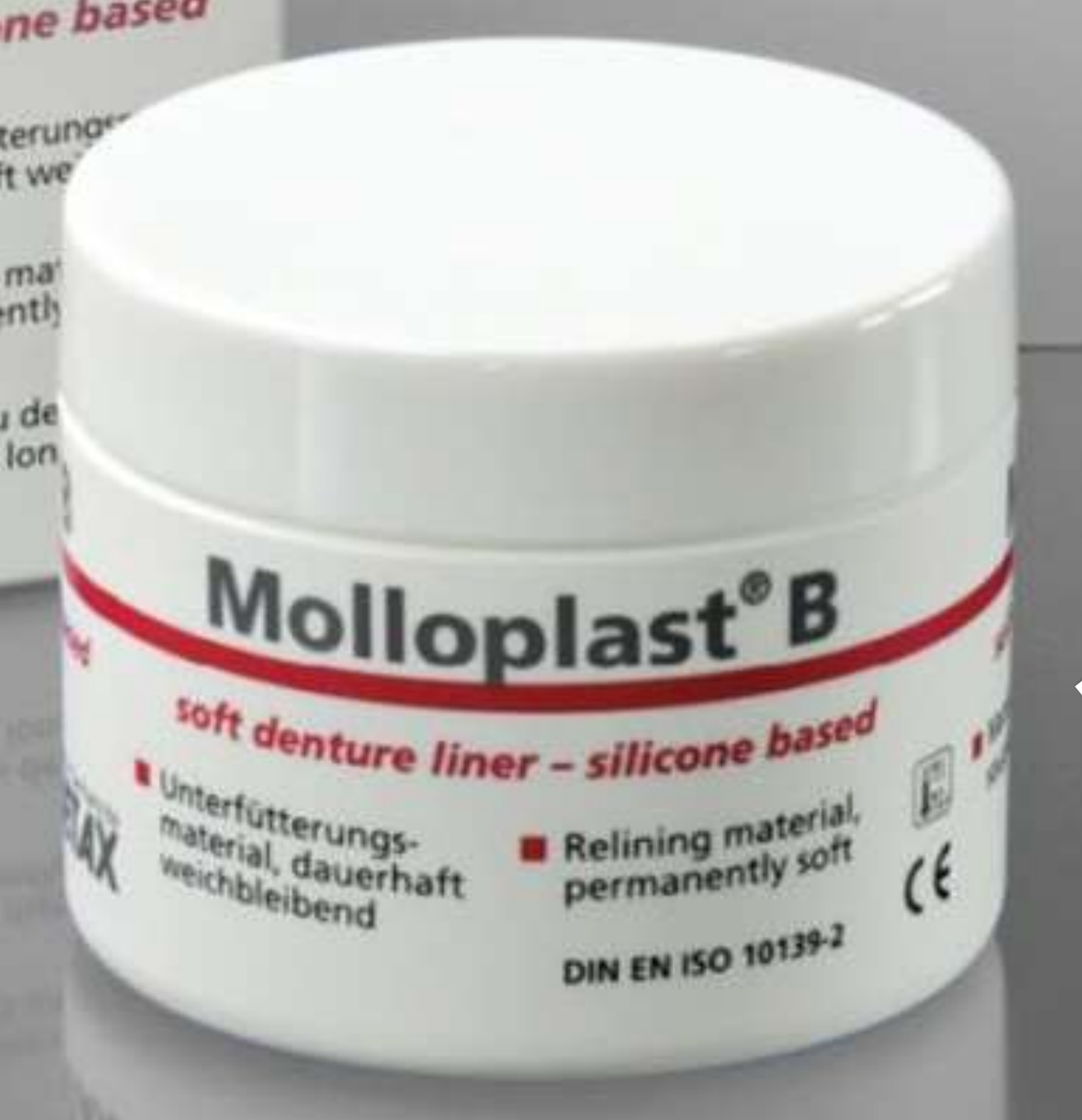
Window denture

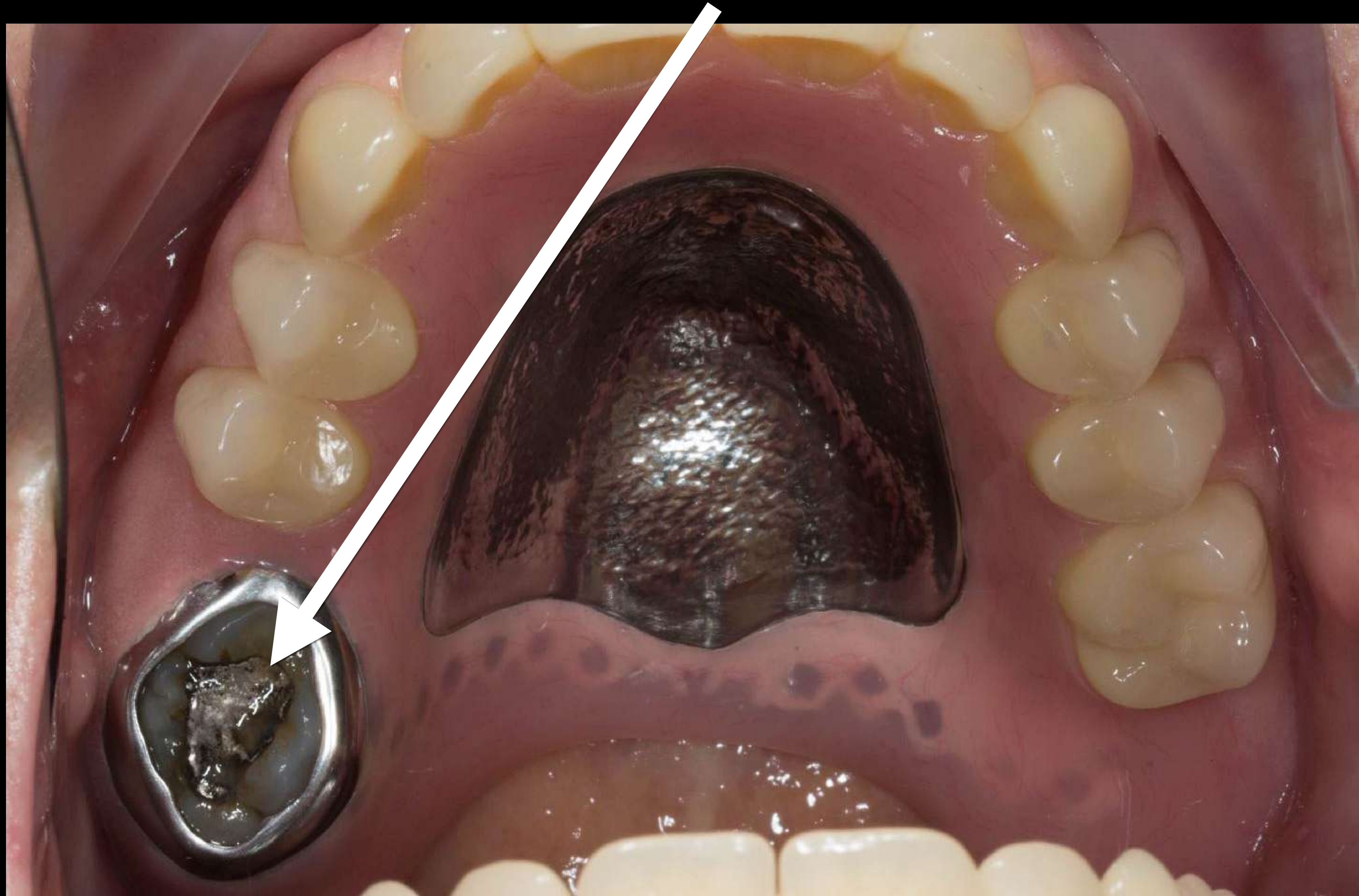

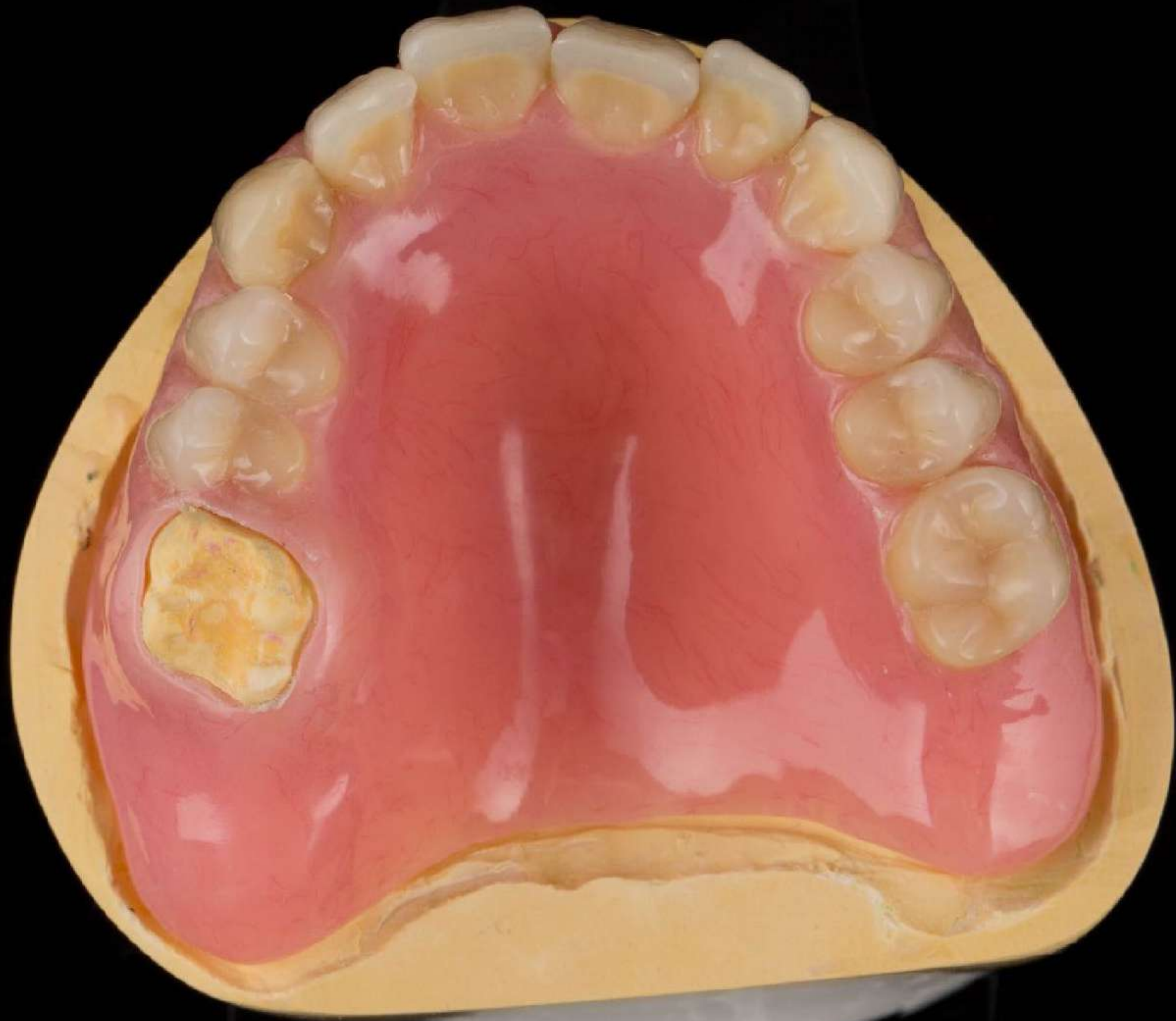Window
denture

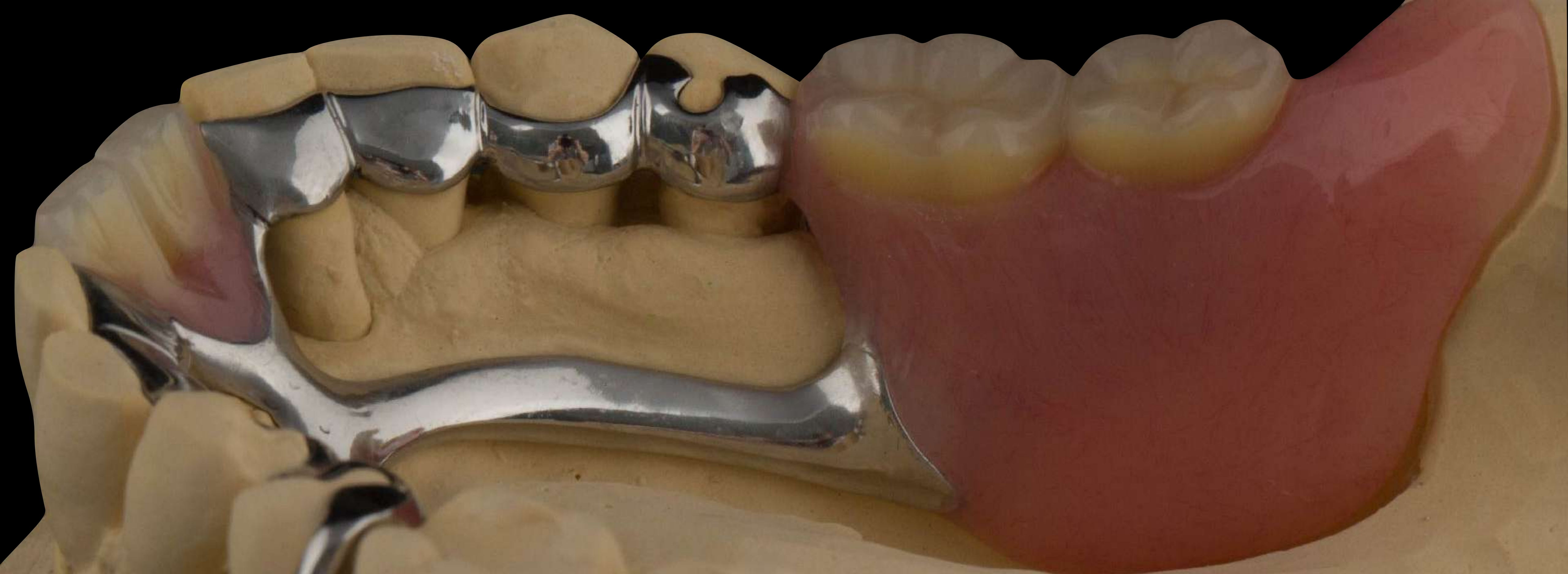




If support tooth fails - addition to convert to complete denture



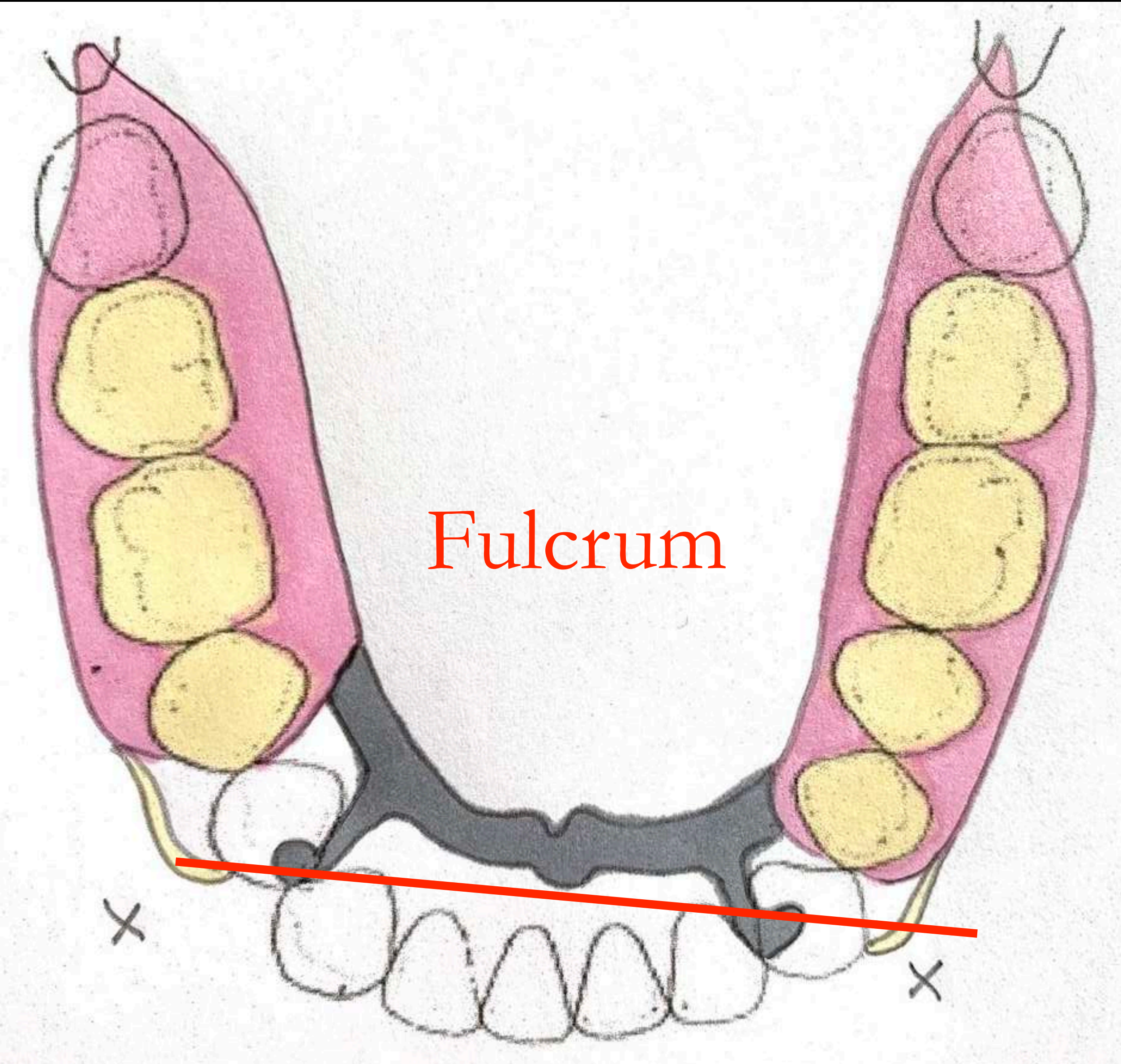




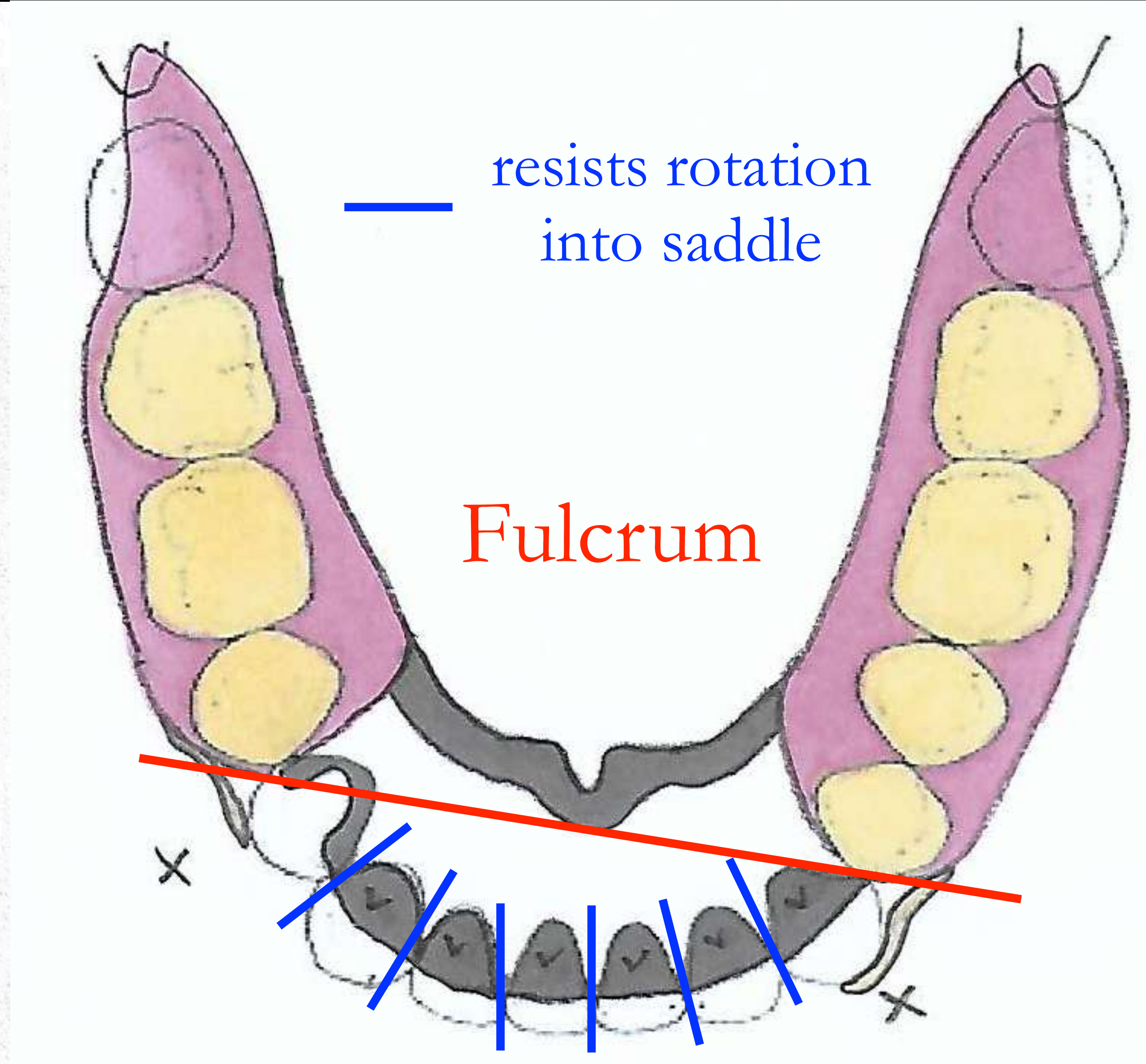
RPD design: a need to focus on Hygienic Principles.

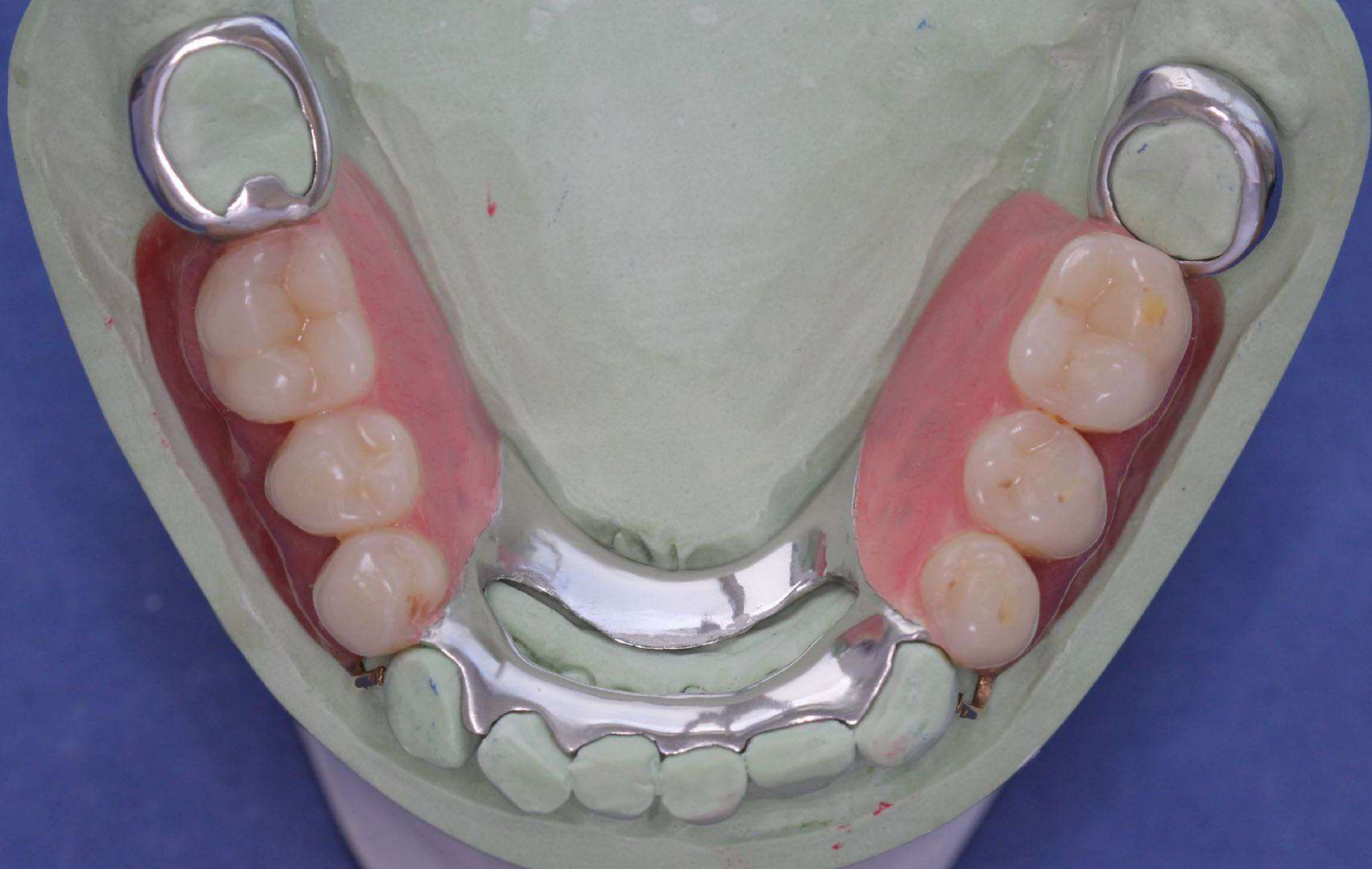Öwall B et al Int J Pros 2002

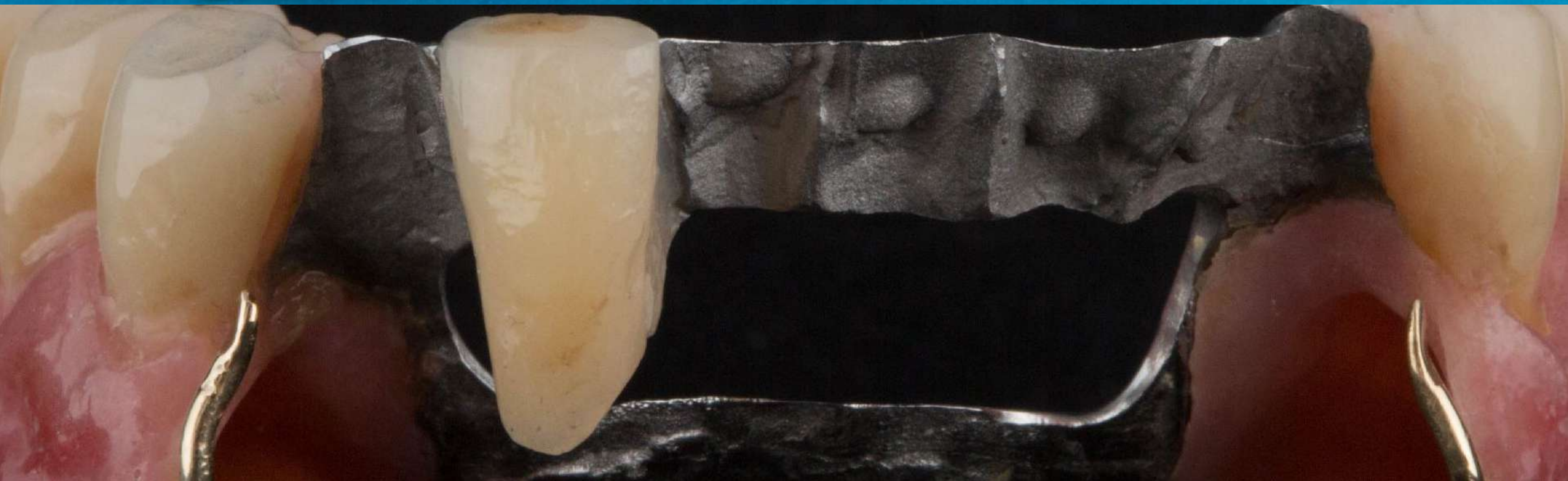RPI system



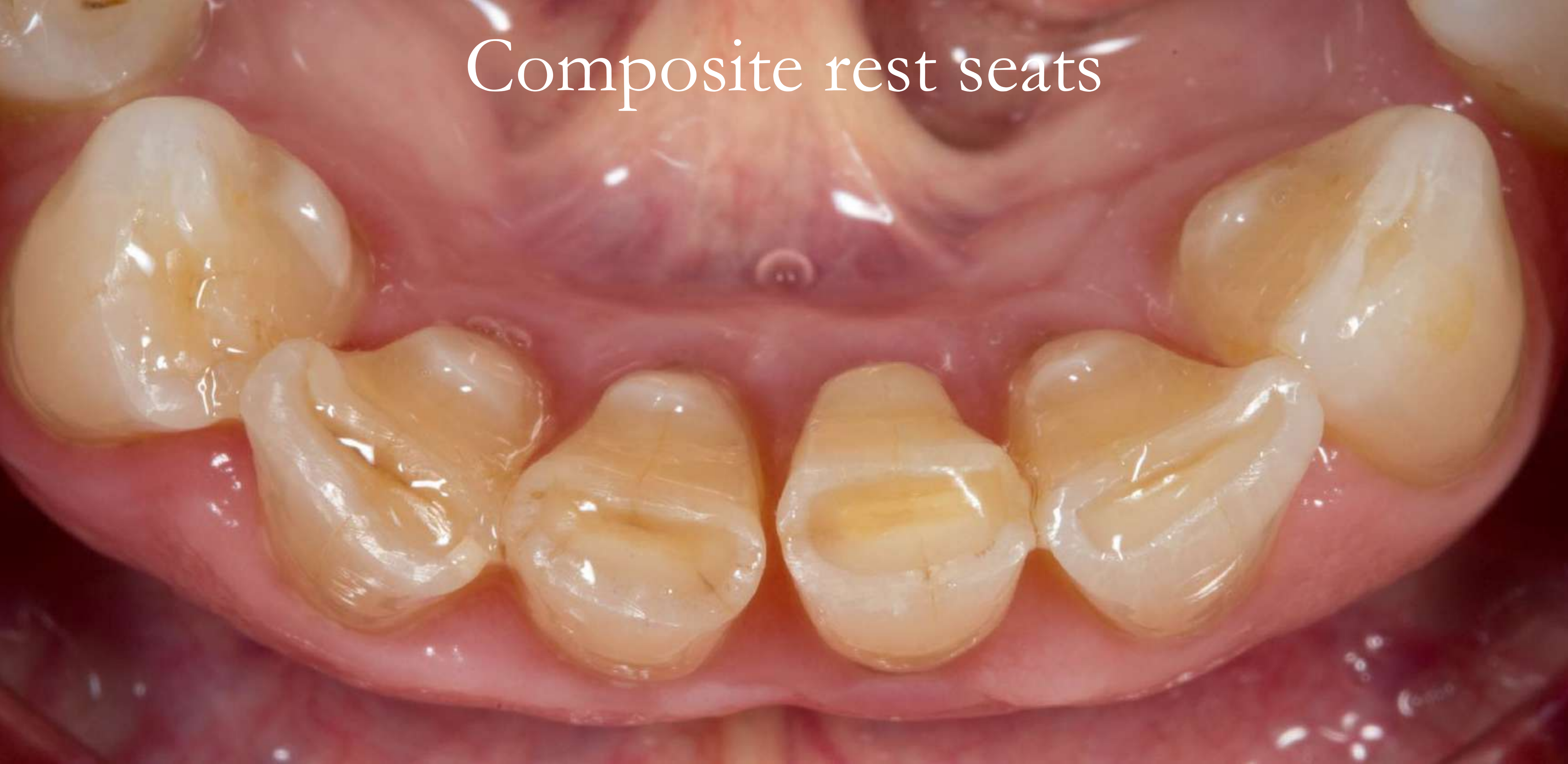v Scandinavian RPD system



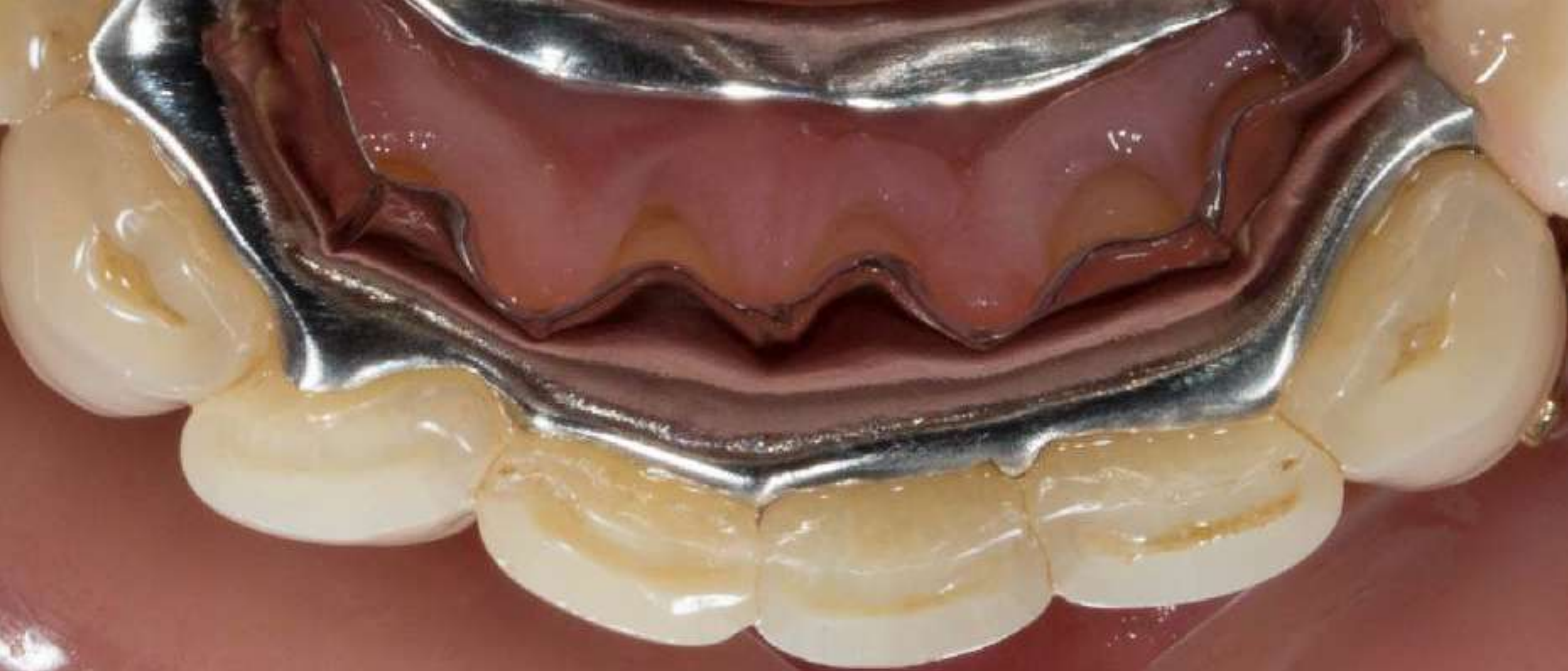

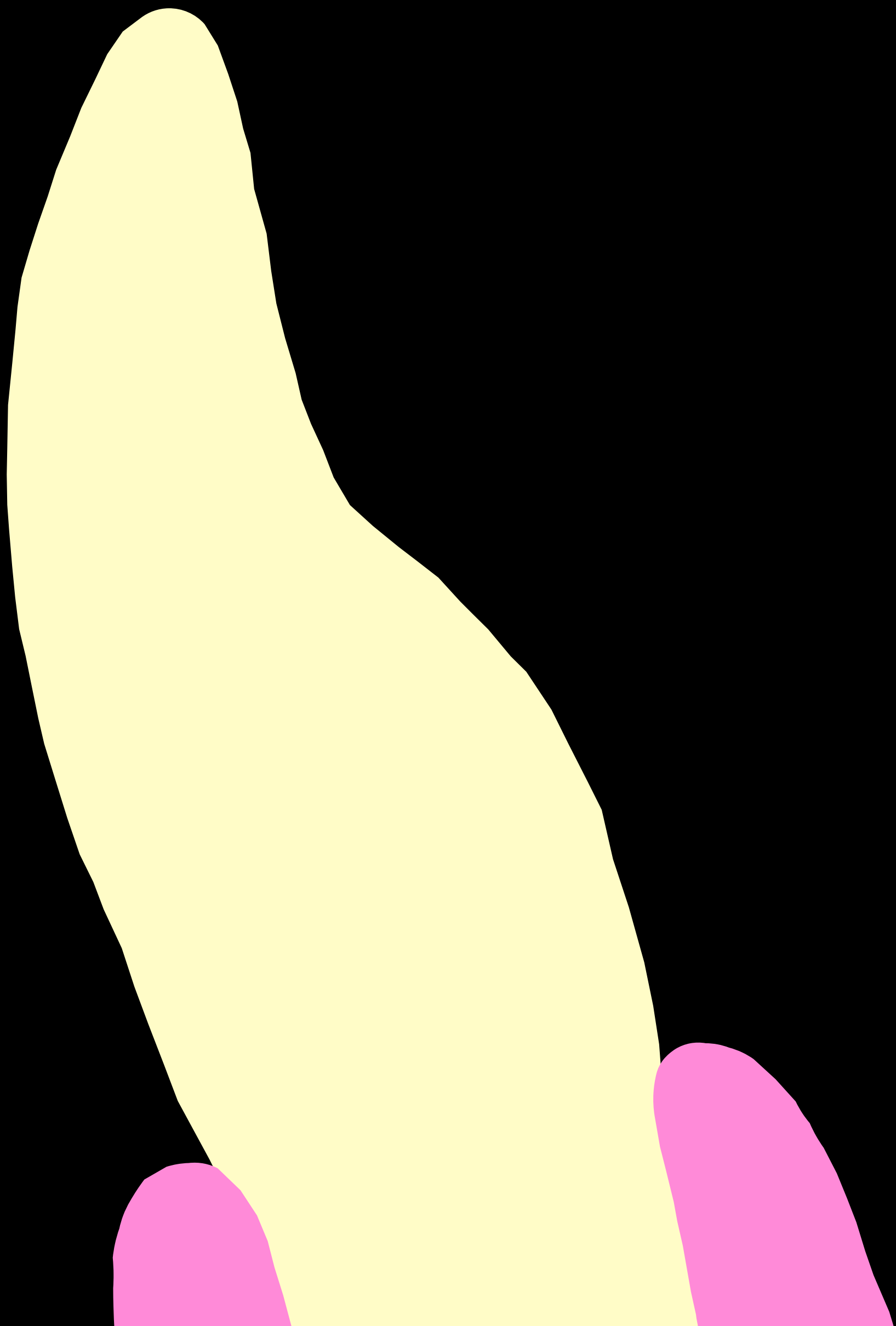



Composite rest seats

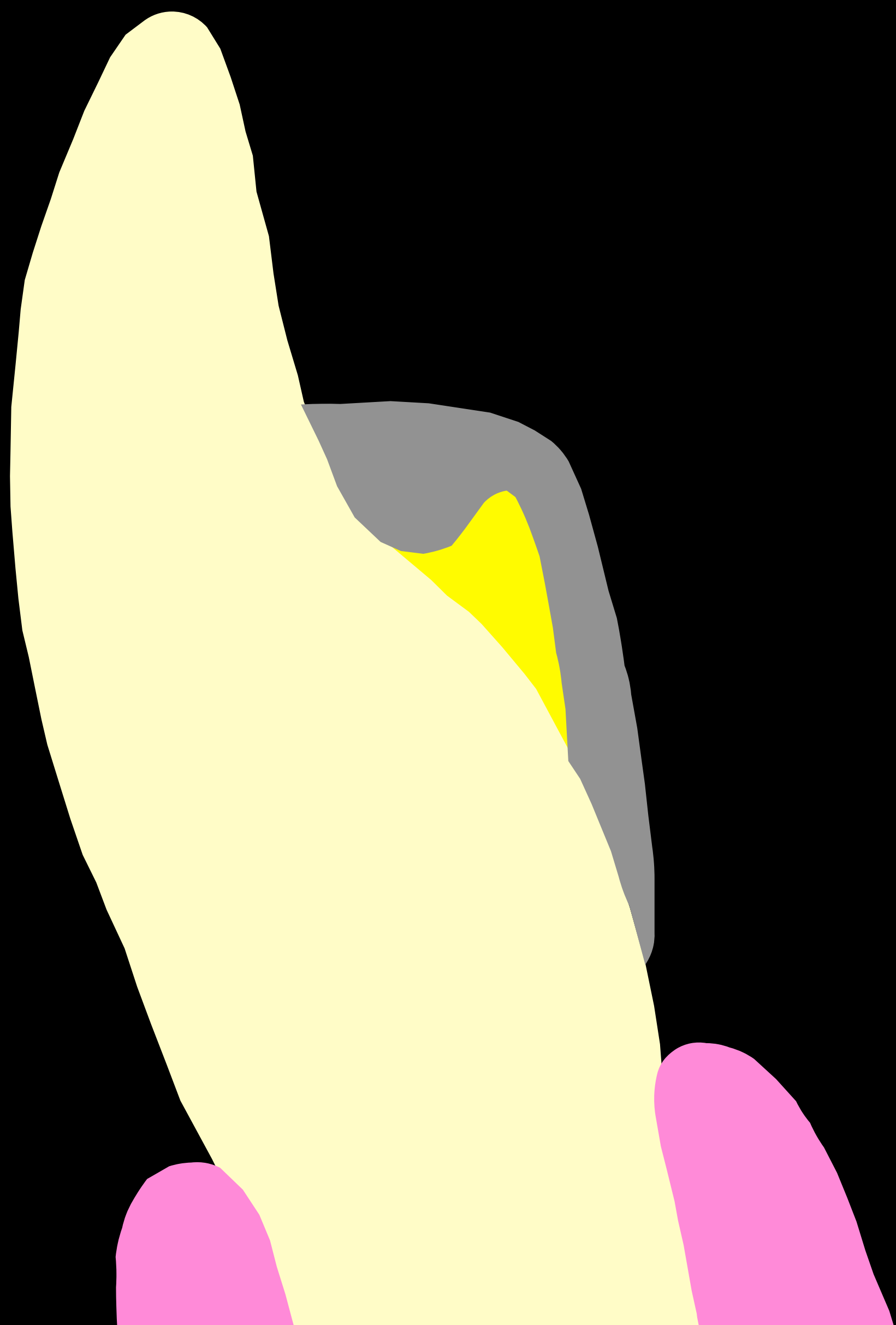



James S Brudvik

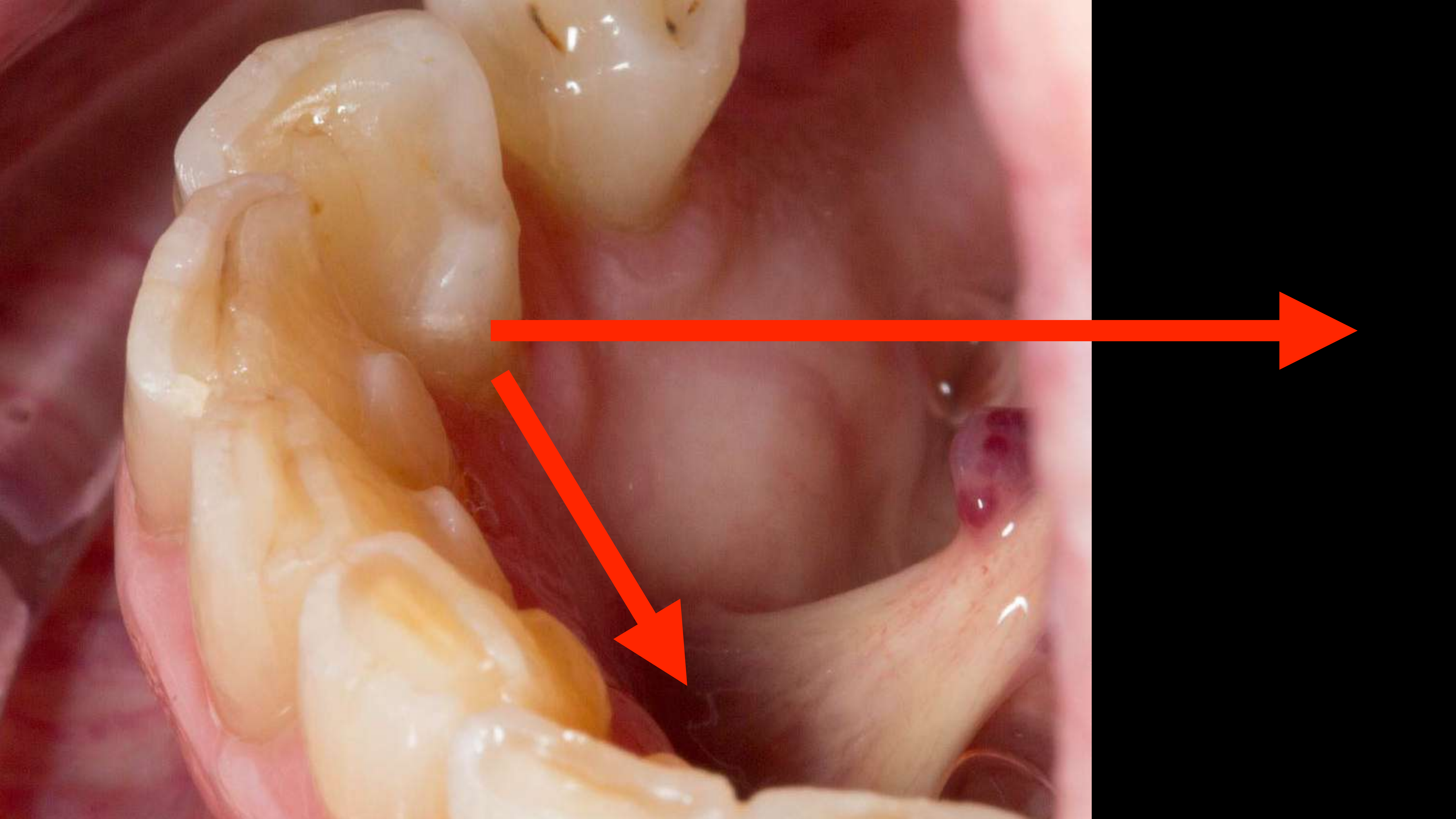


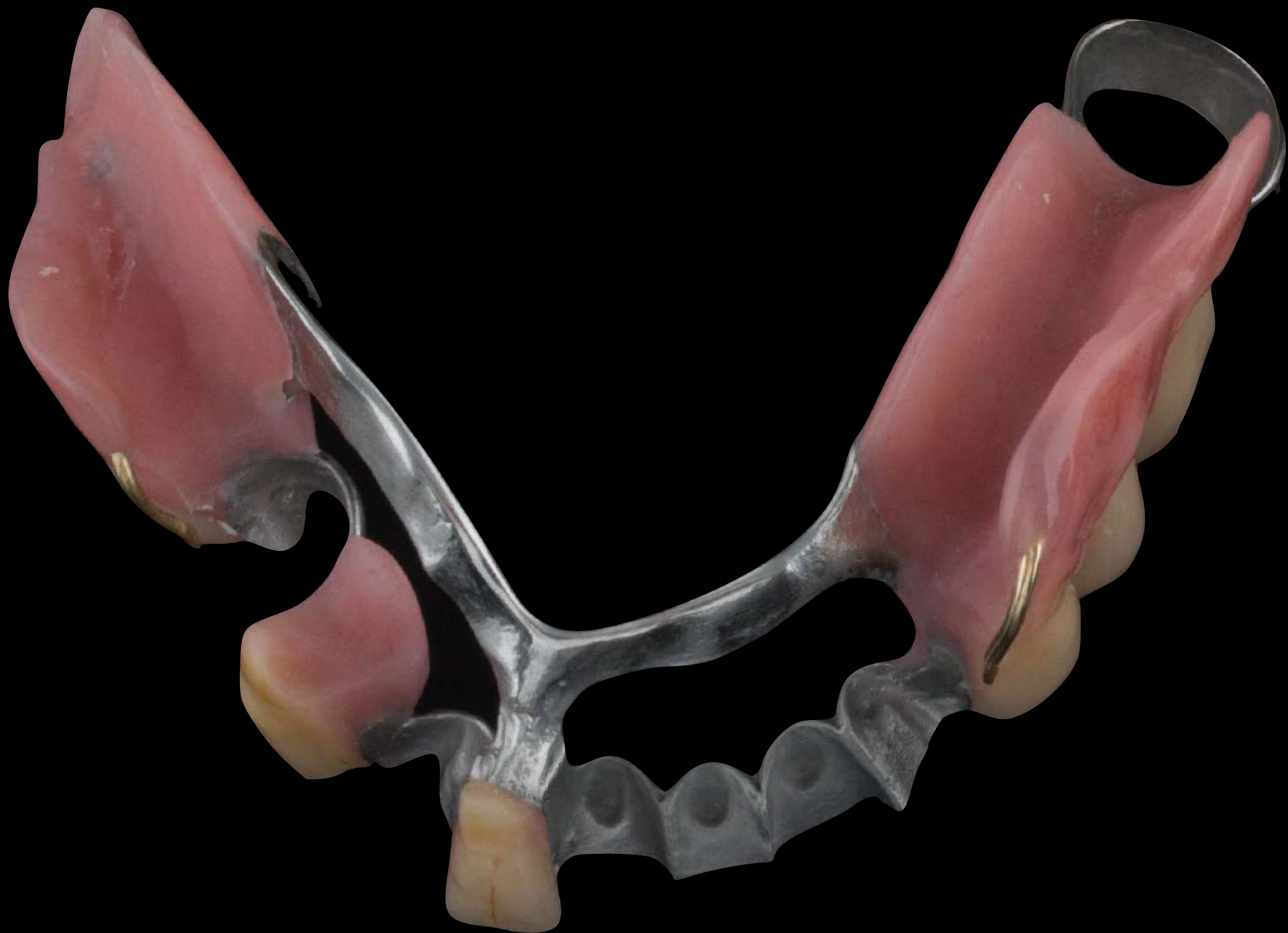




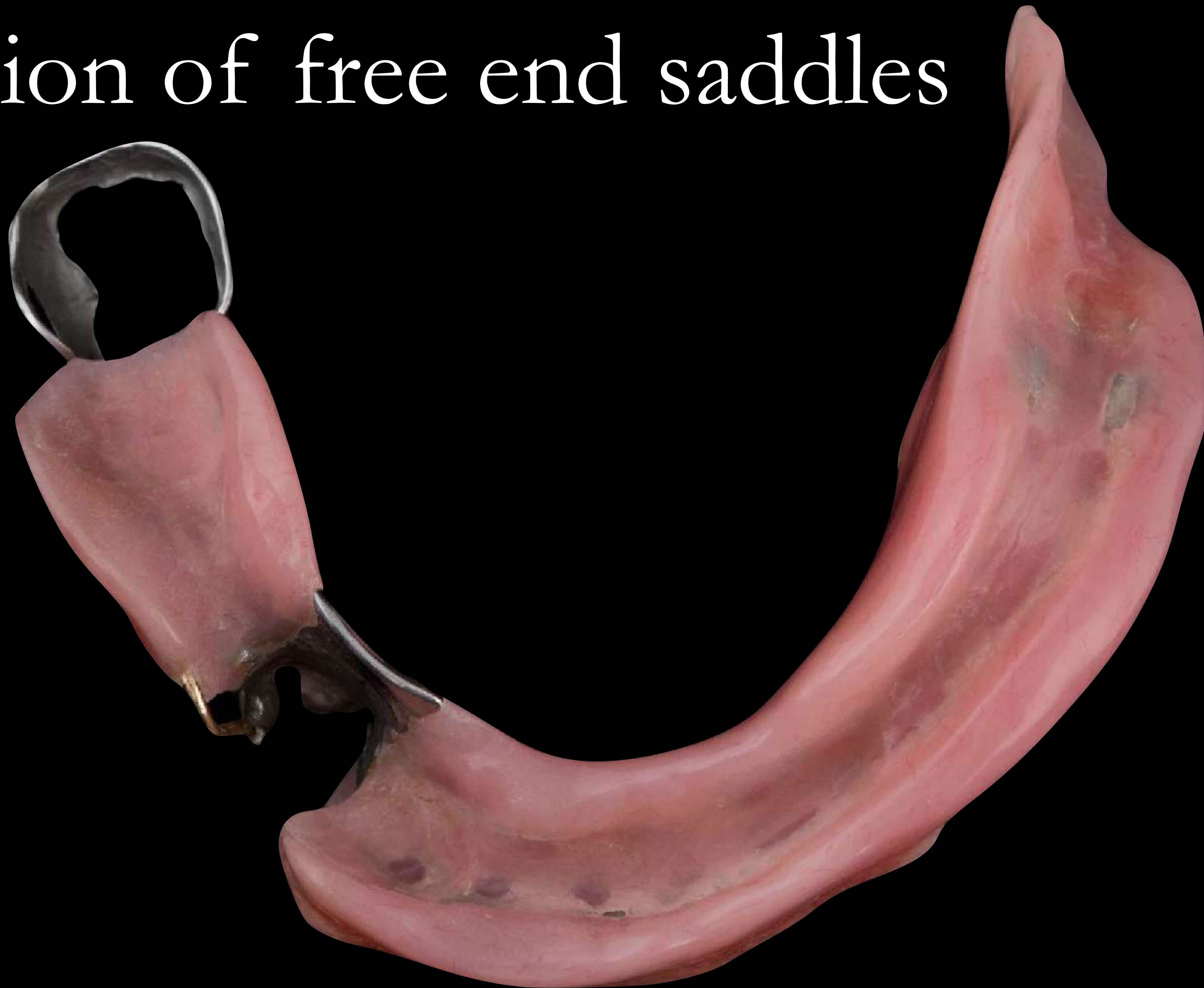


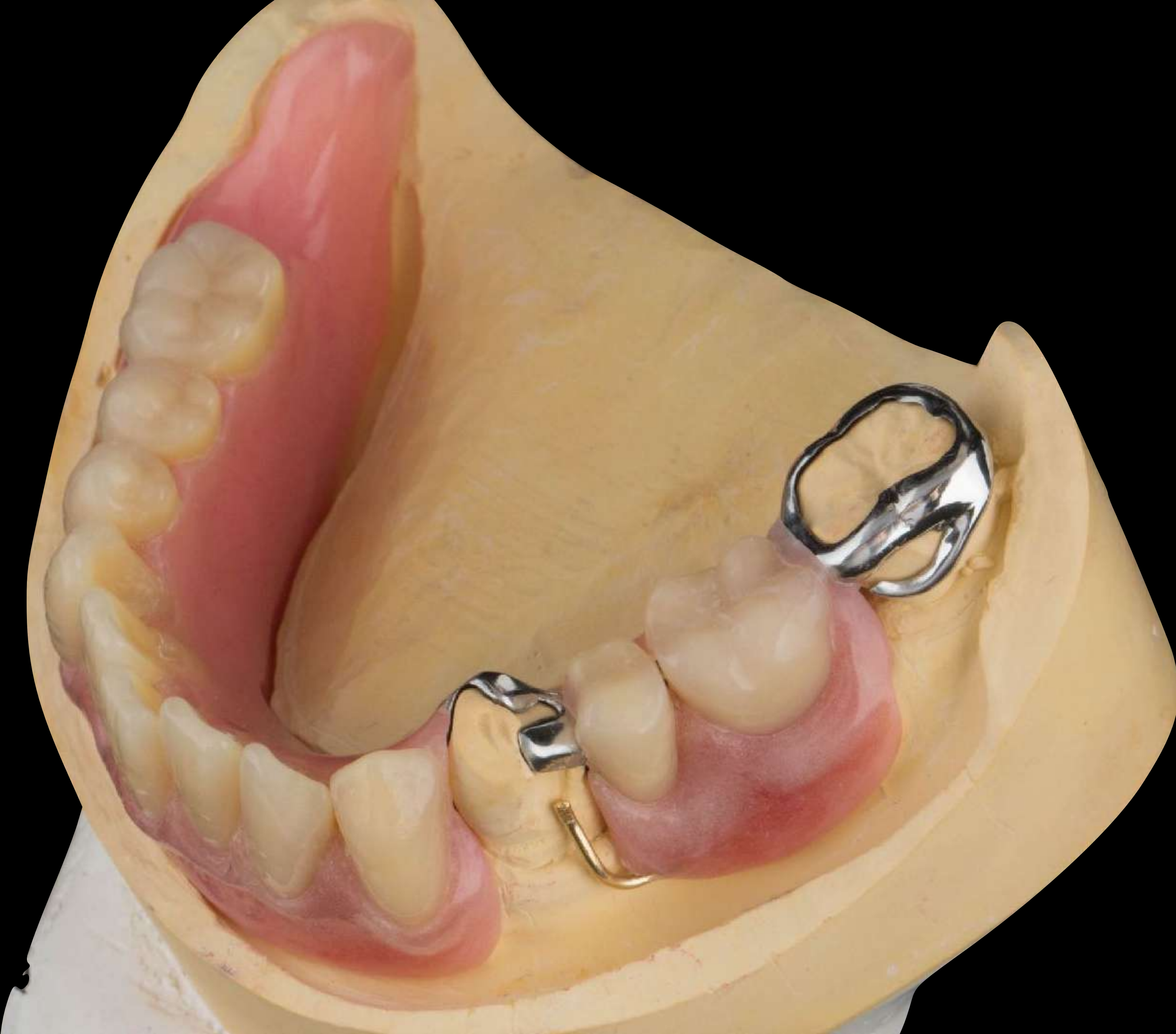




Extension of free end saddles





2 clasps
per
denture

A large, stylized number 6 is centered within a white, 3D-rendered column structure. The column has a wide base, a narrower middle section, and a wide top section, all with a slight gradient and shadow. The background is solid black.

6

Patient
communication



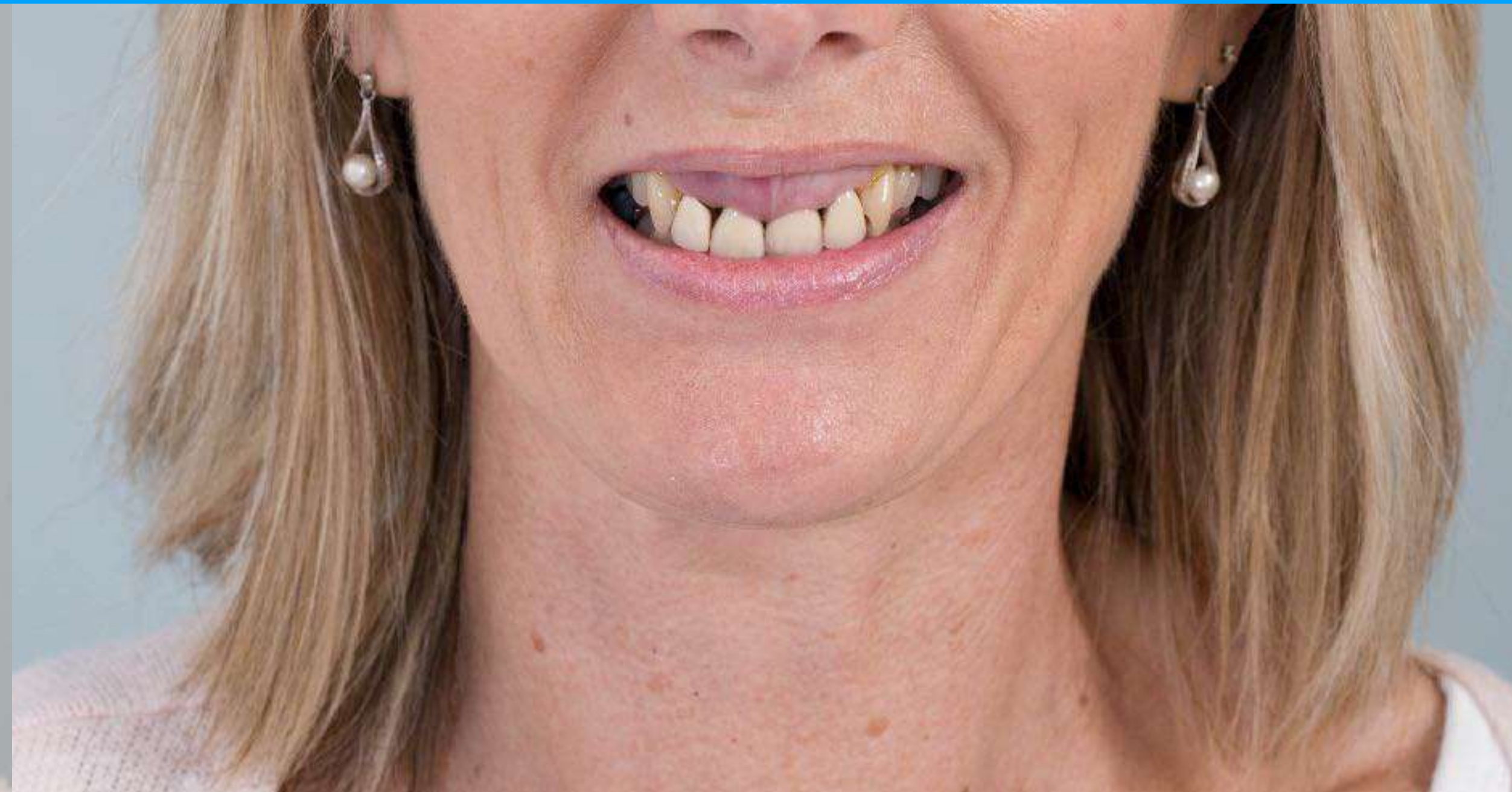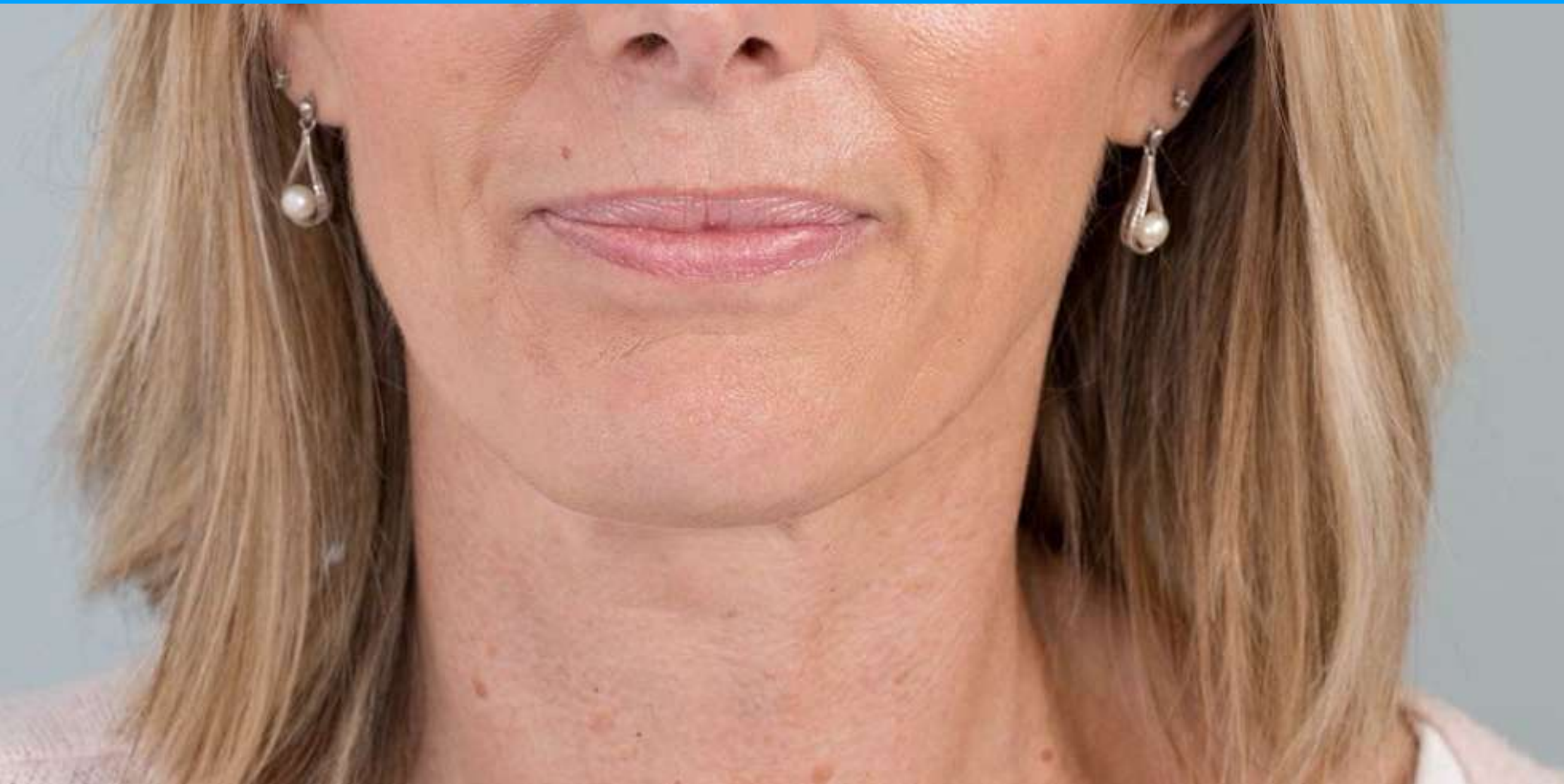Consultation discussion

Over
promise

Under
deliver

Under
promise

Over
deliver



Concerns

“Front teeth”

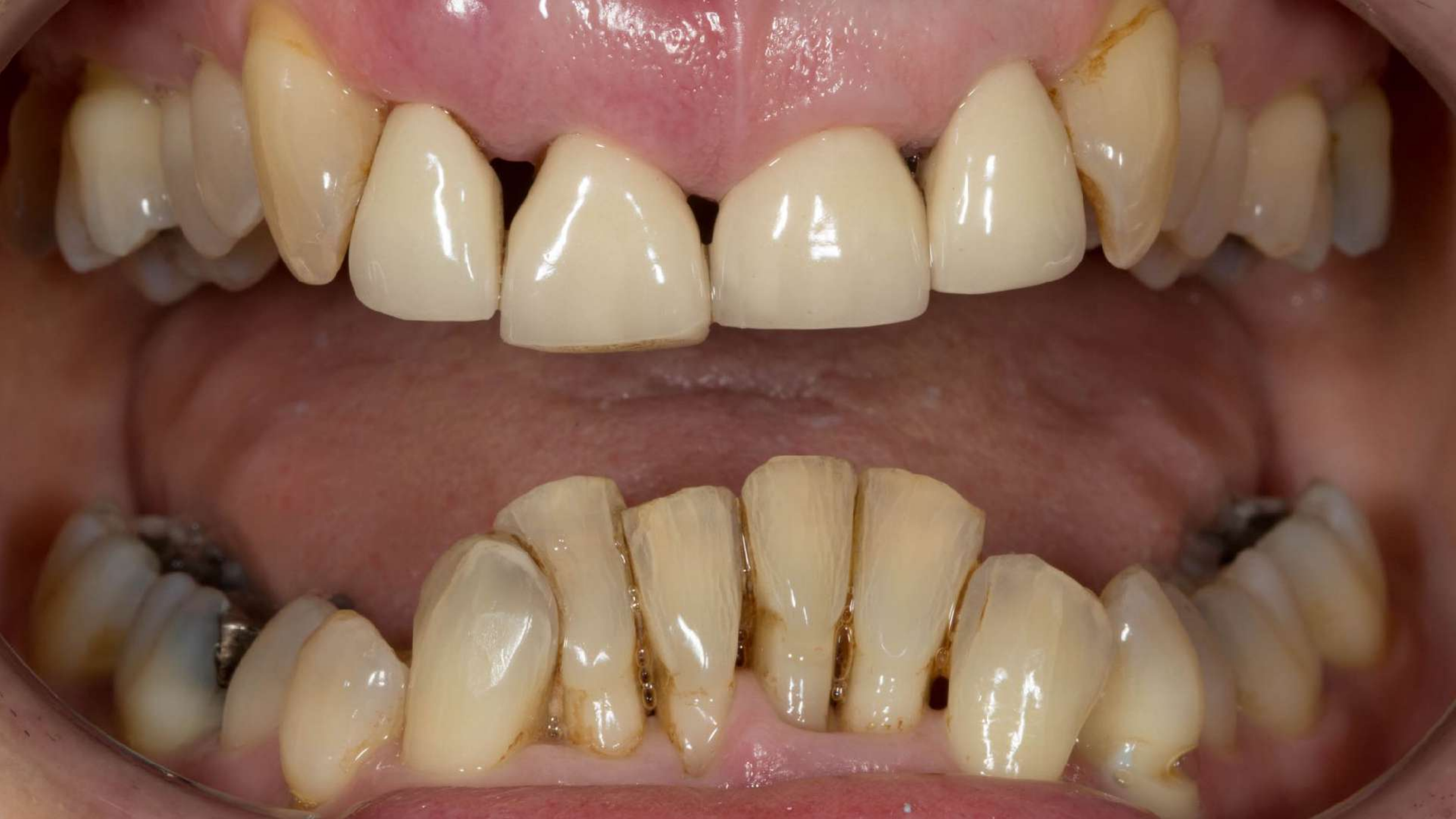“Overbite”

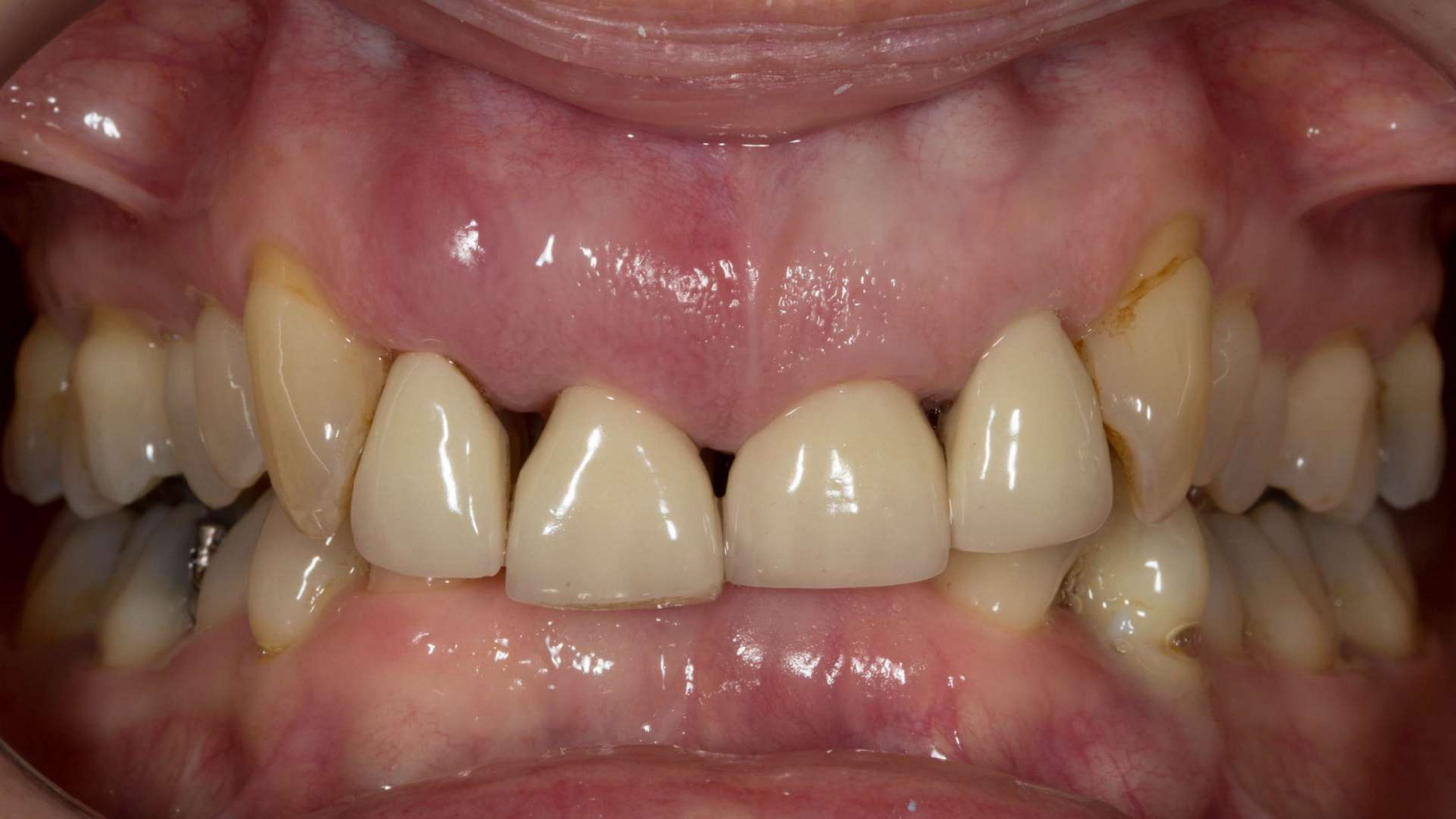“Gums”

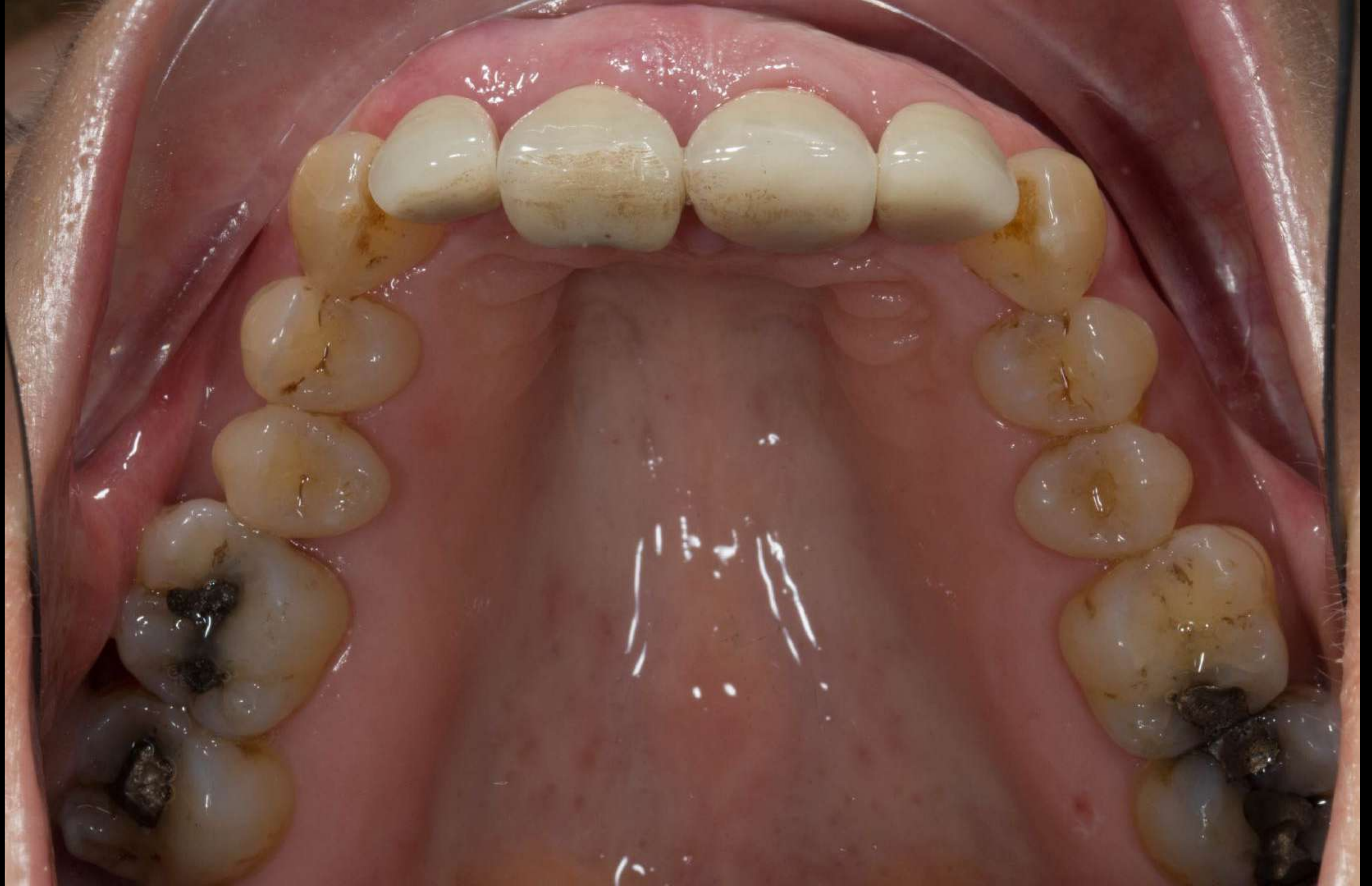Wish list

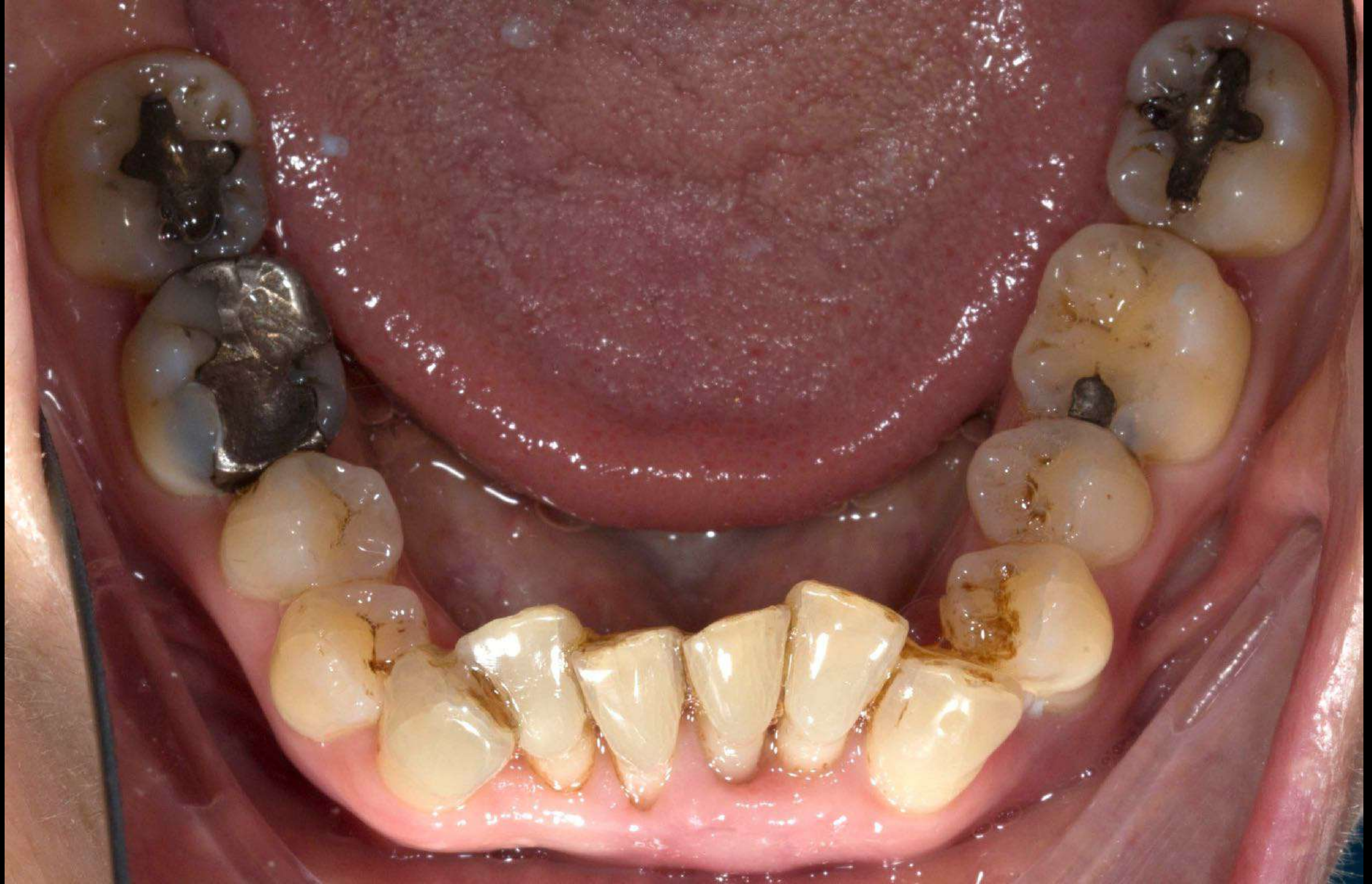“An improved smile”

“Healthy gums”

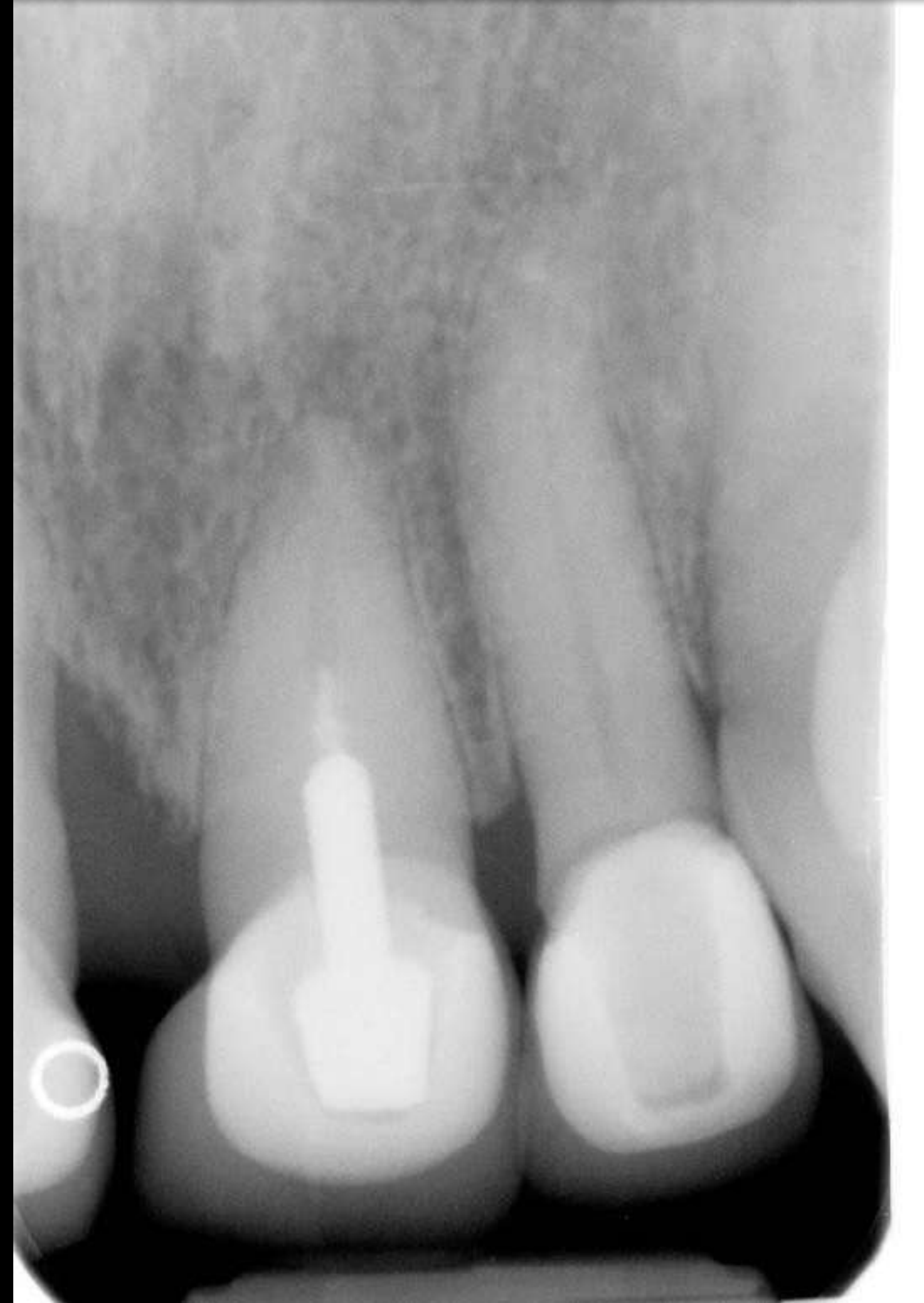
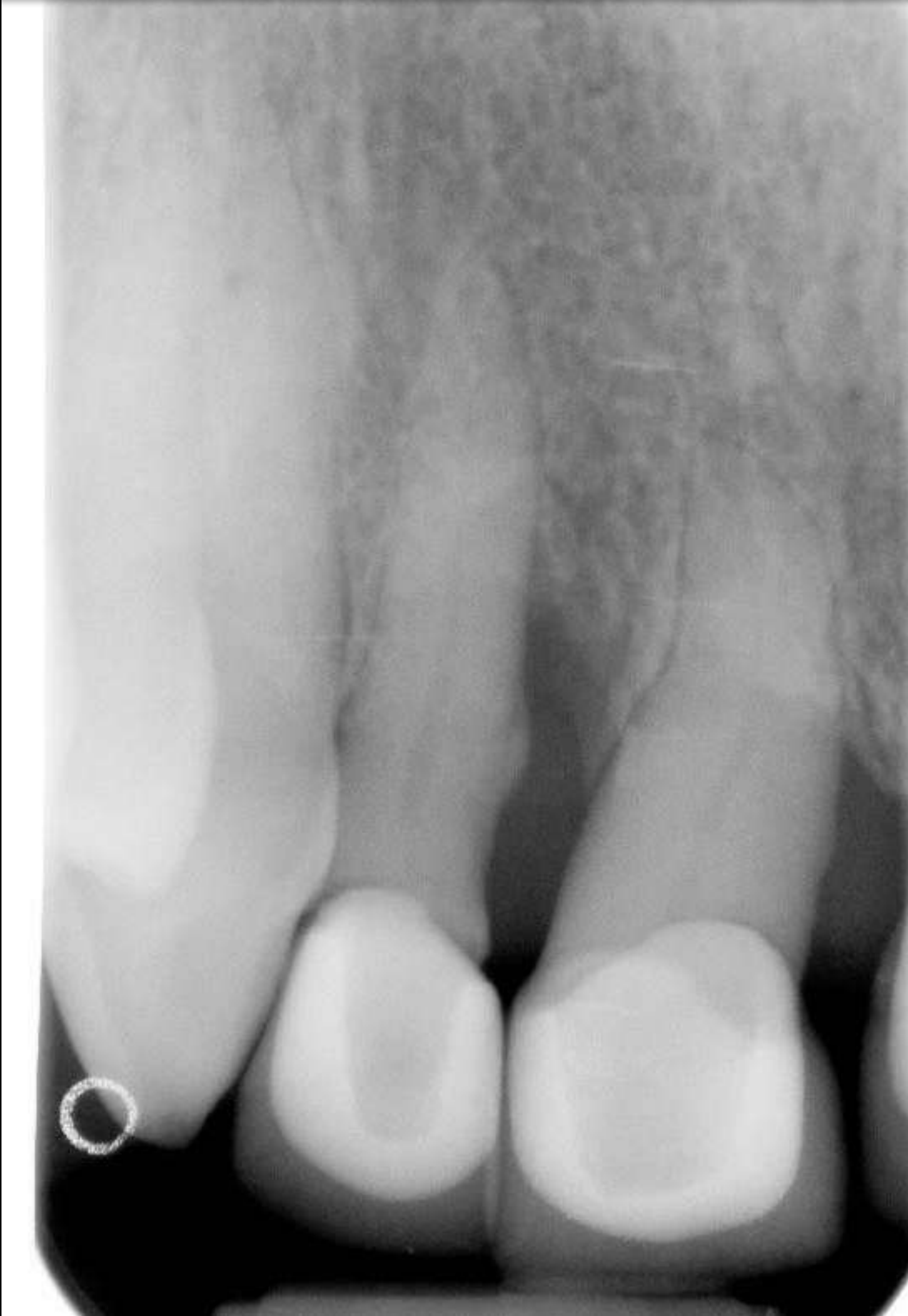
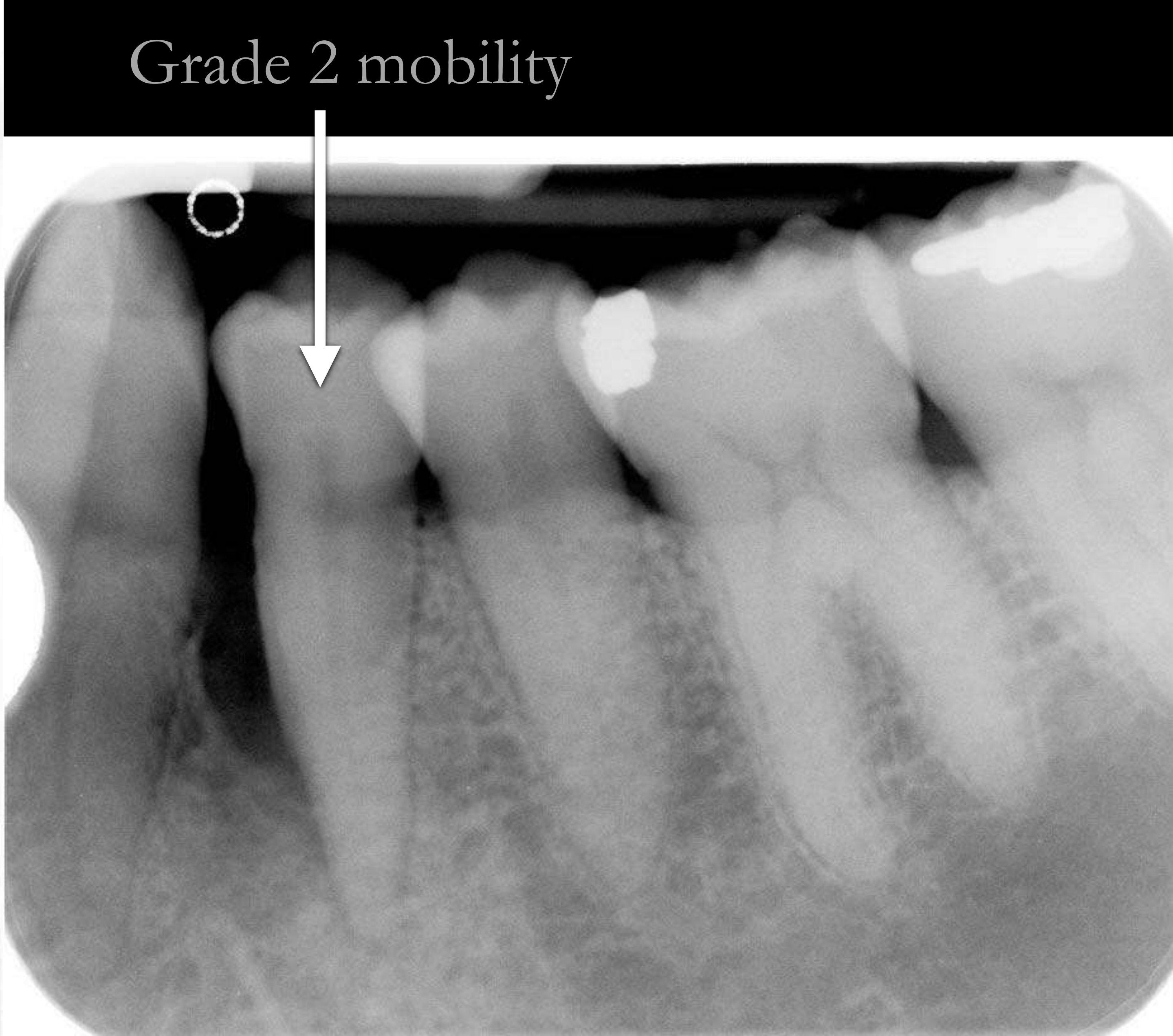


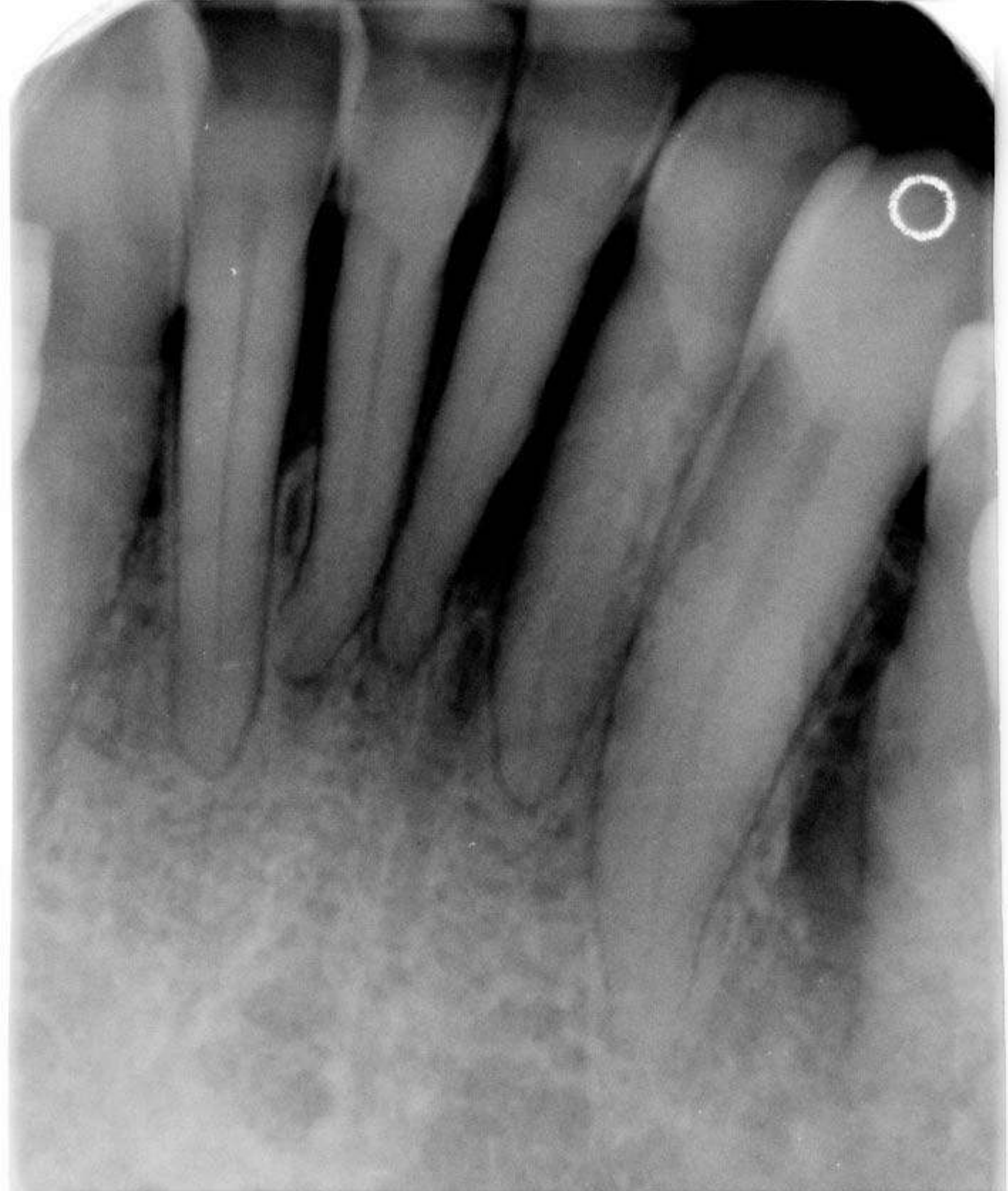



Localised periodontitis stage 4 (very severe) Grade C (rapid progression)





Localised periodontitis stage 4 (very severe) Grade C (rapid progression)

A close-up photograph of the upper teeth, showing the incisors and canines. The teeth are yellowish-white with some staining. A semi-transparent dark grey rectangular box is overlaid in the center, containing white text. The text reads "Mk 1 Immediate P/P" on the first line, "9 months" on the second line, and "Mk 2 P/P" on the third line.

Mk 1 Immediate P/P

9 months

Mk 2 P/P

Name: MF

Treatment plan No 1

Date estimate accepted:

Objective:

Preferred times:

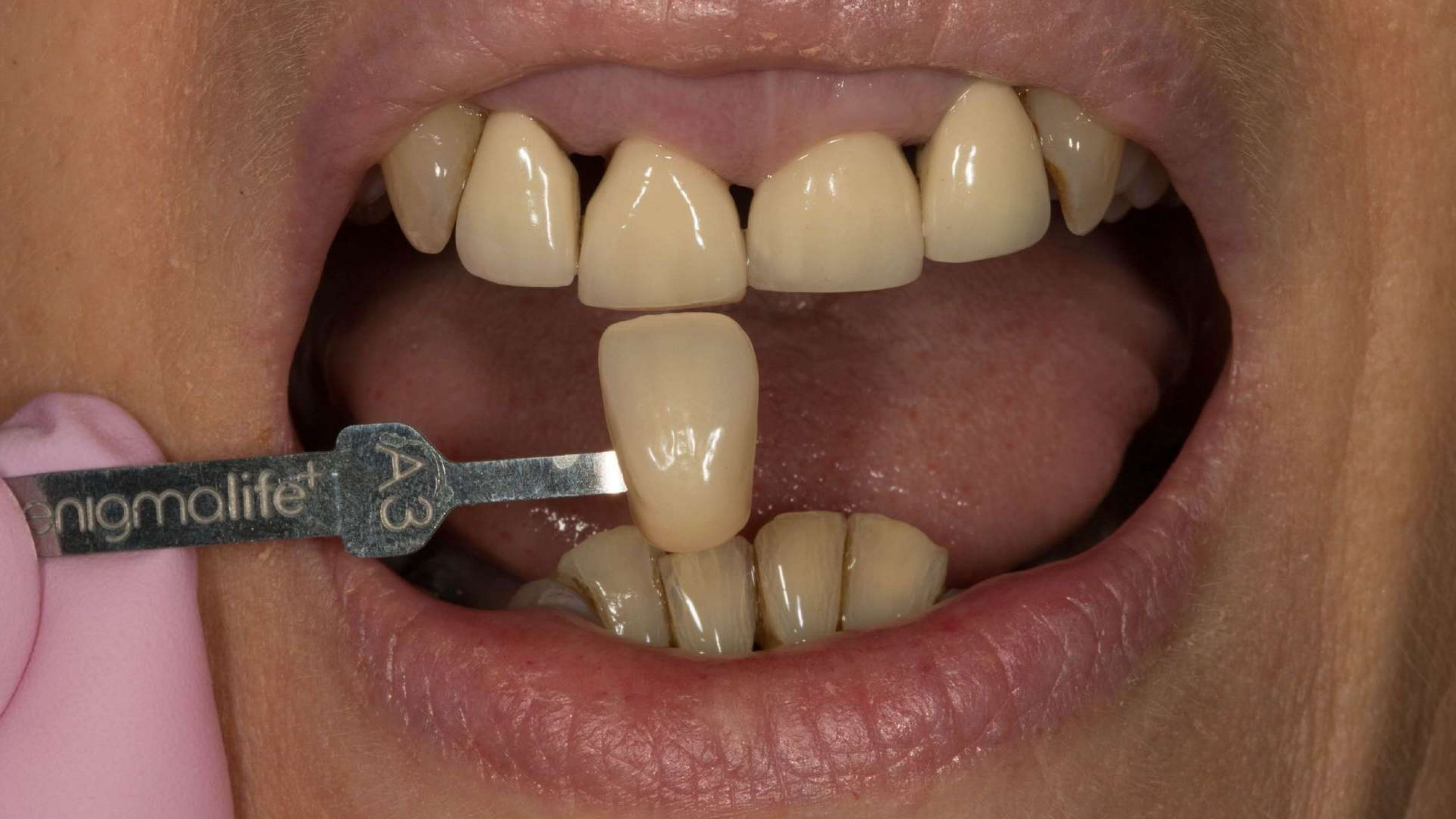
- Mk 1 Immediate interim partial denture with removal of upper 2-2
- Teeth whitening – only if wanted no cost extra
- Periodontal therapy – Syed Abad after visit 3.
- Ensure the Mk 2 denture is made to accommodate ideal arrangement of lower 2-2 which may be restored with a resin bonded bridge
- Mk 2 Definitive metal based partial dentures upper 2-2

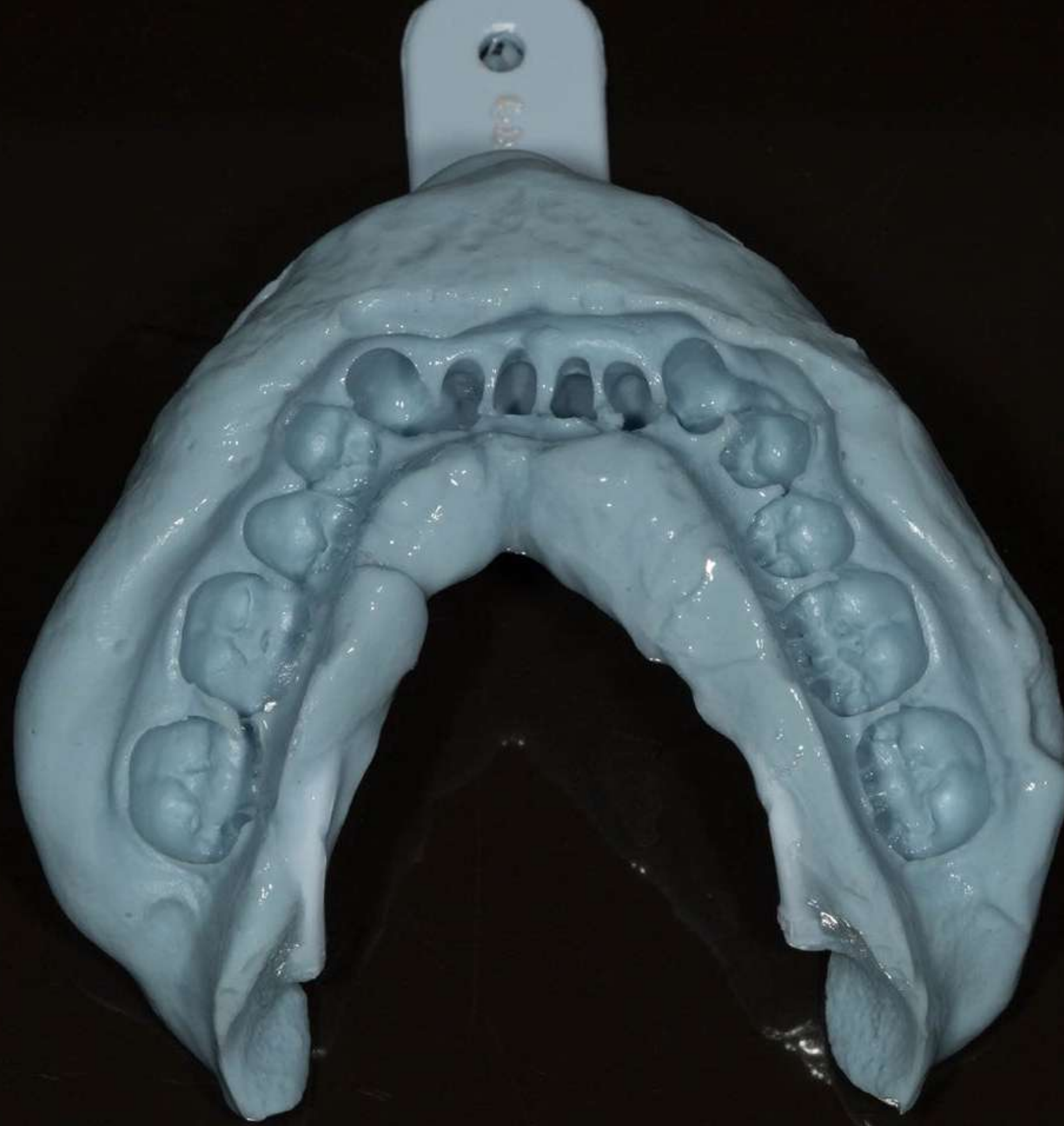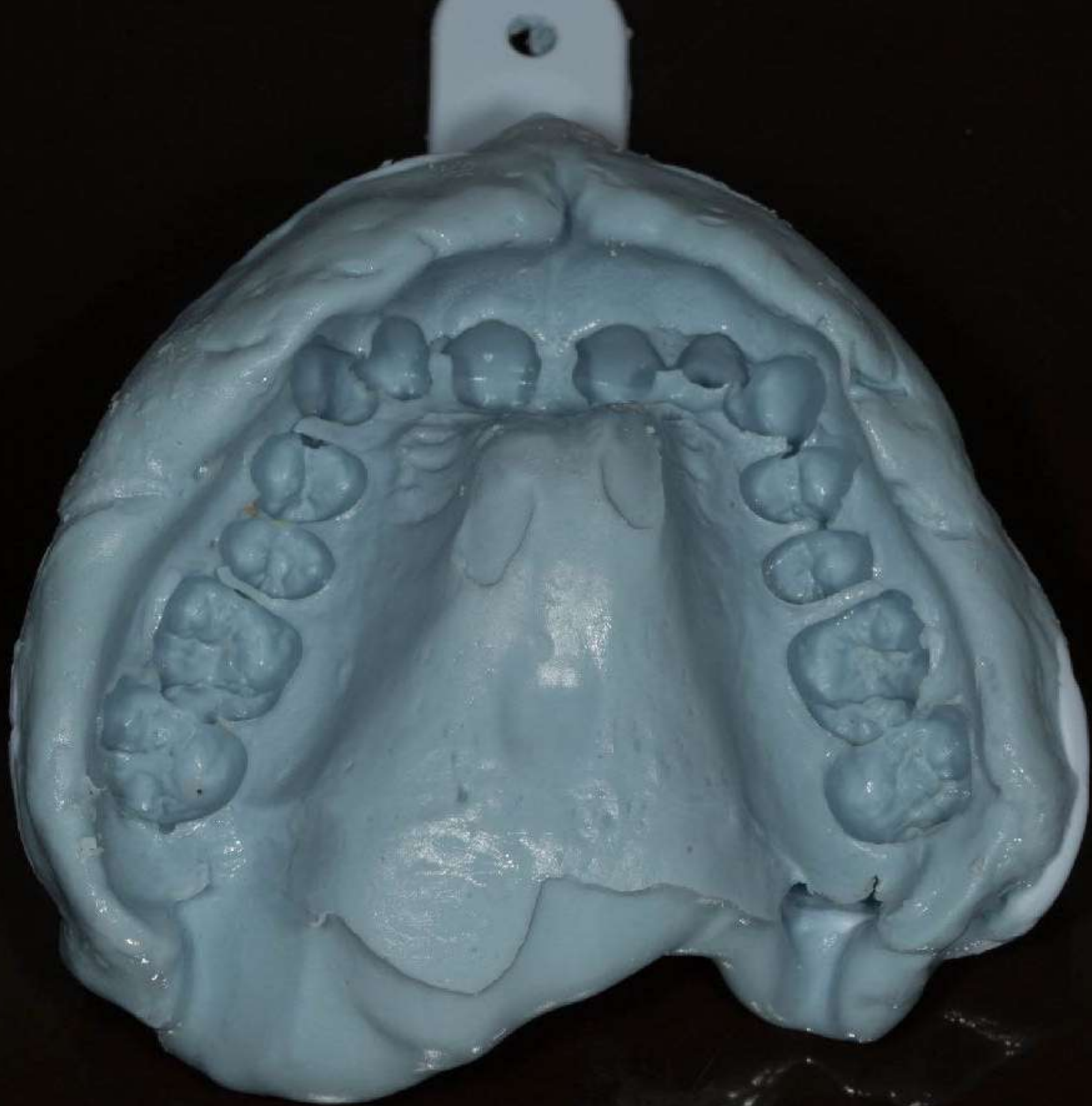+ MAKE SURE BOOKED IN WITH SYED REGARDING REMAINING TEETH

Visit	Treatment and result	Fee (£)	Time required (Hours)	Appointment		Time Gap	Laboratory to produce	Lab and implant parts fee (£)
				Date	Time			
1.	Impressions	450	1			2 weeks	Immediate acrylic based denture upper 2-2	750
2.	Immediate dentures - fit Extract UL12, UR12 Adjust lower 2-2 to create more space in the bite	1125	2 ½			1 week		0
3.	RV 1 Impression for whitening trays if wanted	450	1			2 weeks	Whitening tray	0
4.	Review – x 6 over 12 months Do impression – for special tray and designing appropriate denture design May require new interim partial denture	2000	4			9 -12 months	Special tray Wax up of lower anterior teeth in an ideal arrangement – Mk 2 upper to be built to accommodate this and accommodate the adjusted lower anterior teeth	0
5.	Prepare mouth for upper denture Check impression	450	1			2 weeks	Check impression – check design	0
6.	Refine preparations Definitive impression	450	1			2 weeks	Try in in wax	0
7.	Teeth try in	250	½			2 weeks	CoCr framework	300
8.	Metal <u>framework</u> try in	450	1			2 weeks	Try in with teeth on	0
9.	Try in with teeth on frame	450	1			2 weeks	Finish	1500
10.	Fit	450	1			1 week		0
11.	Review and post op photos	450	1					0
12.	Contingency for additional denture reviews and remakes, relines etc...	450	1					0
Total		7425				52 weeks		2550

£9,975


1. £5,985 2. £1,995 3. £1,995

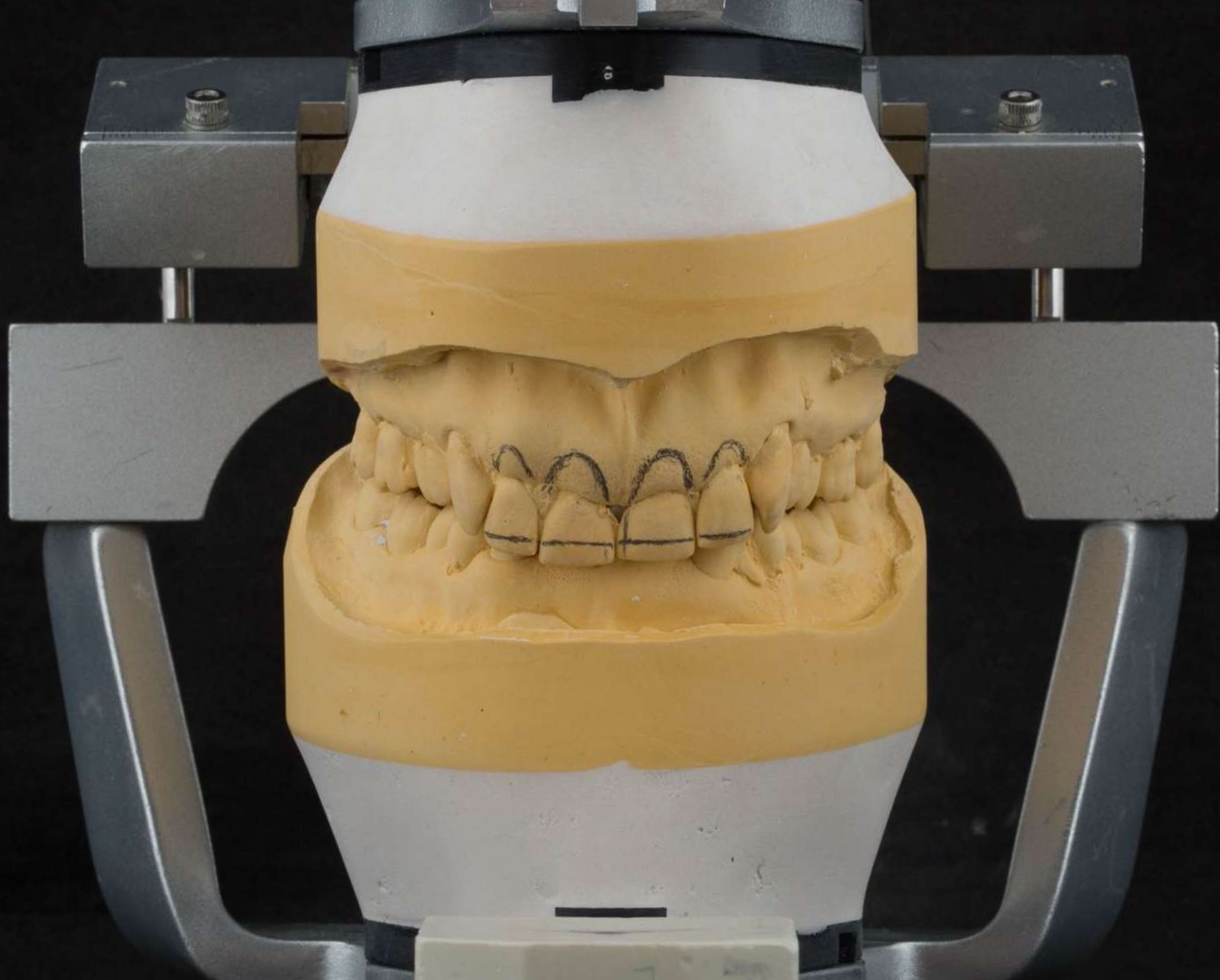


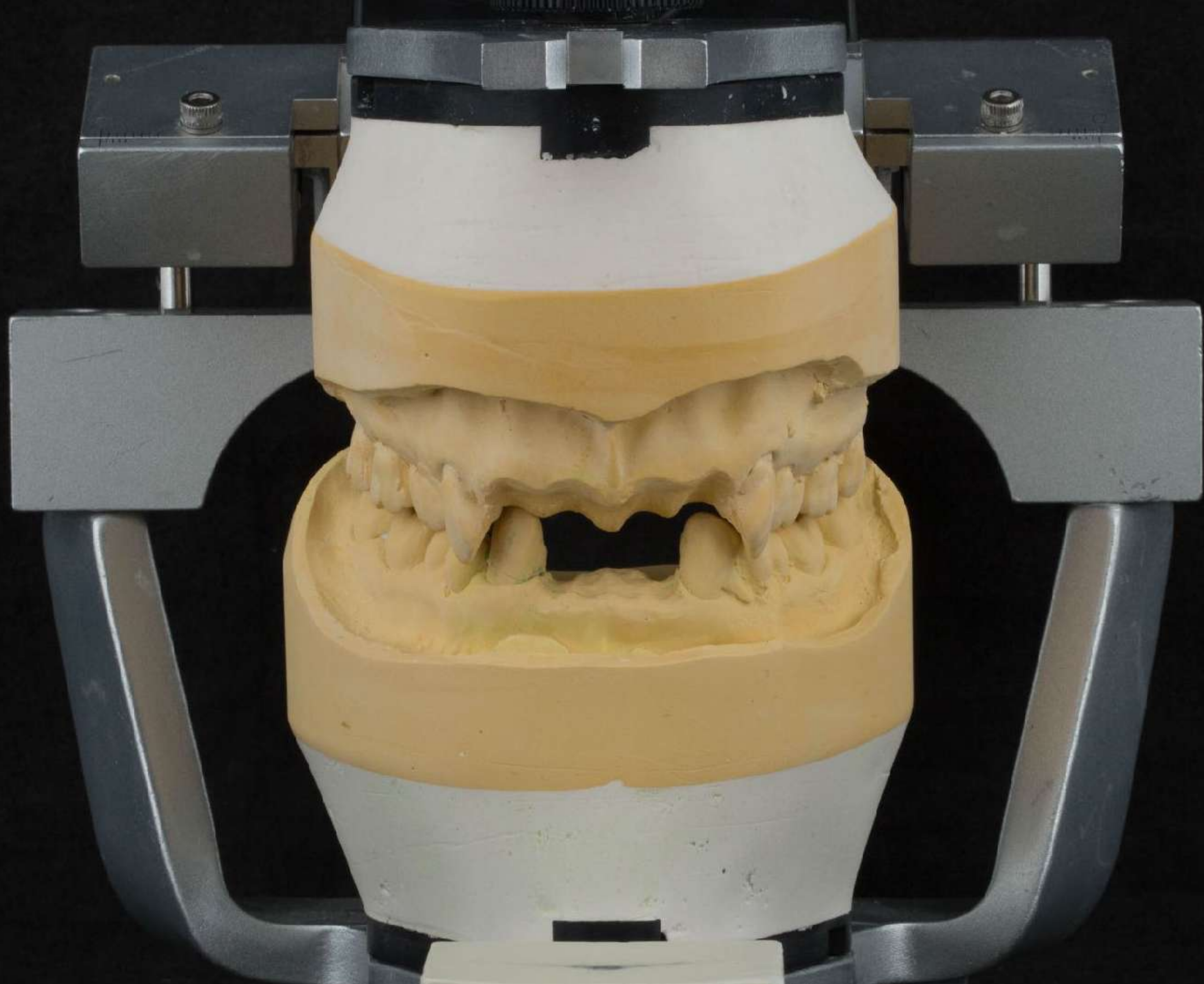


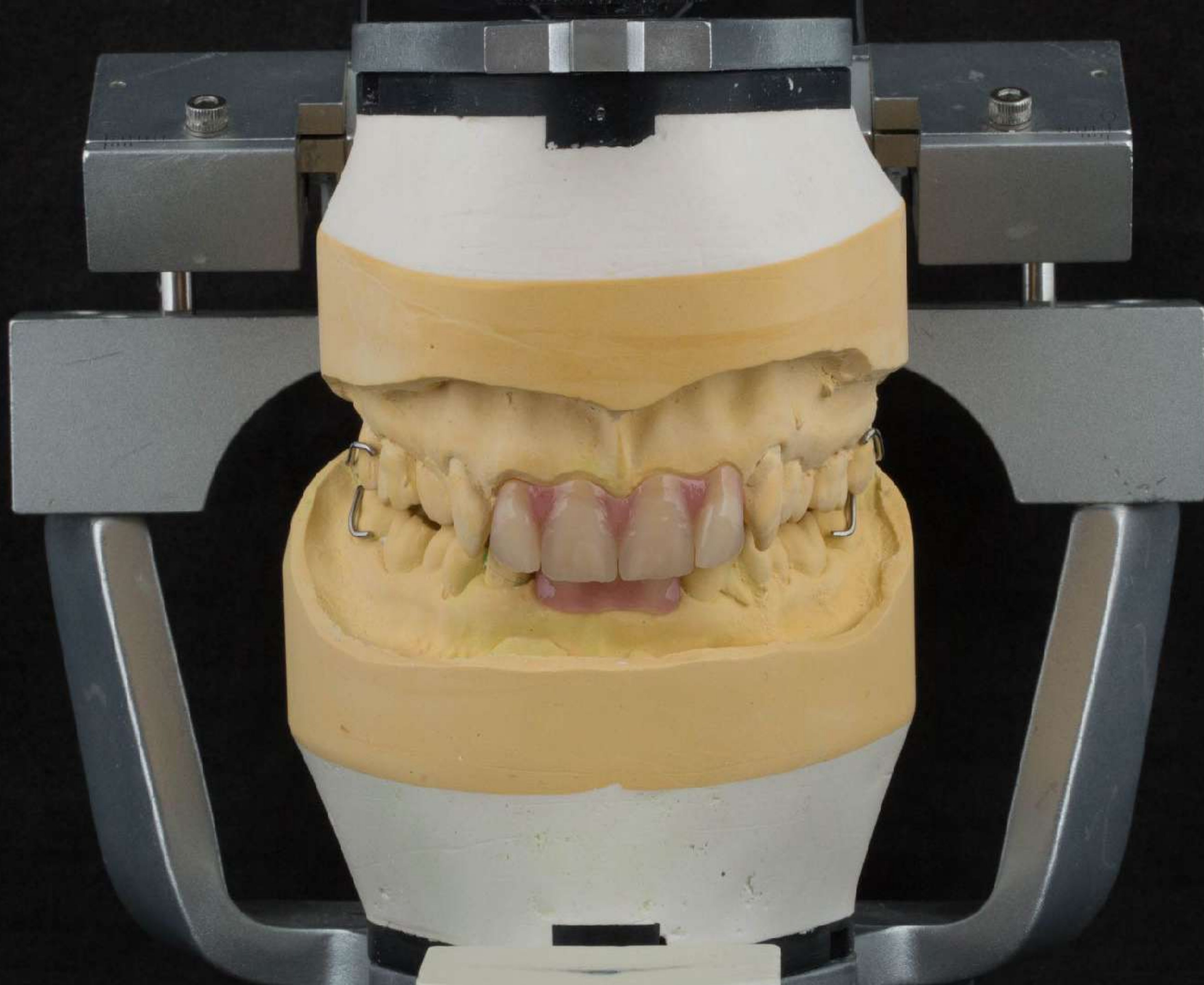
Primary impressions

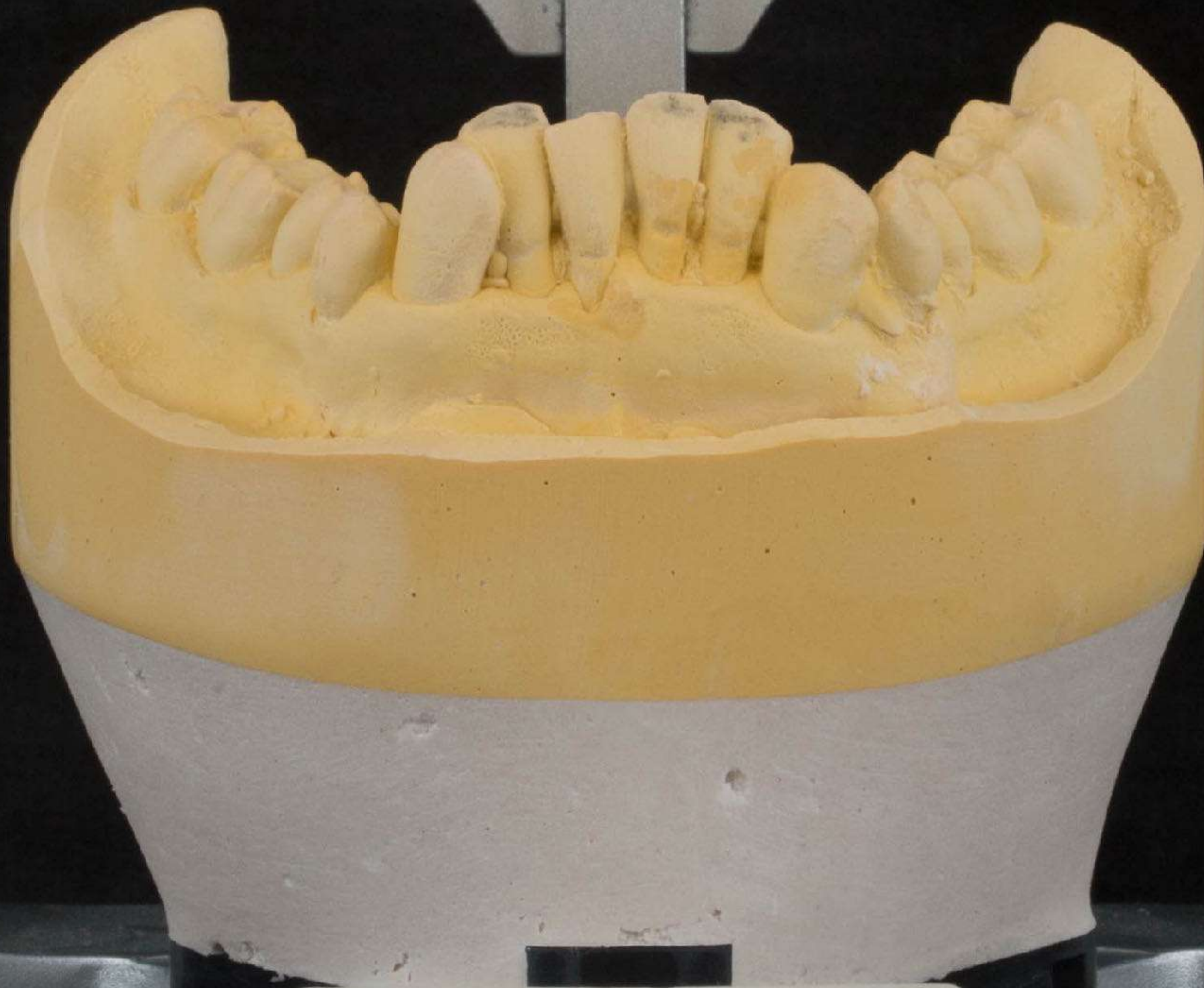Aesthetic improvement

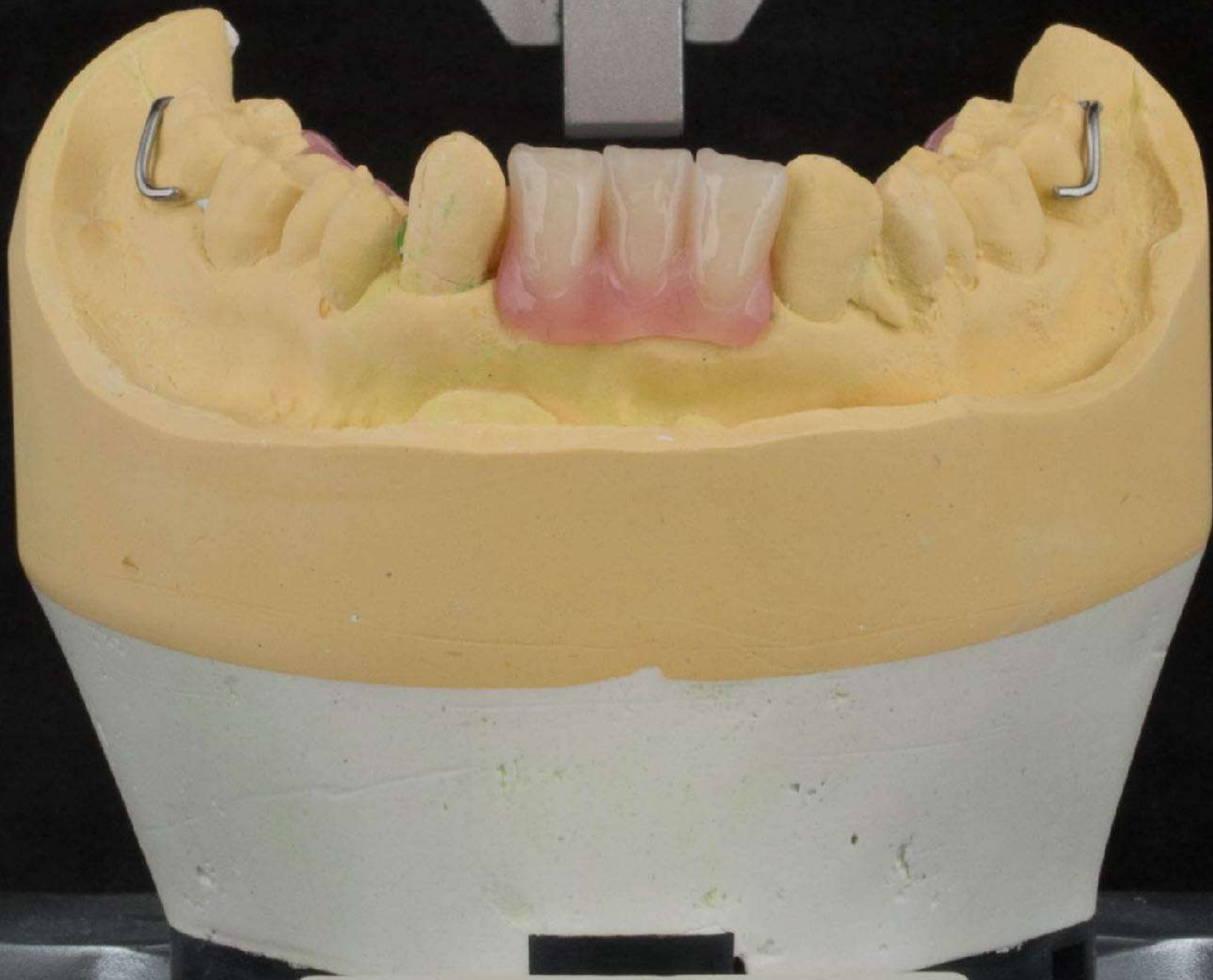


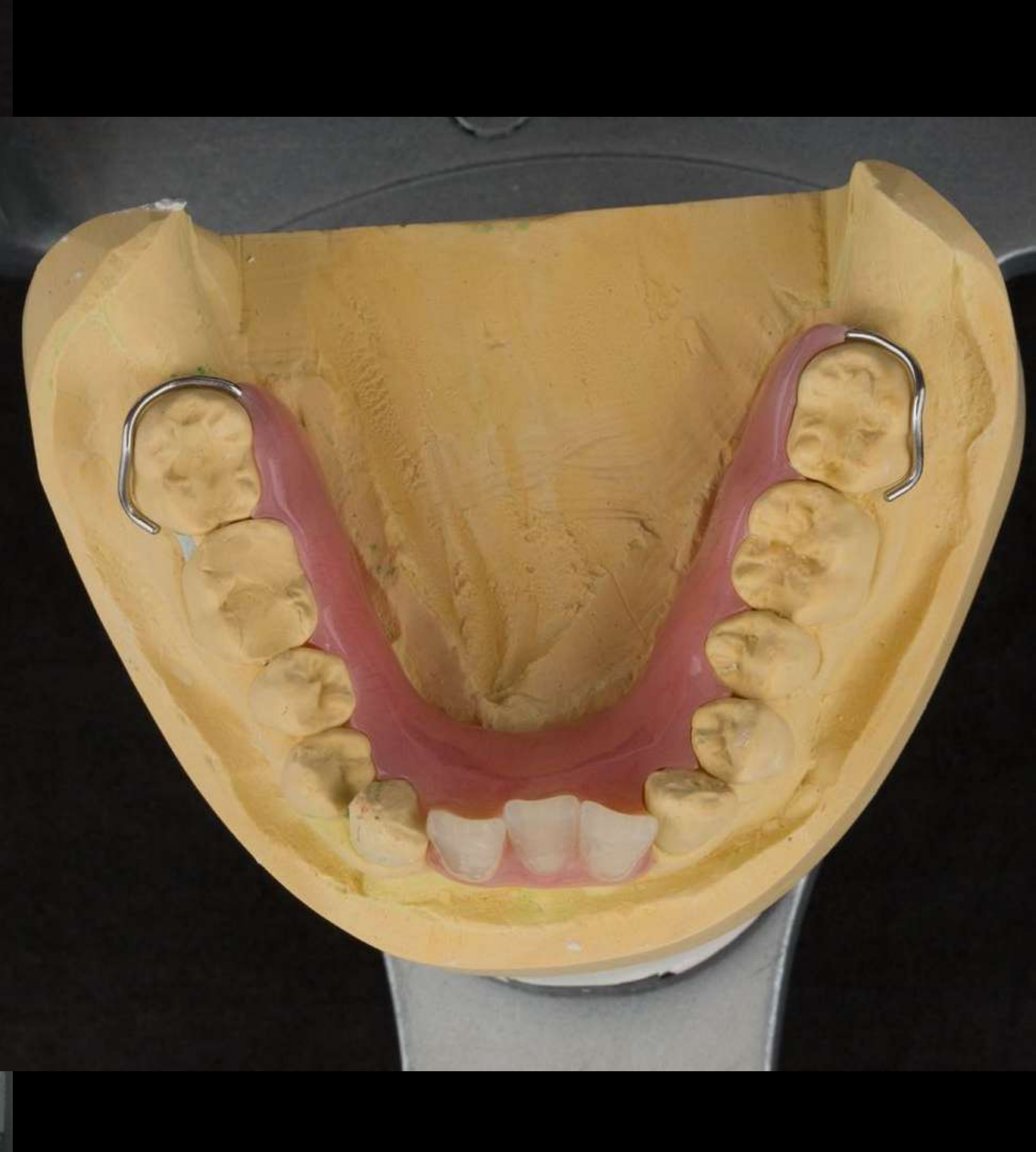
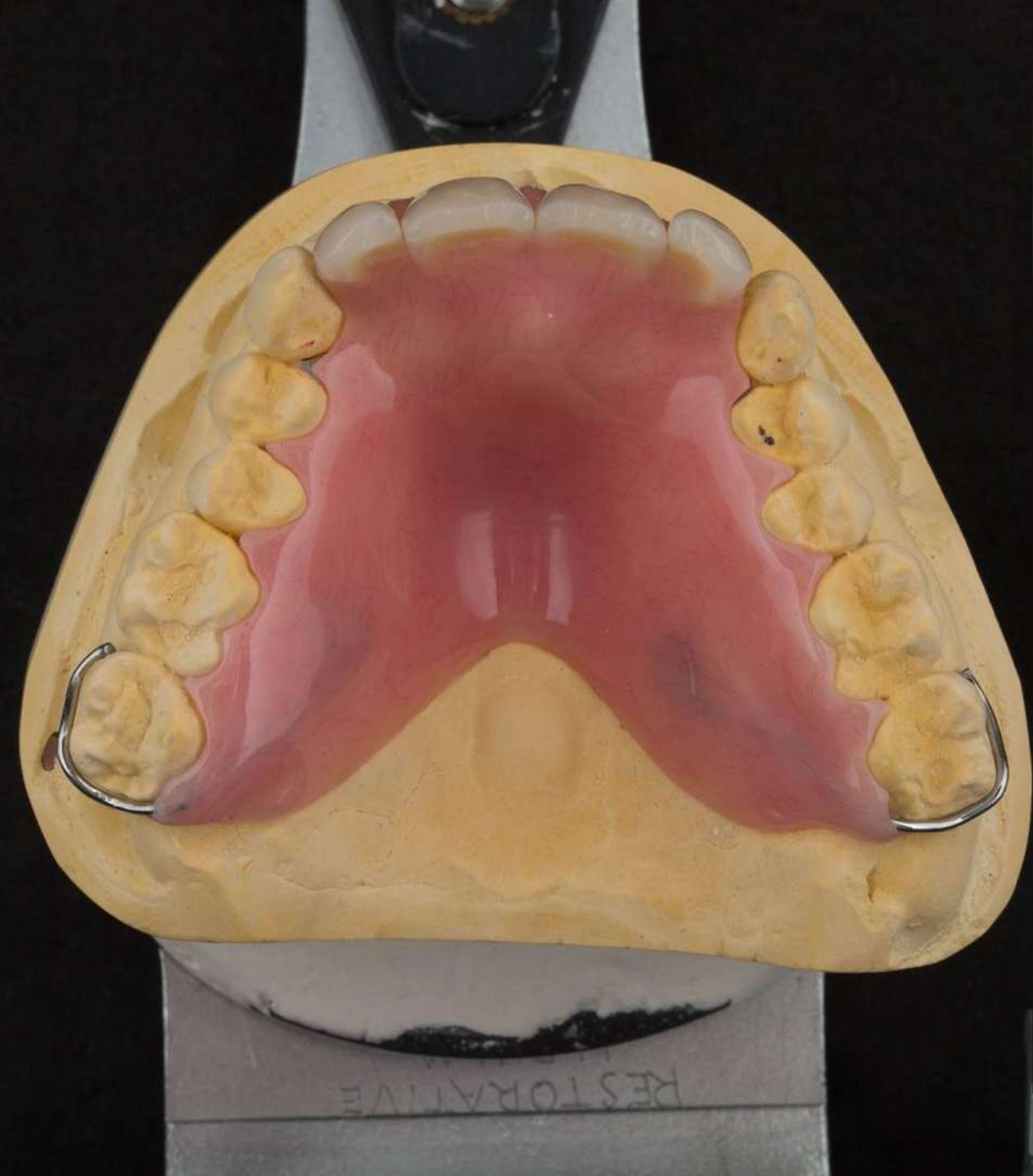


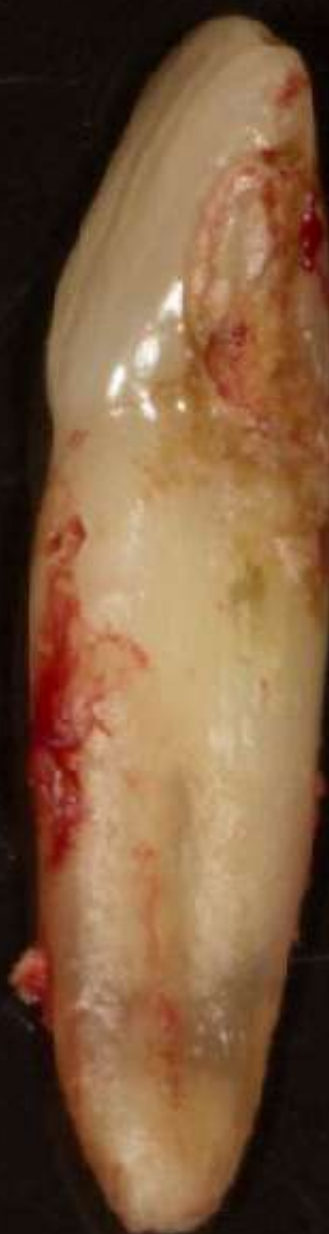
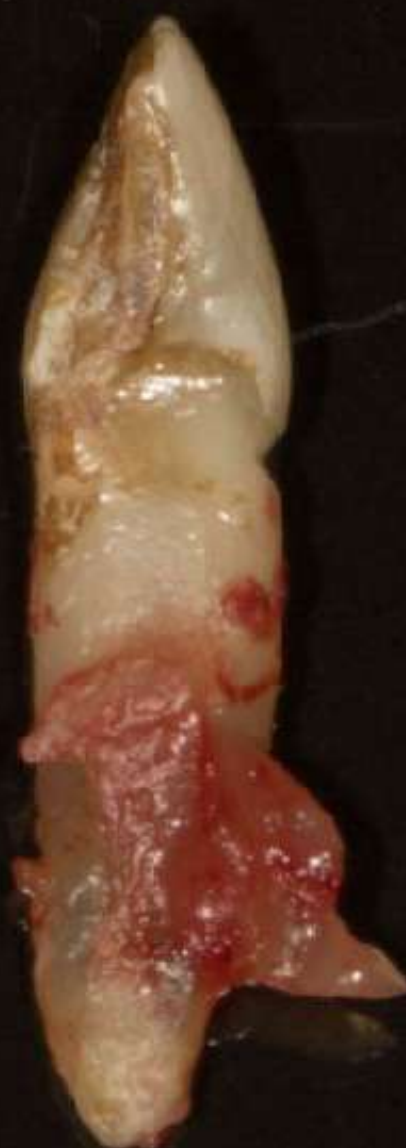
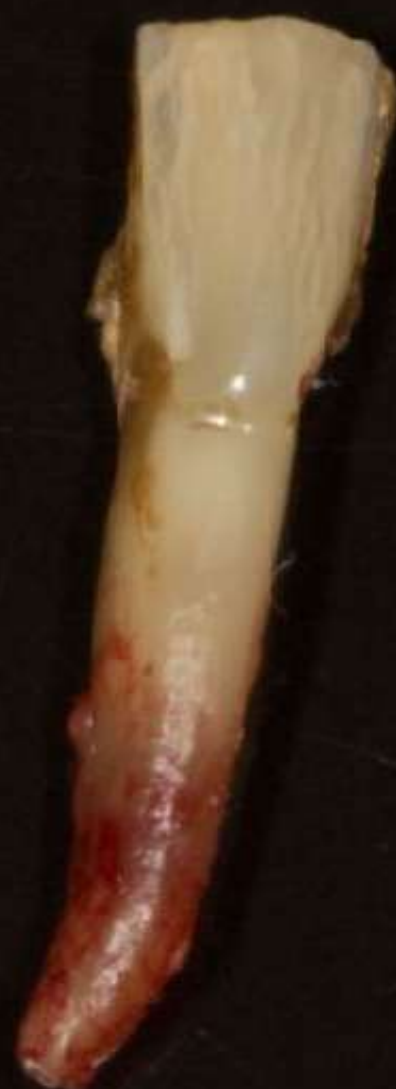
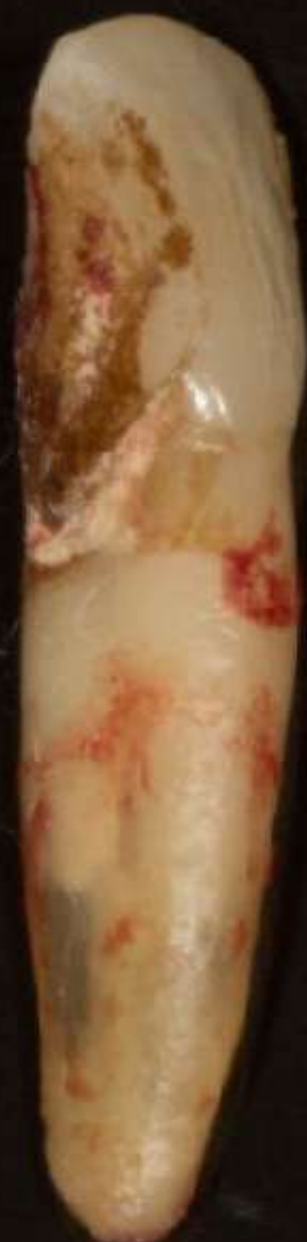
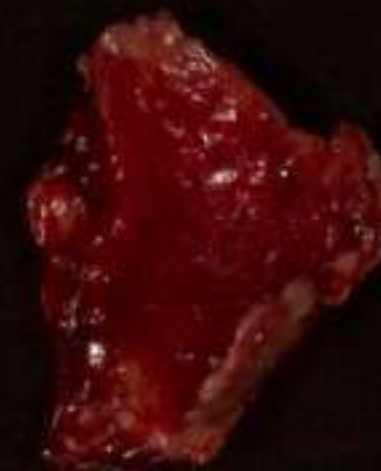
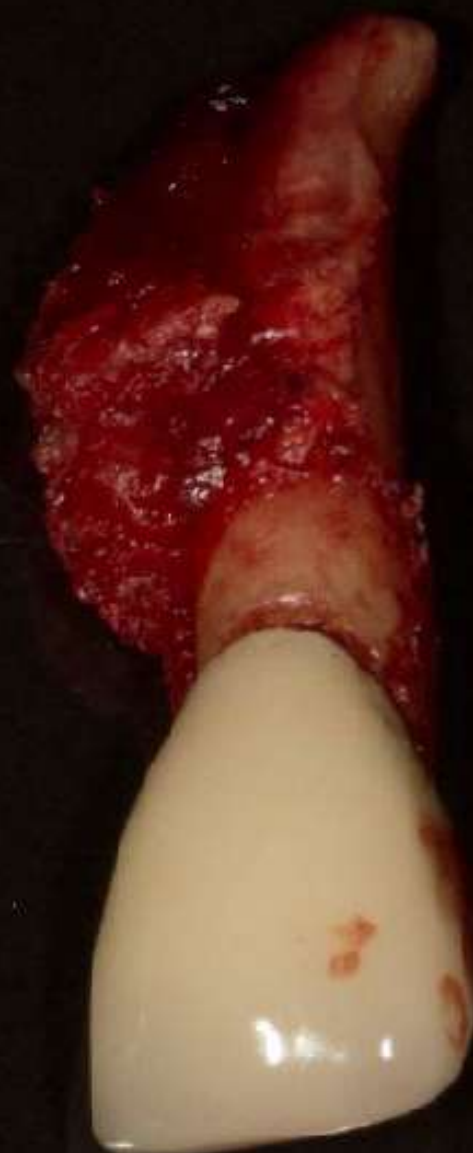
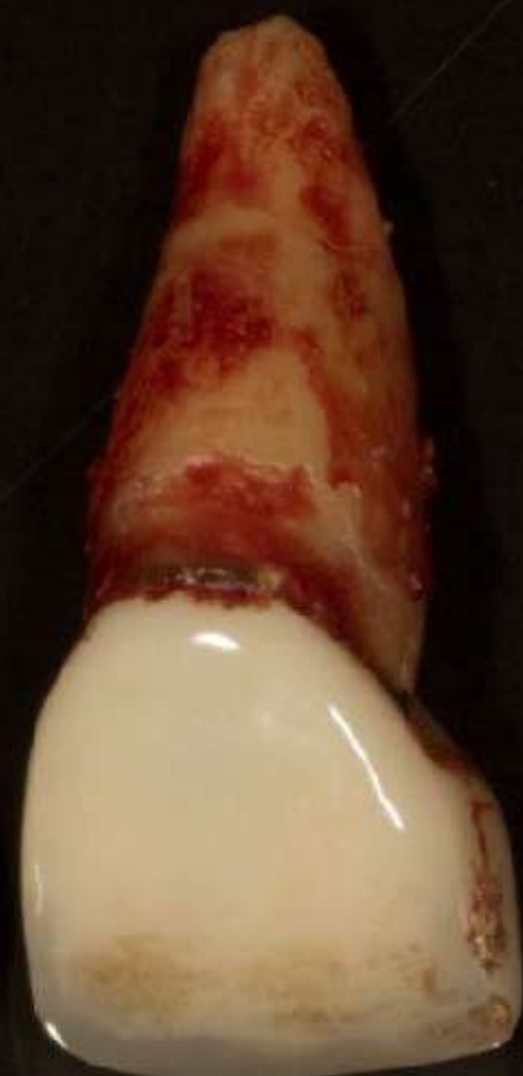
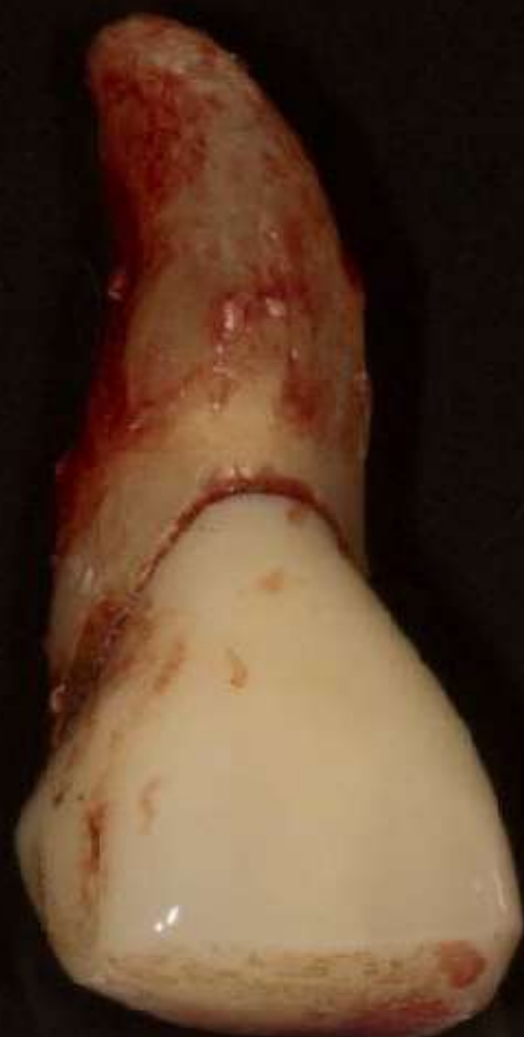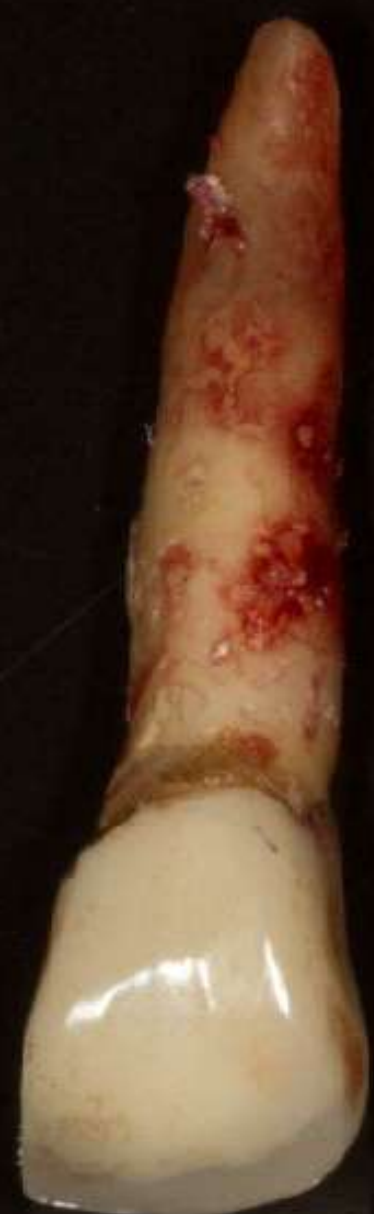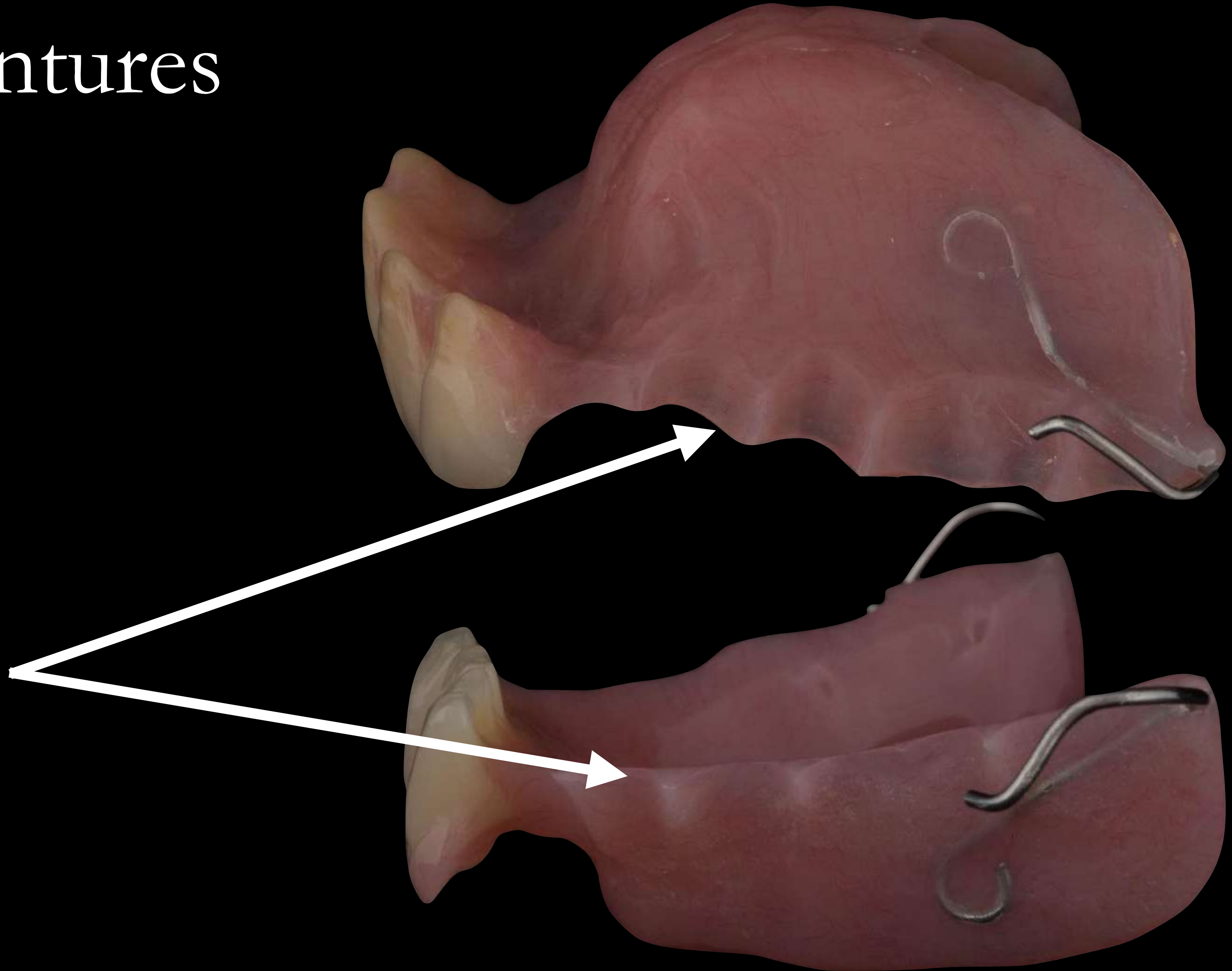


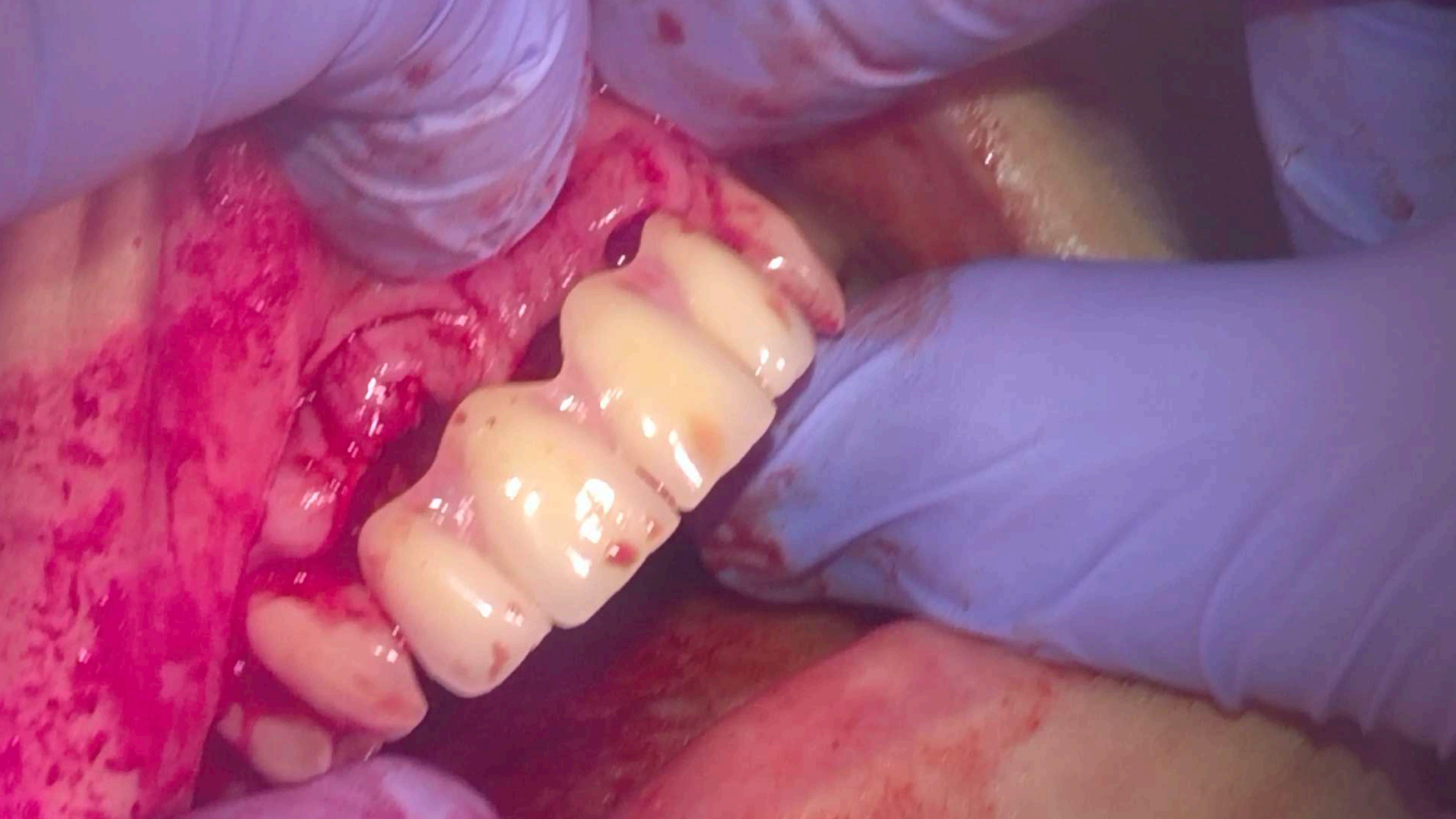
Adjusting dentures

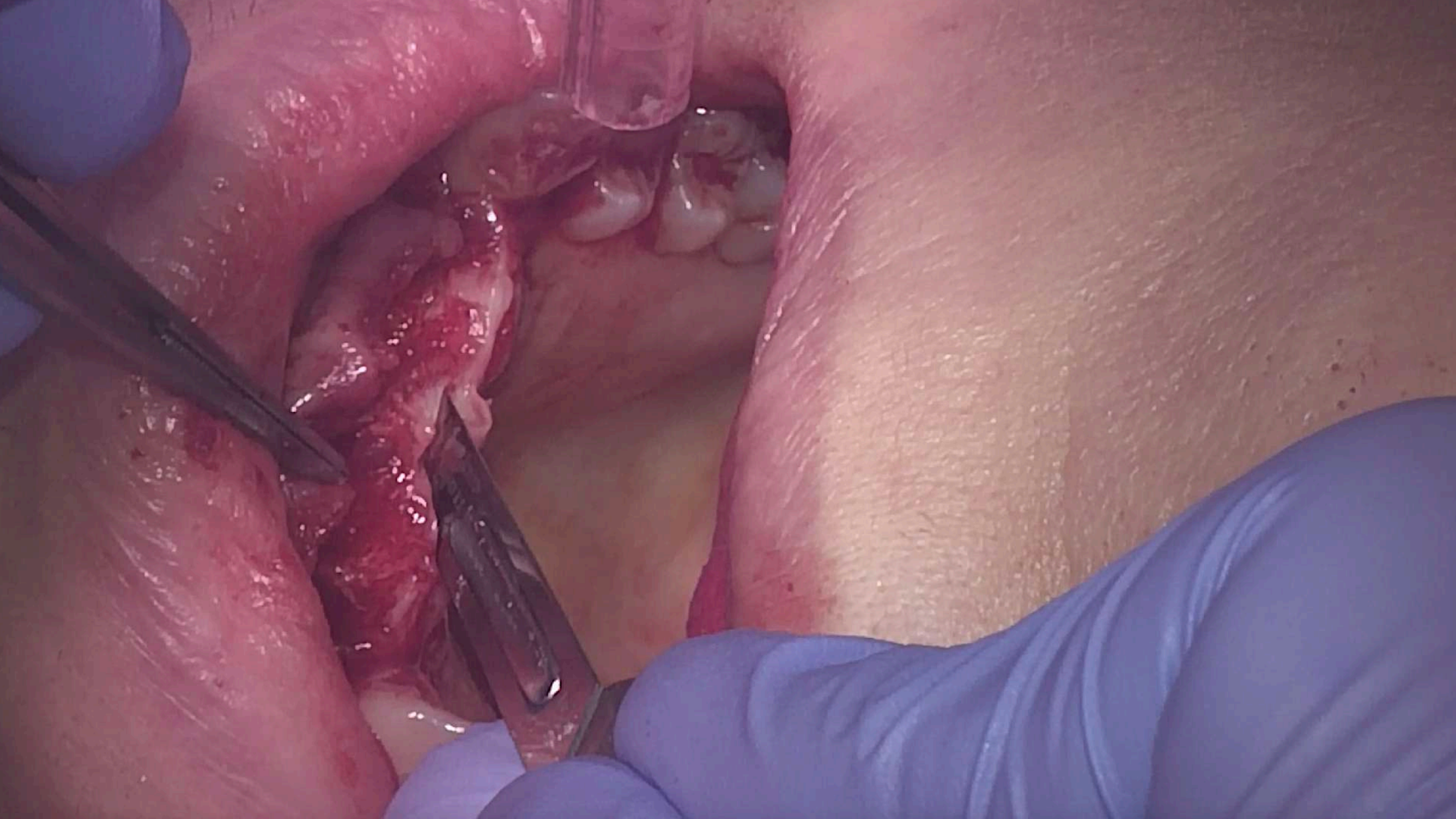
Soft tissue

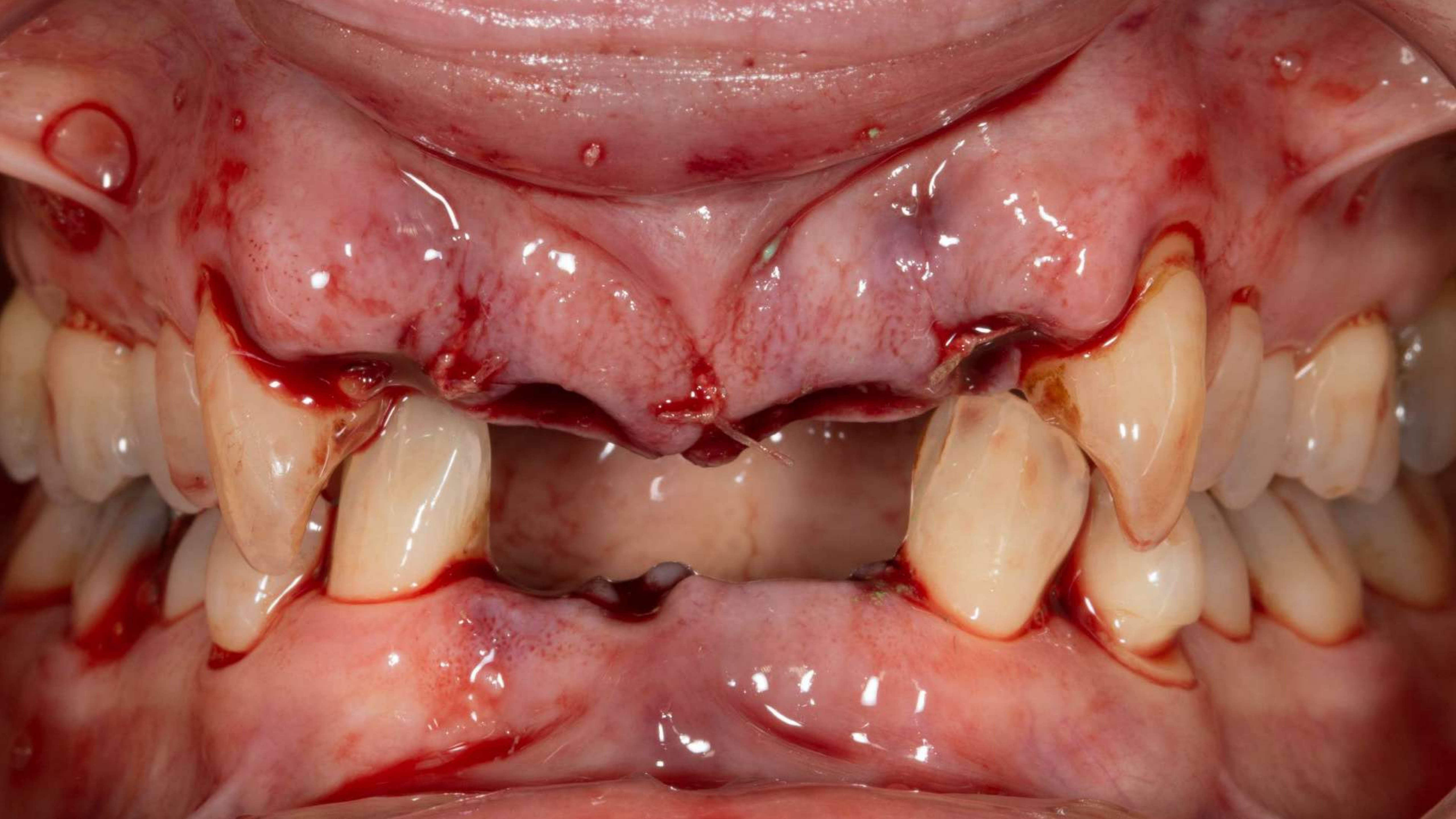
Hard tissue

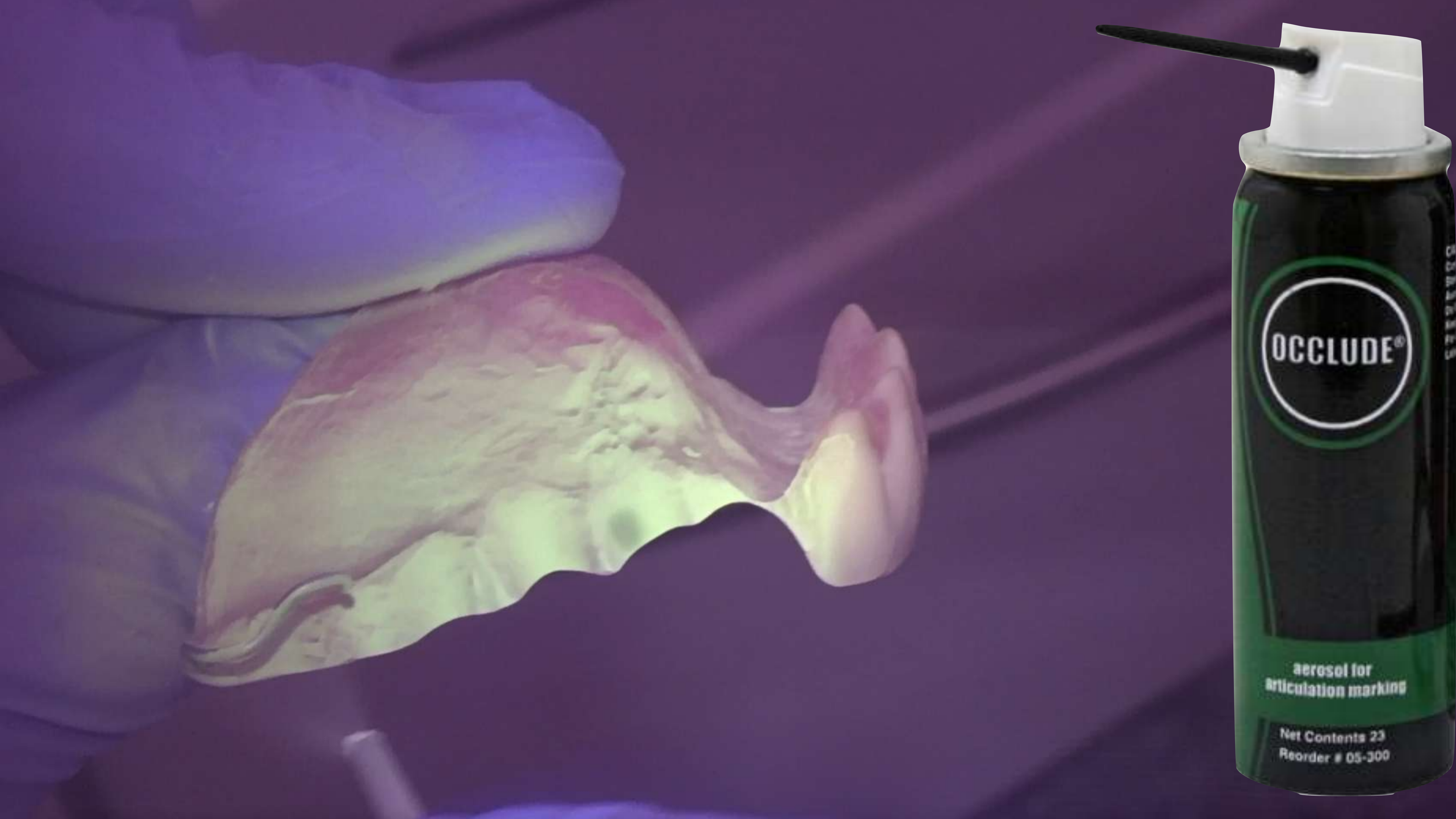
Never adjust here
- at the edge as
this will create a
gap







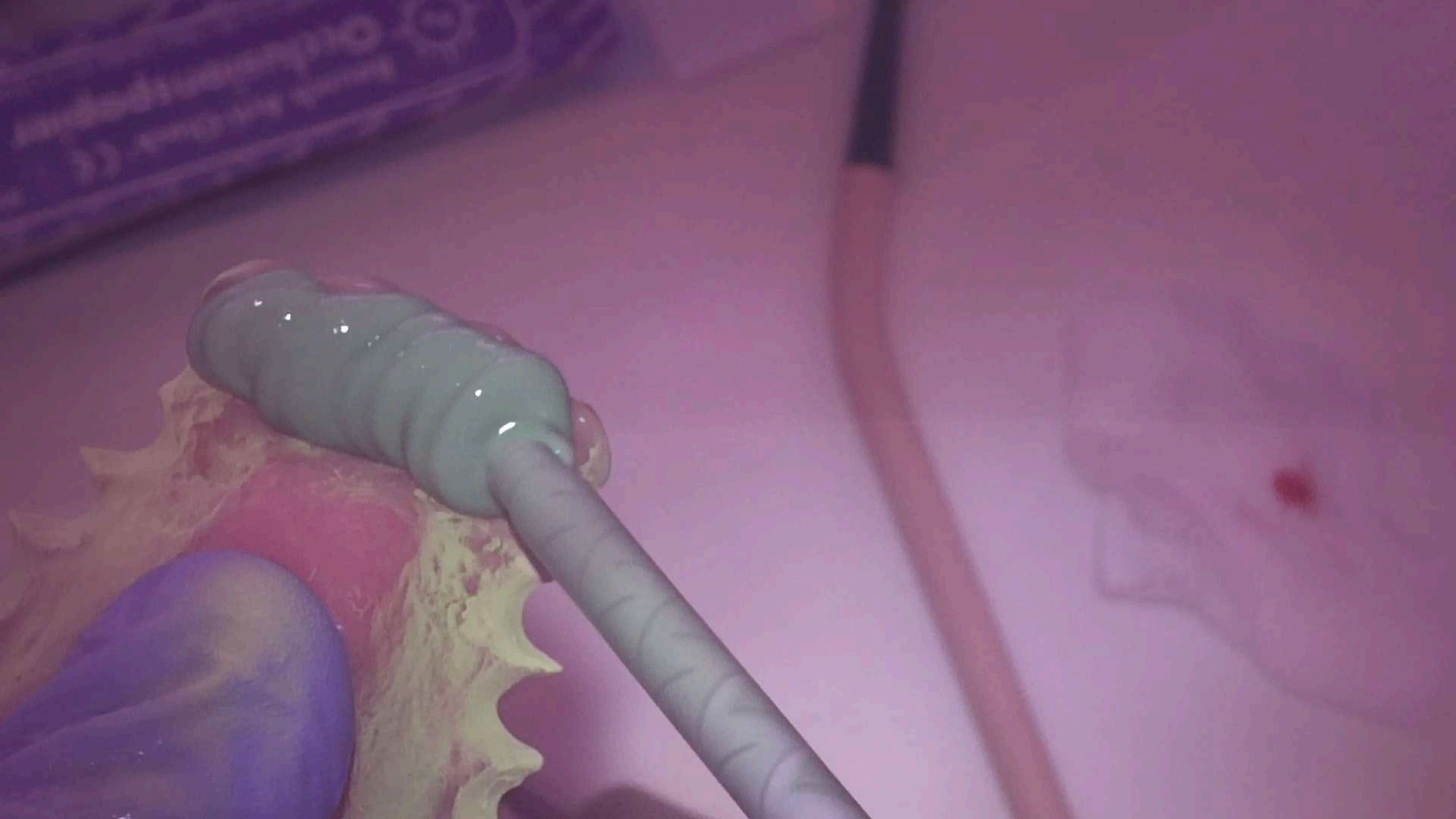

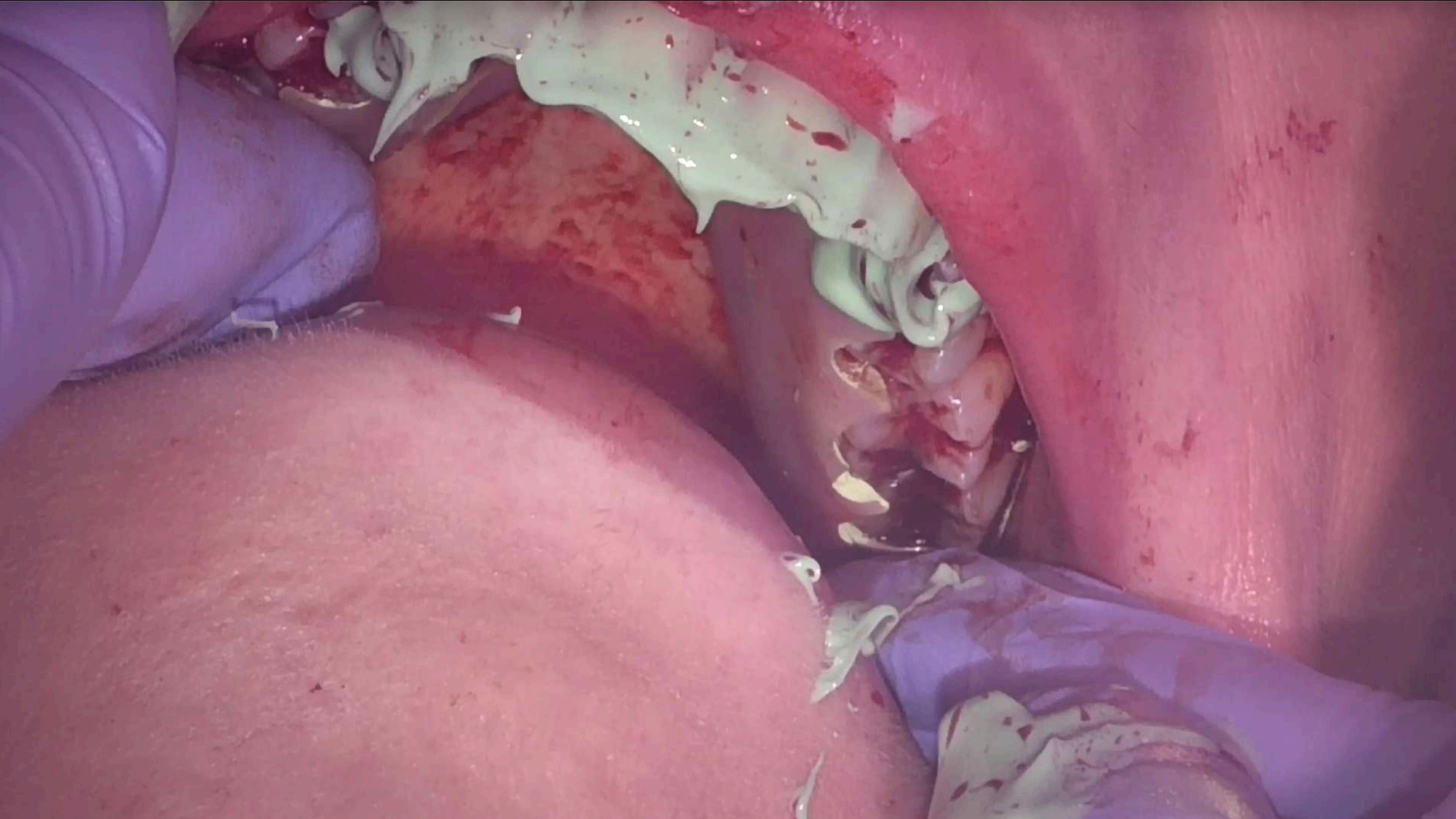



OCCLUDE®

aerosol for
articulation marking

Net Contents 23
Reorder # 05-300

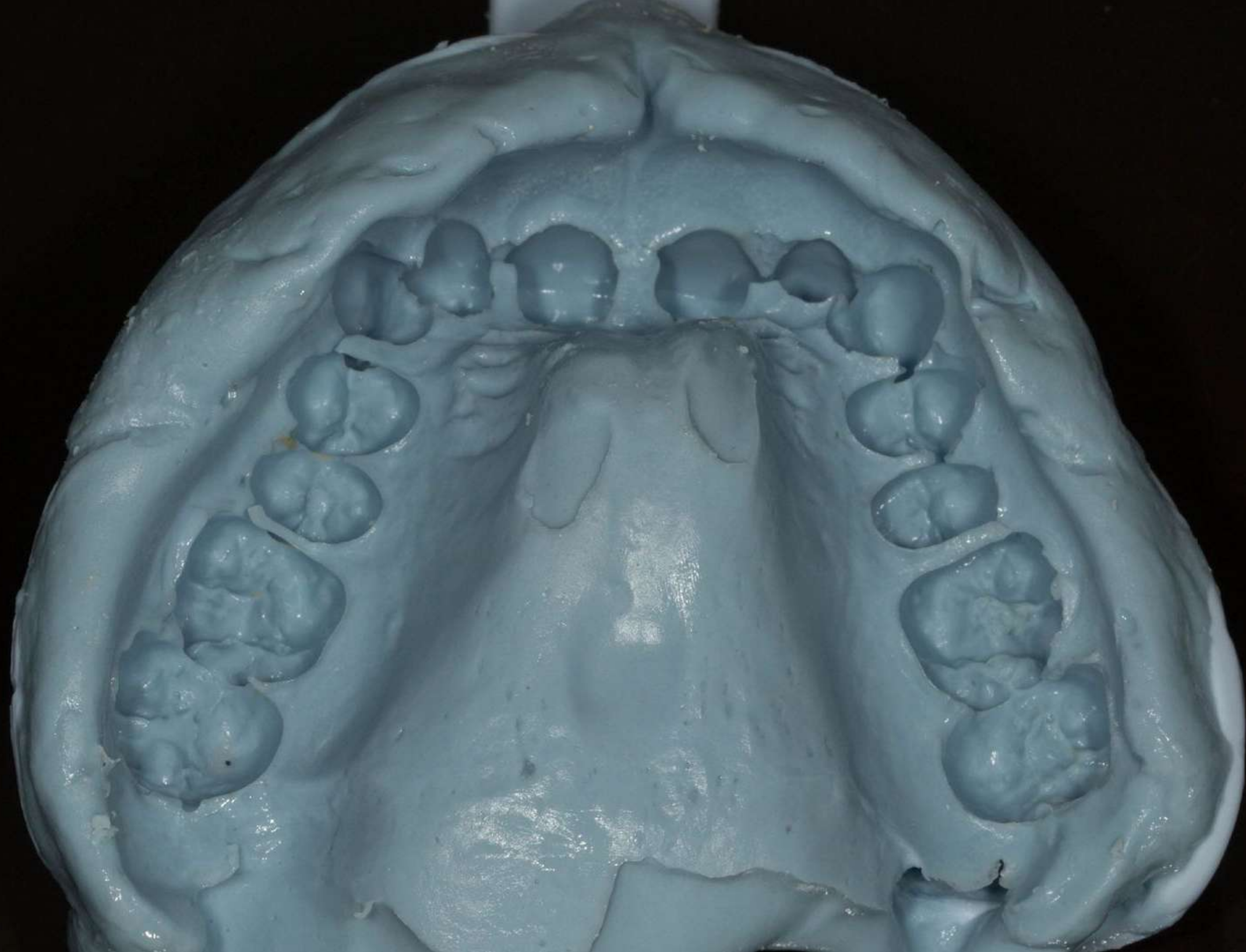

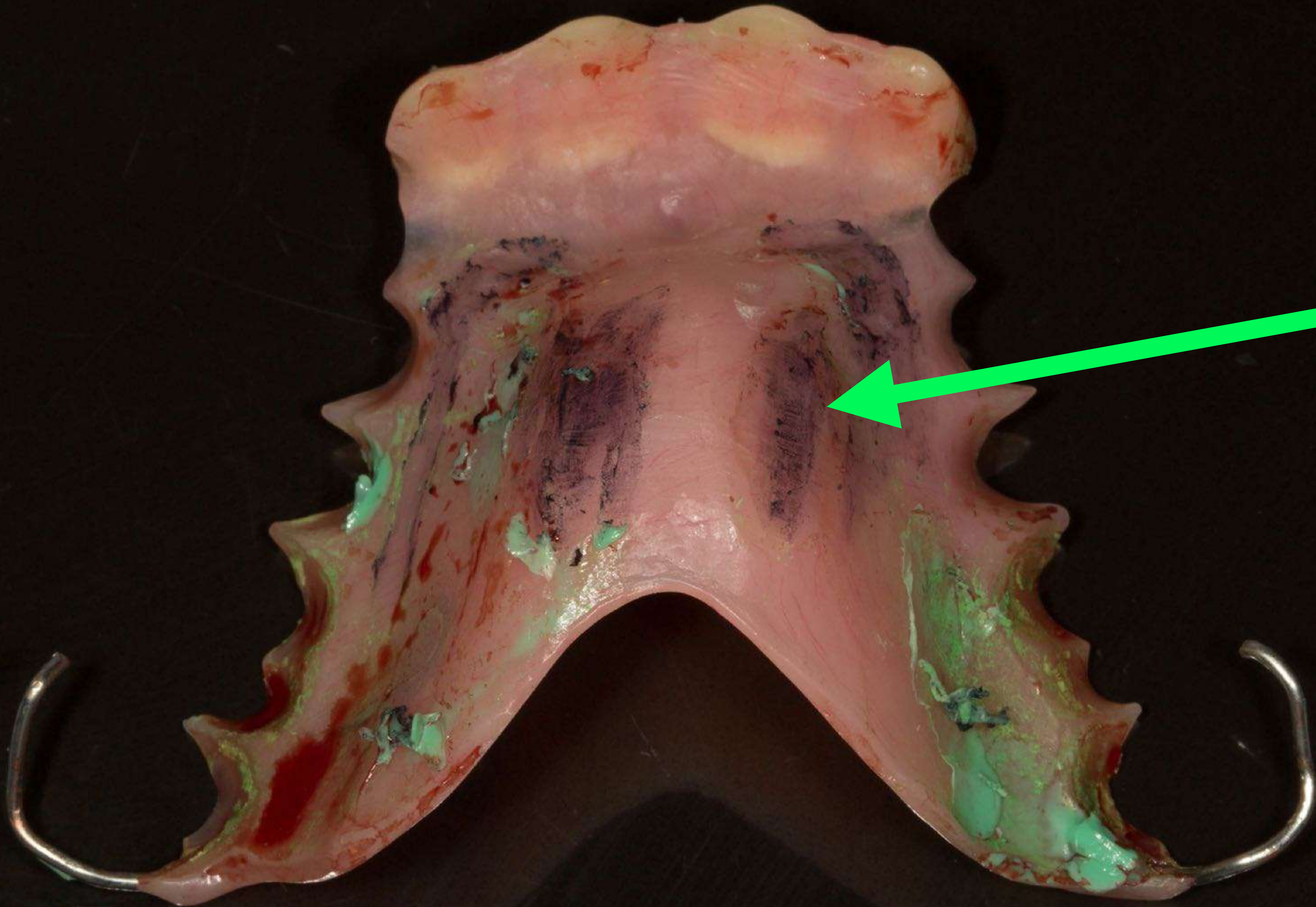


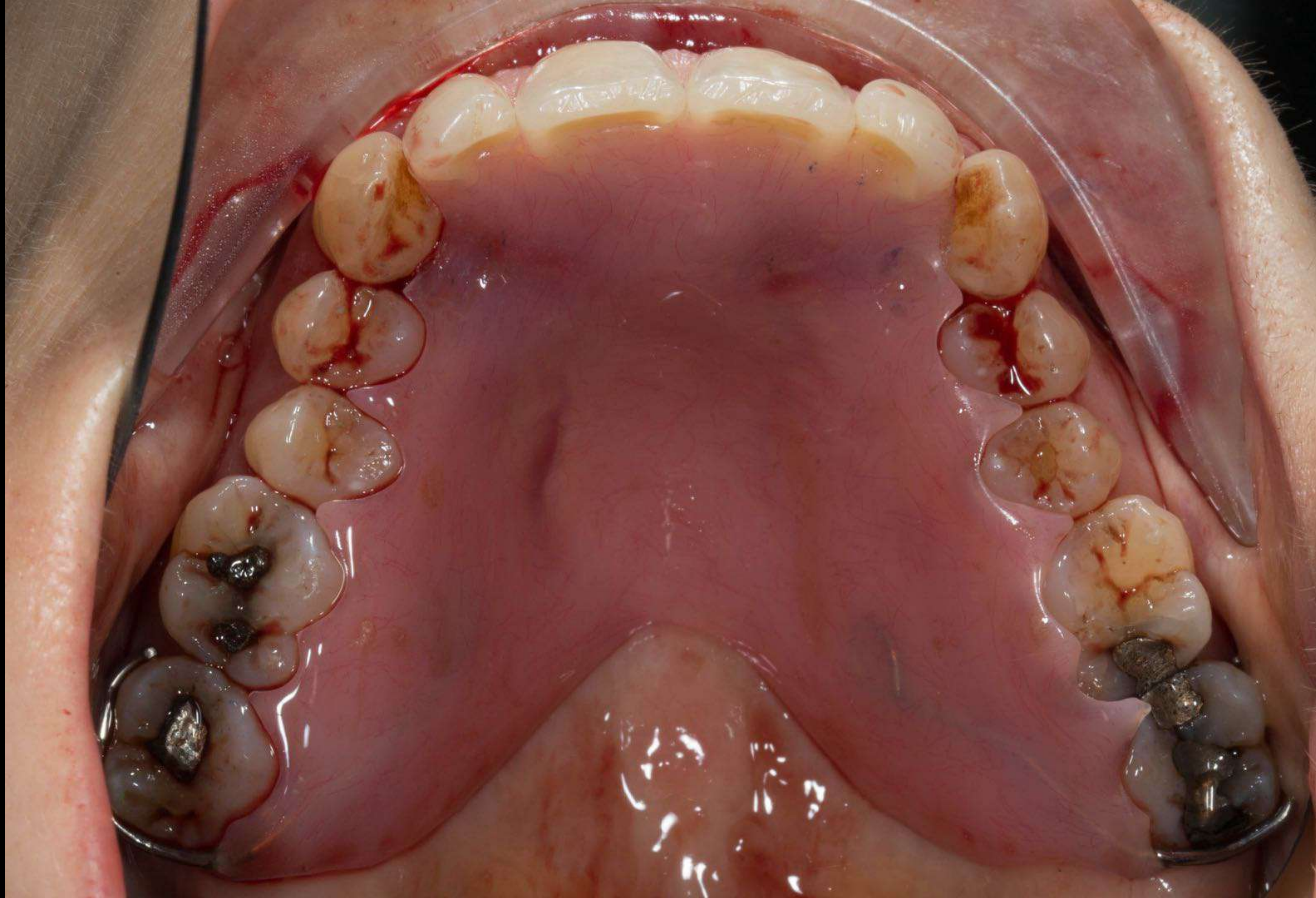


Light
bodied
silicone

Chinagraph
pencil

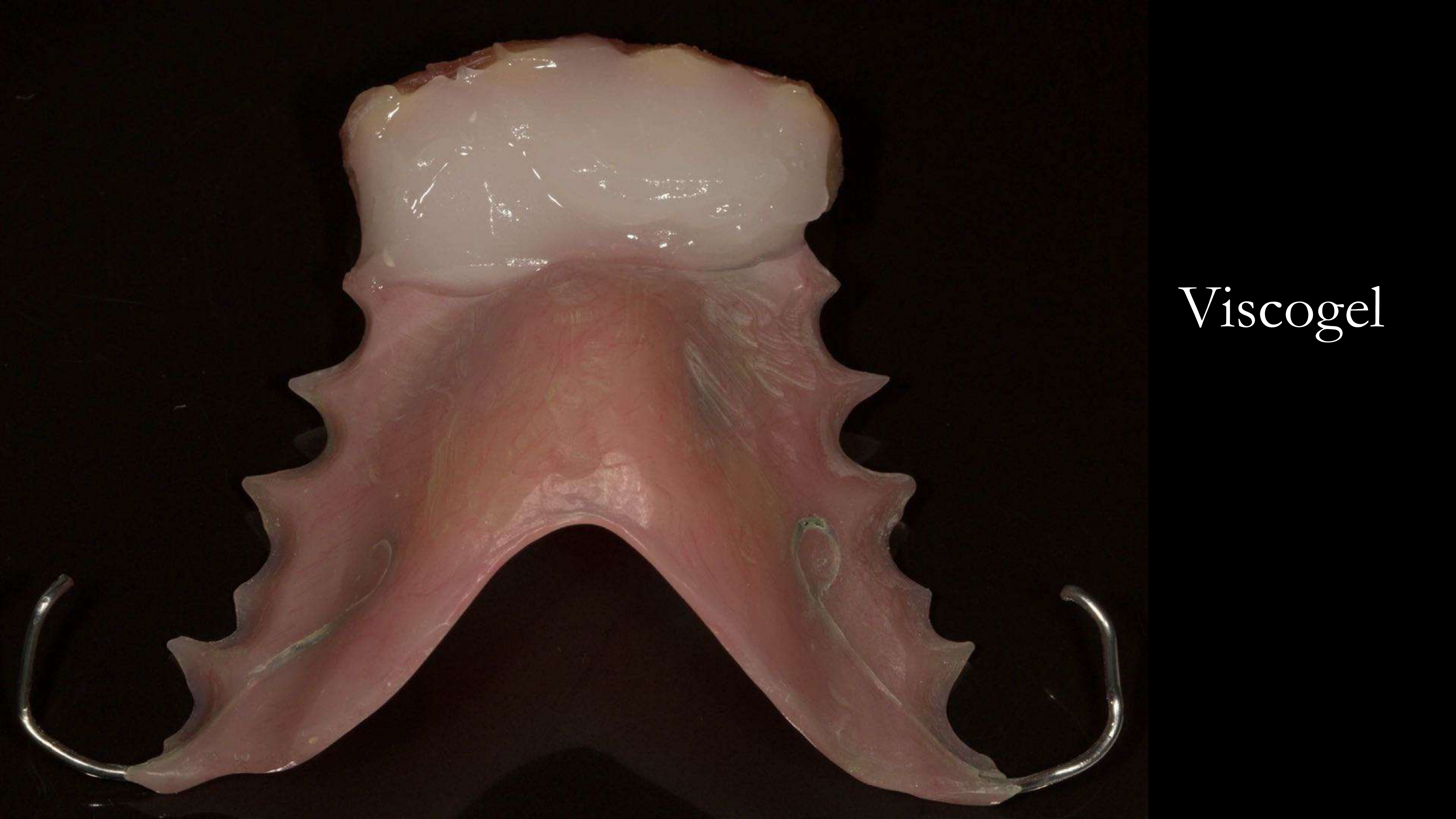




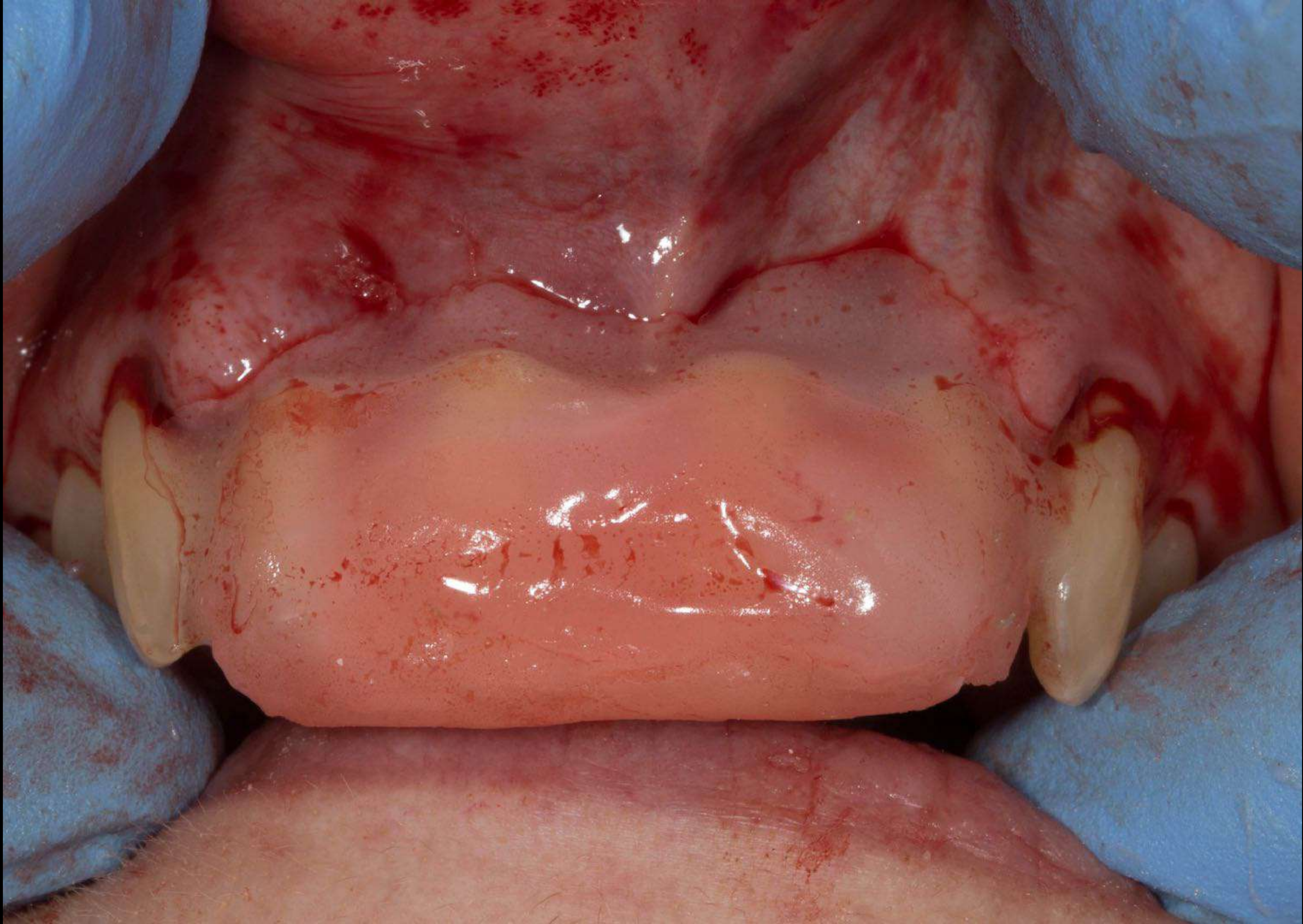


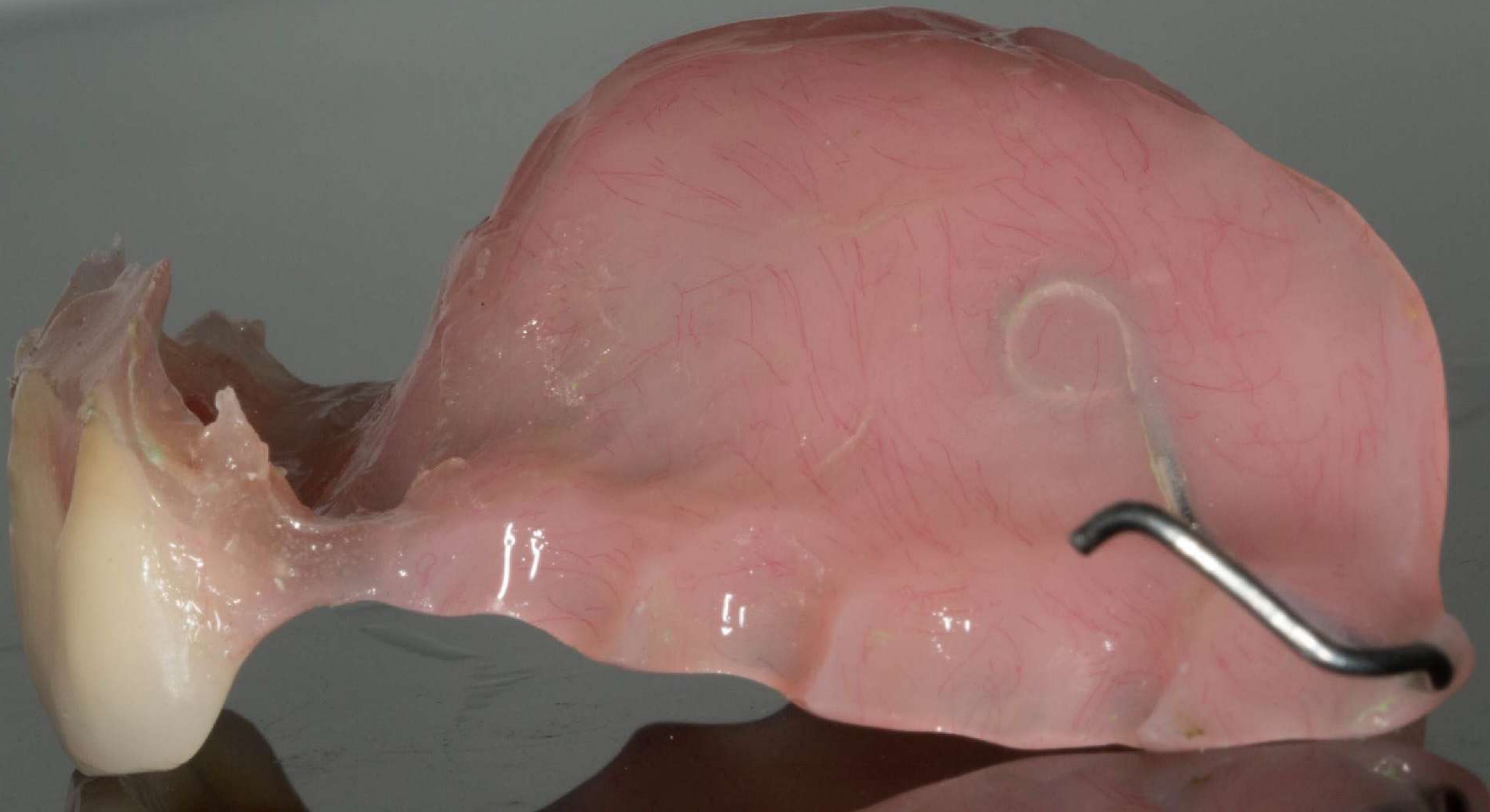Gap

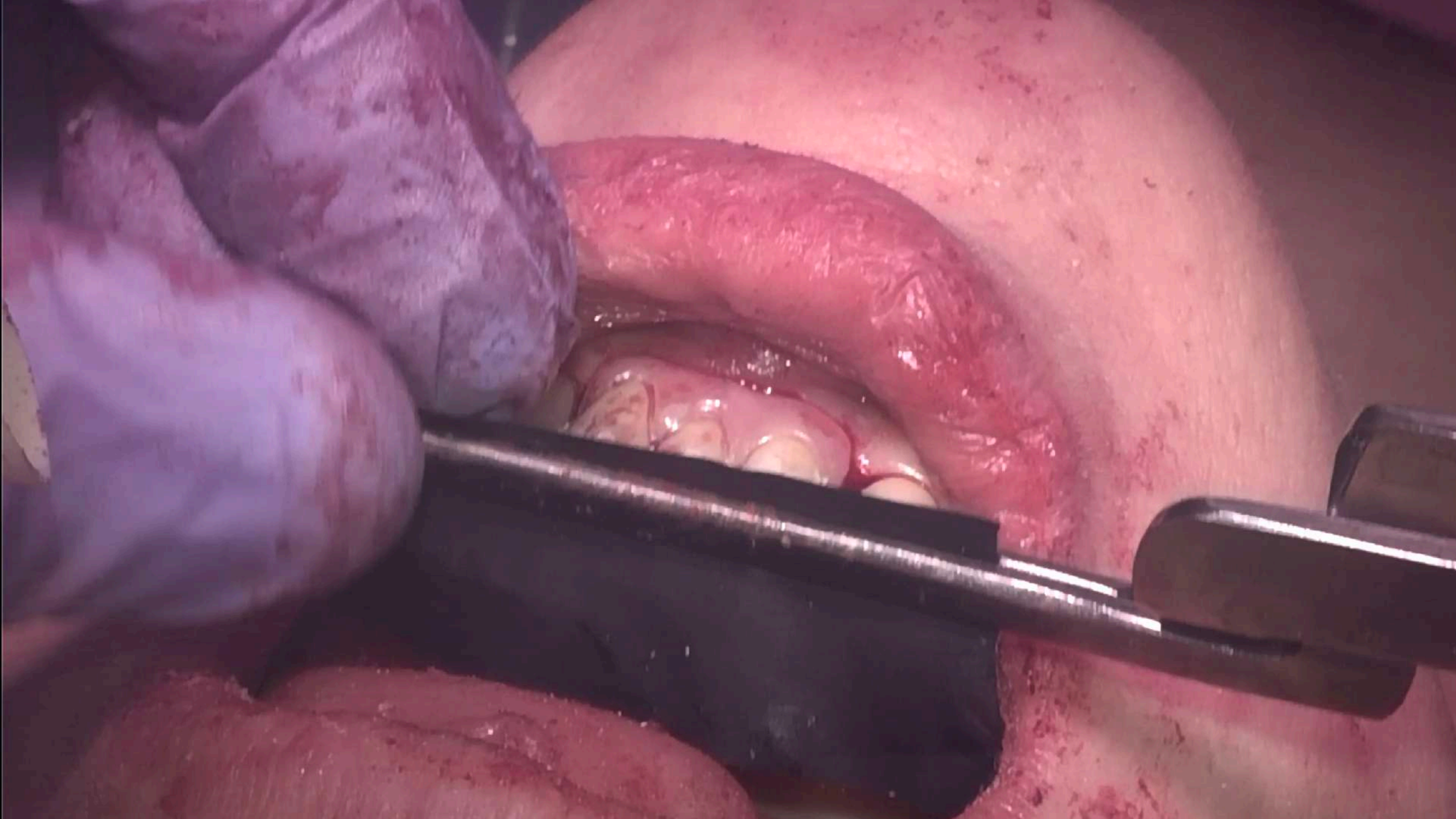


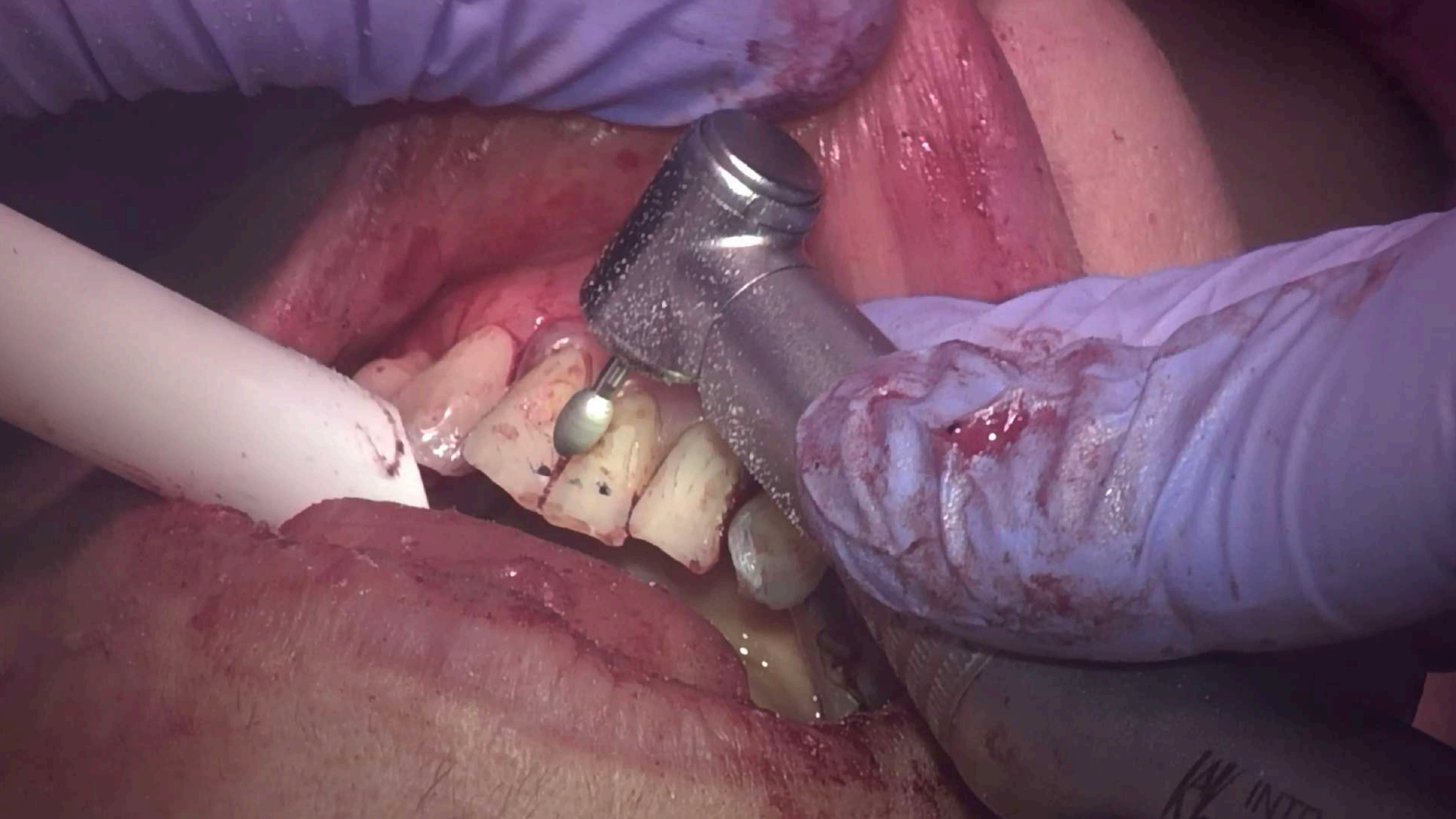


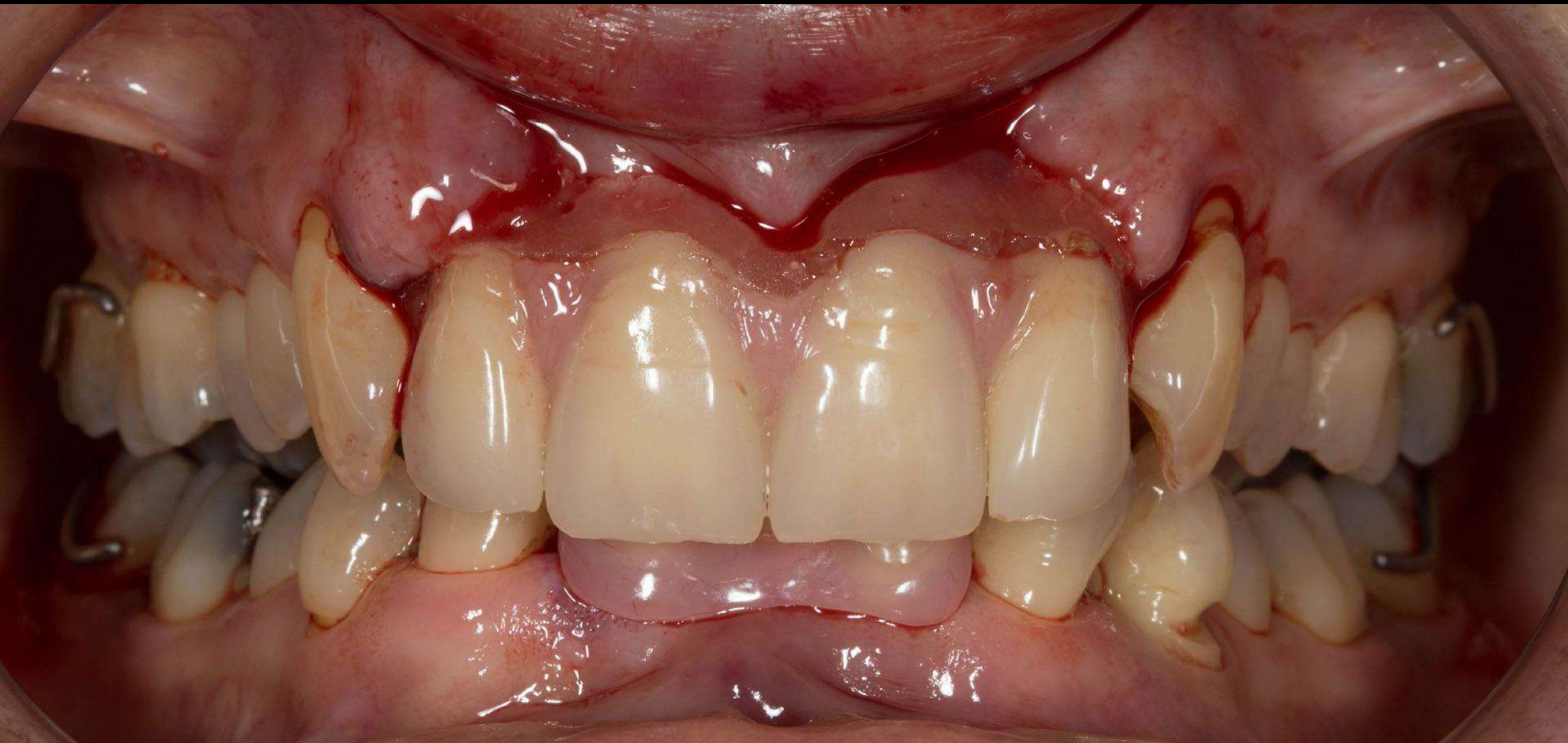Viscogel

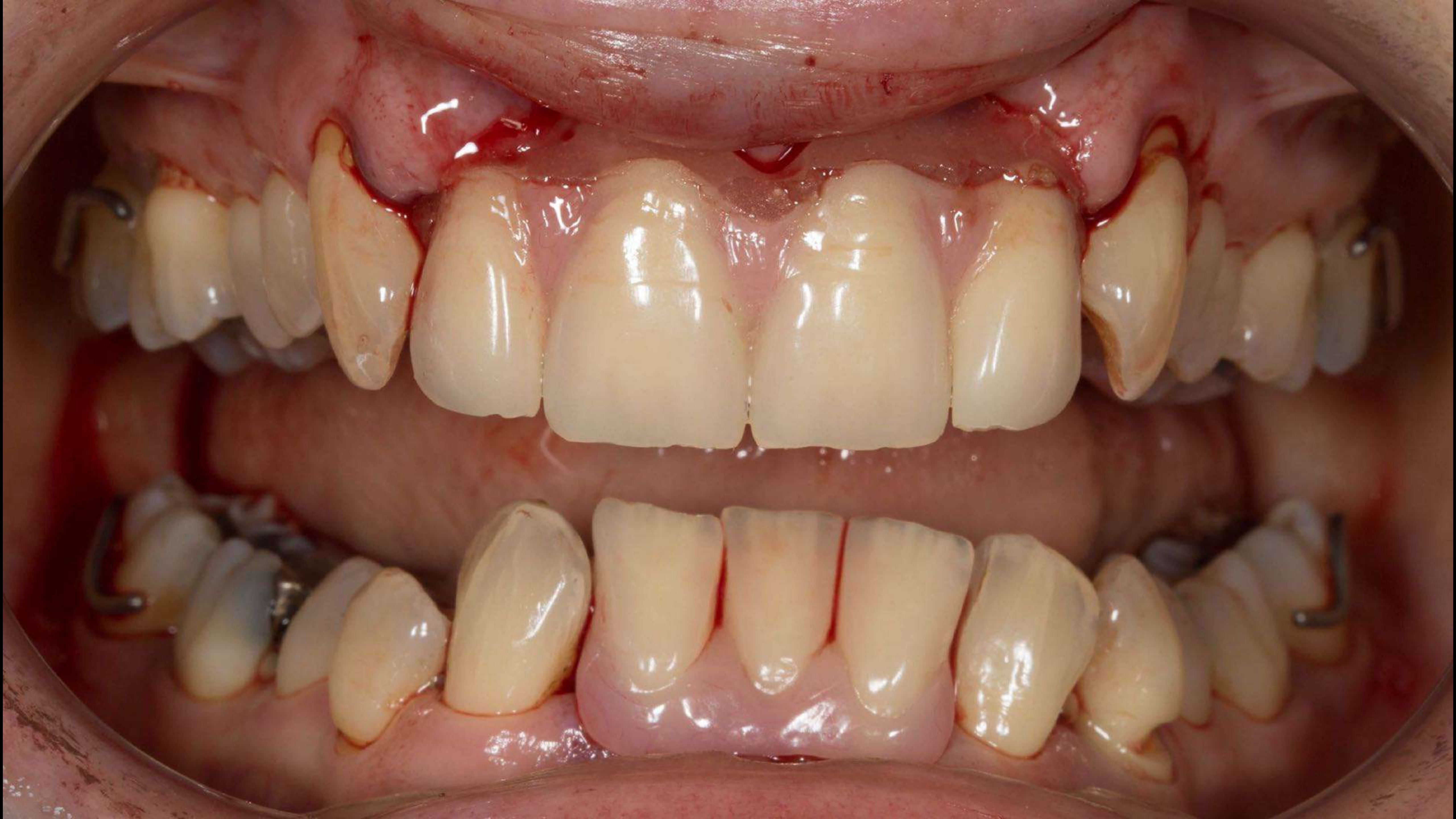






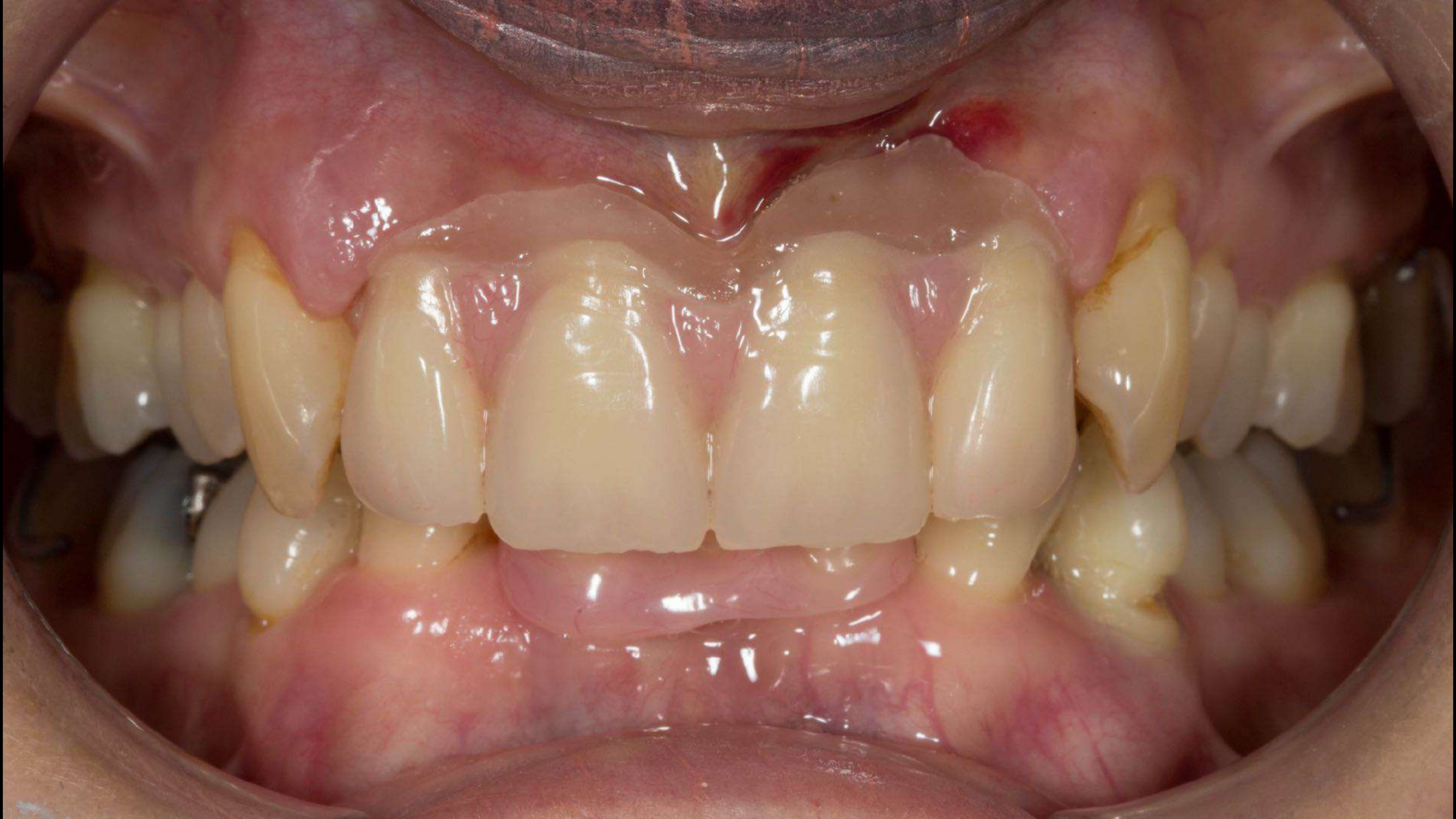


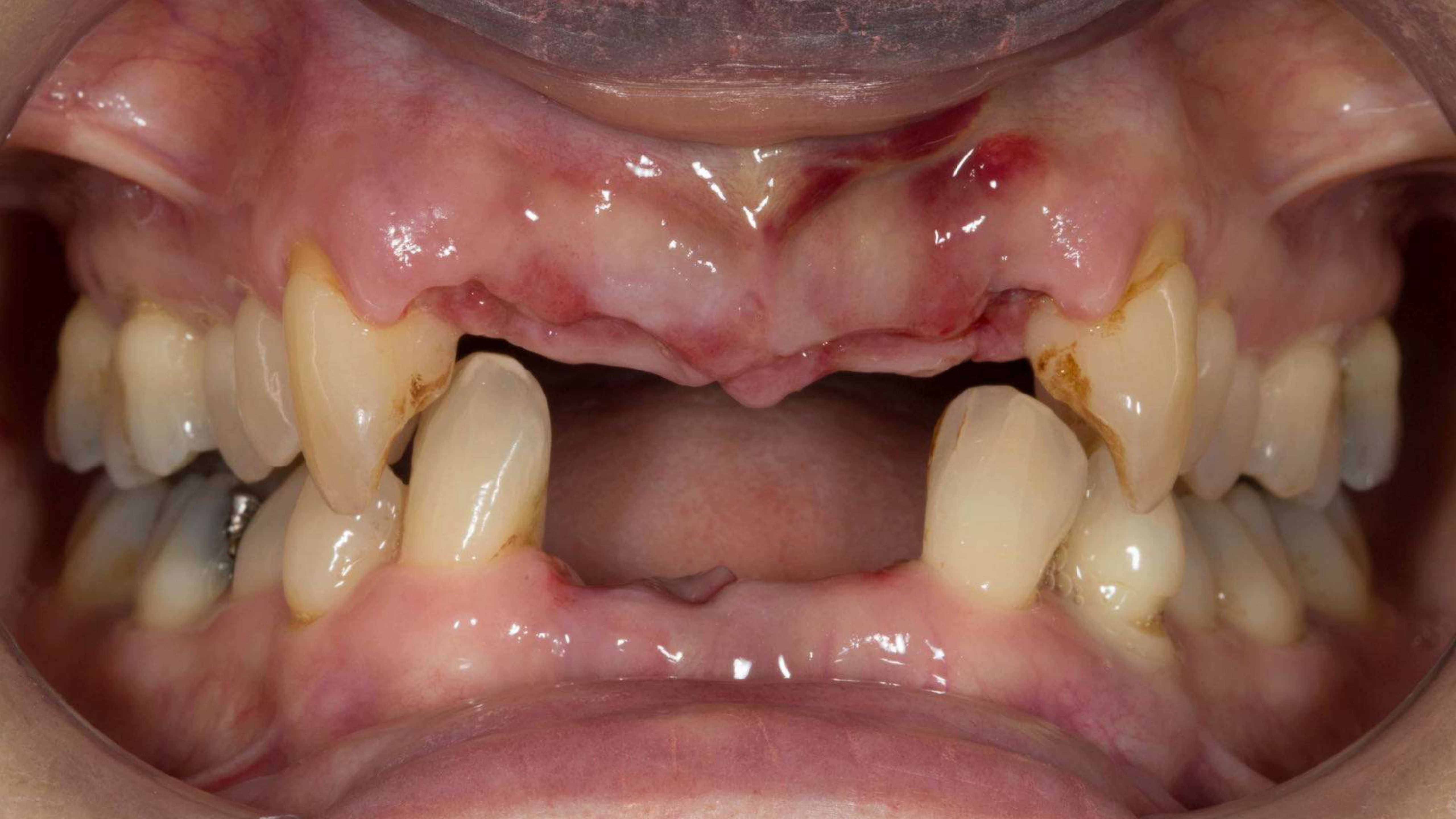



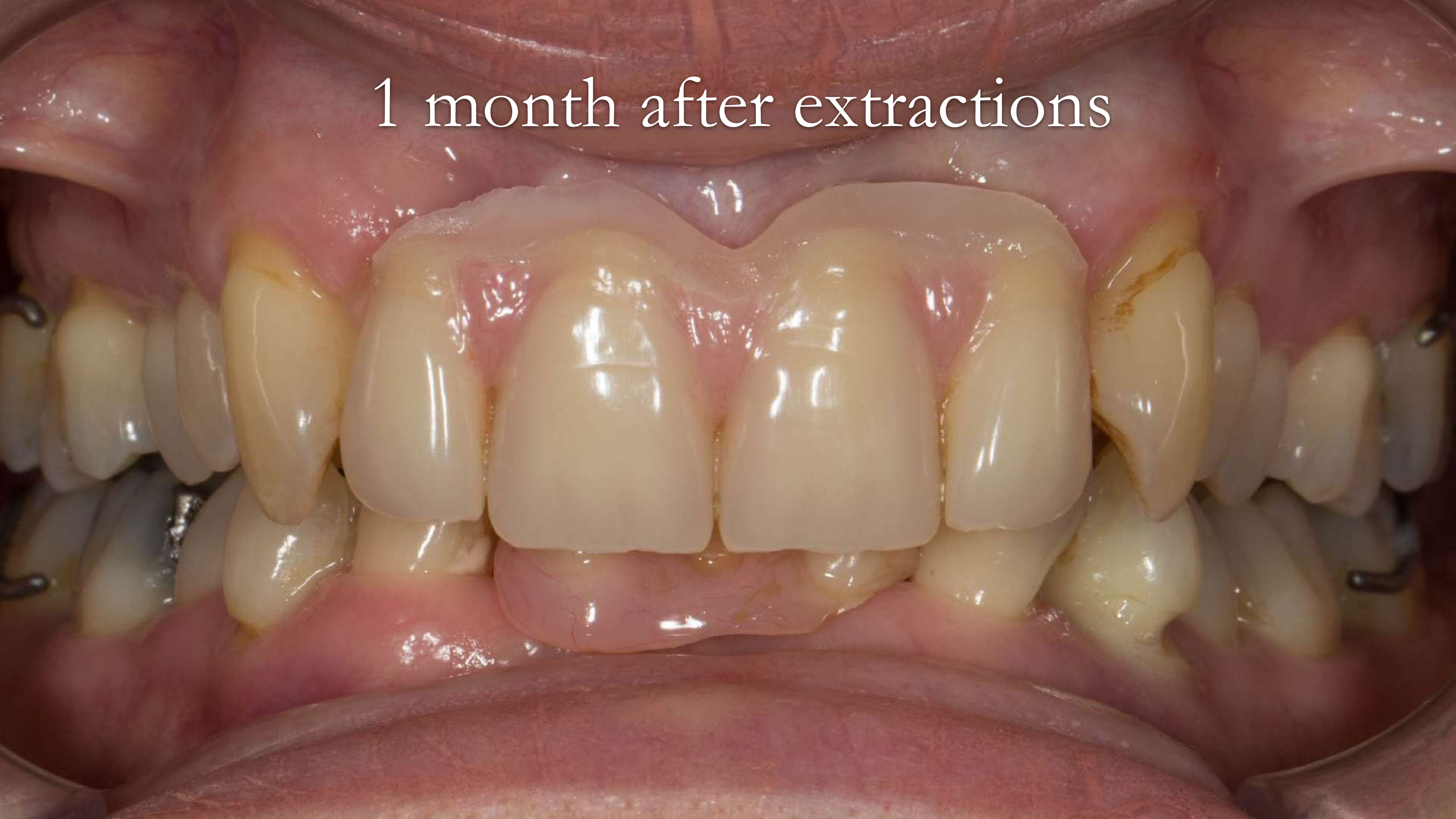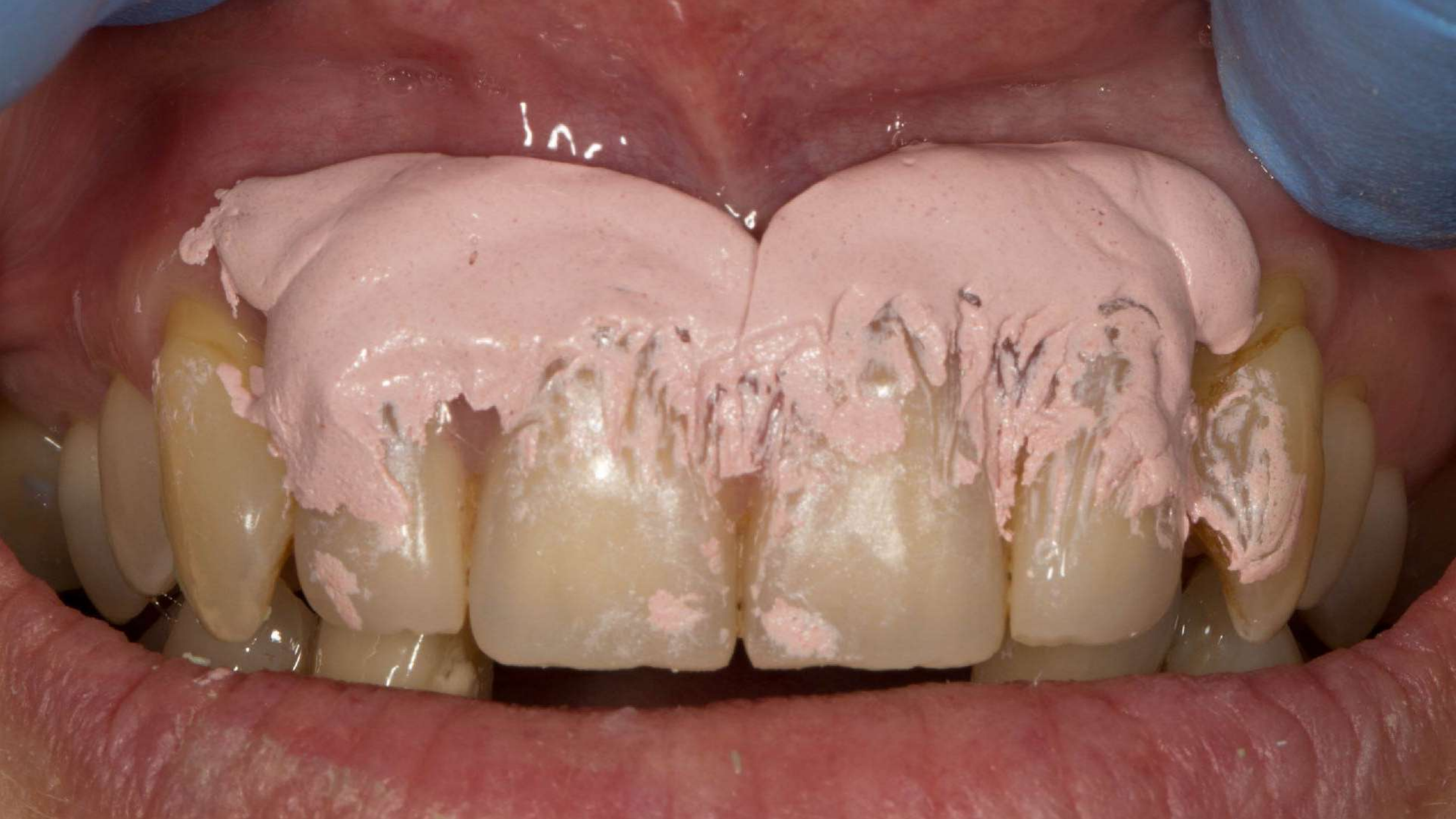1 week review

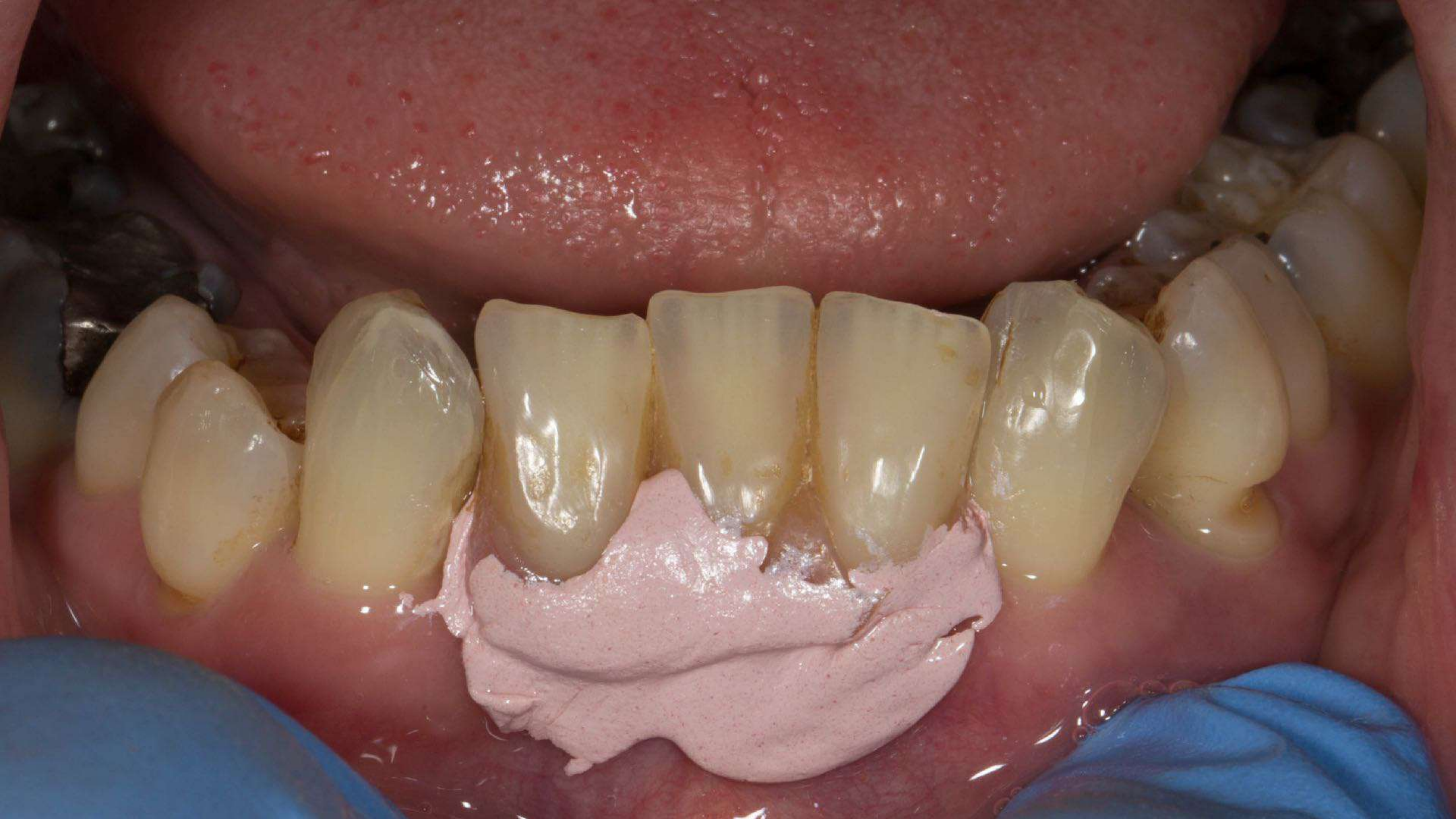

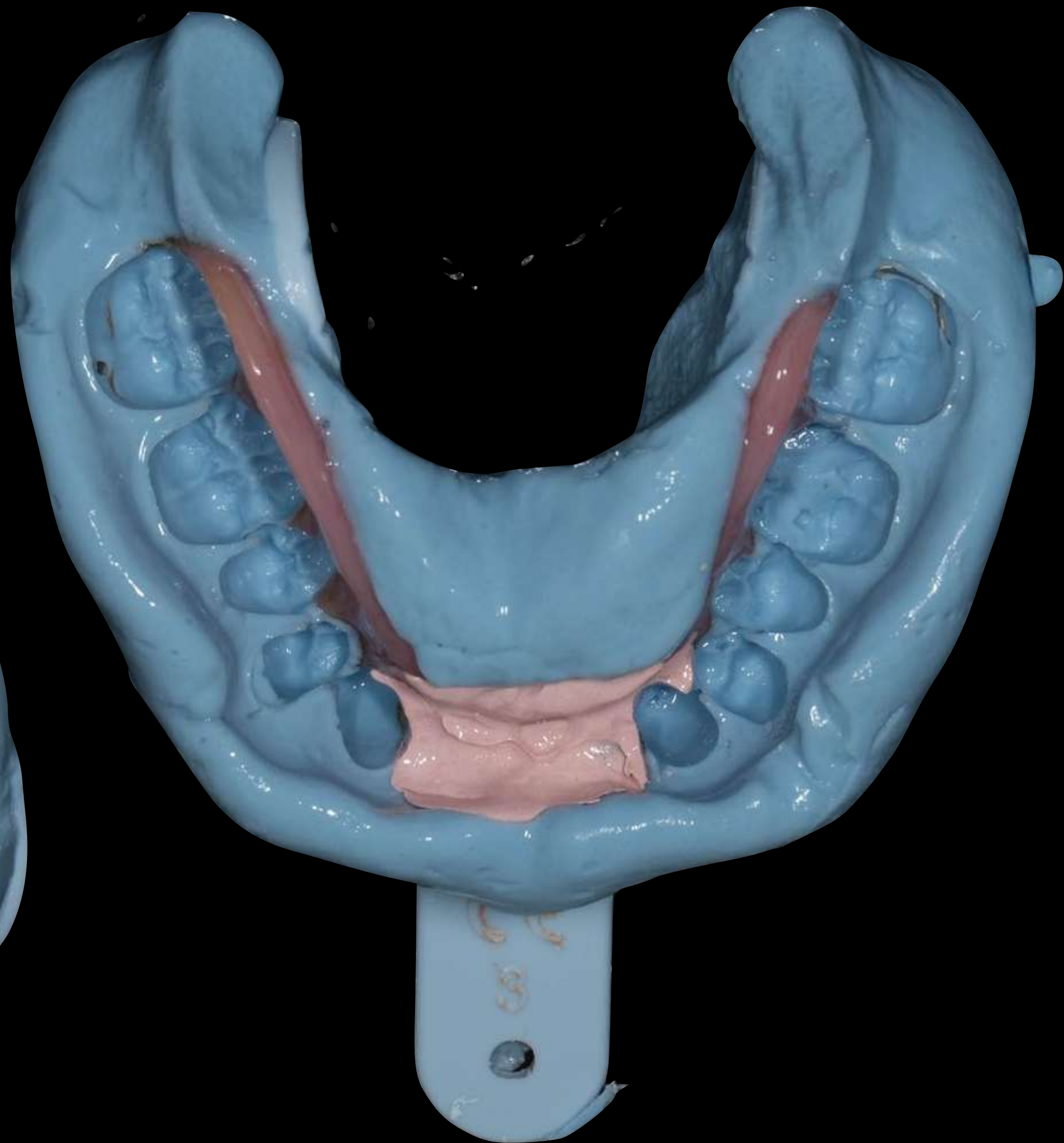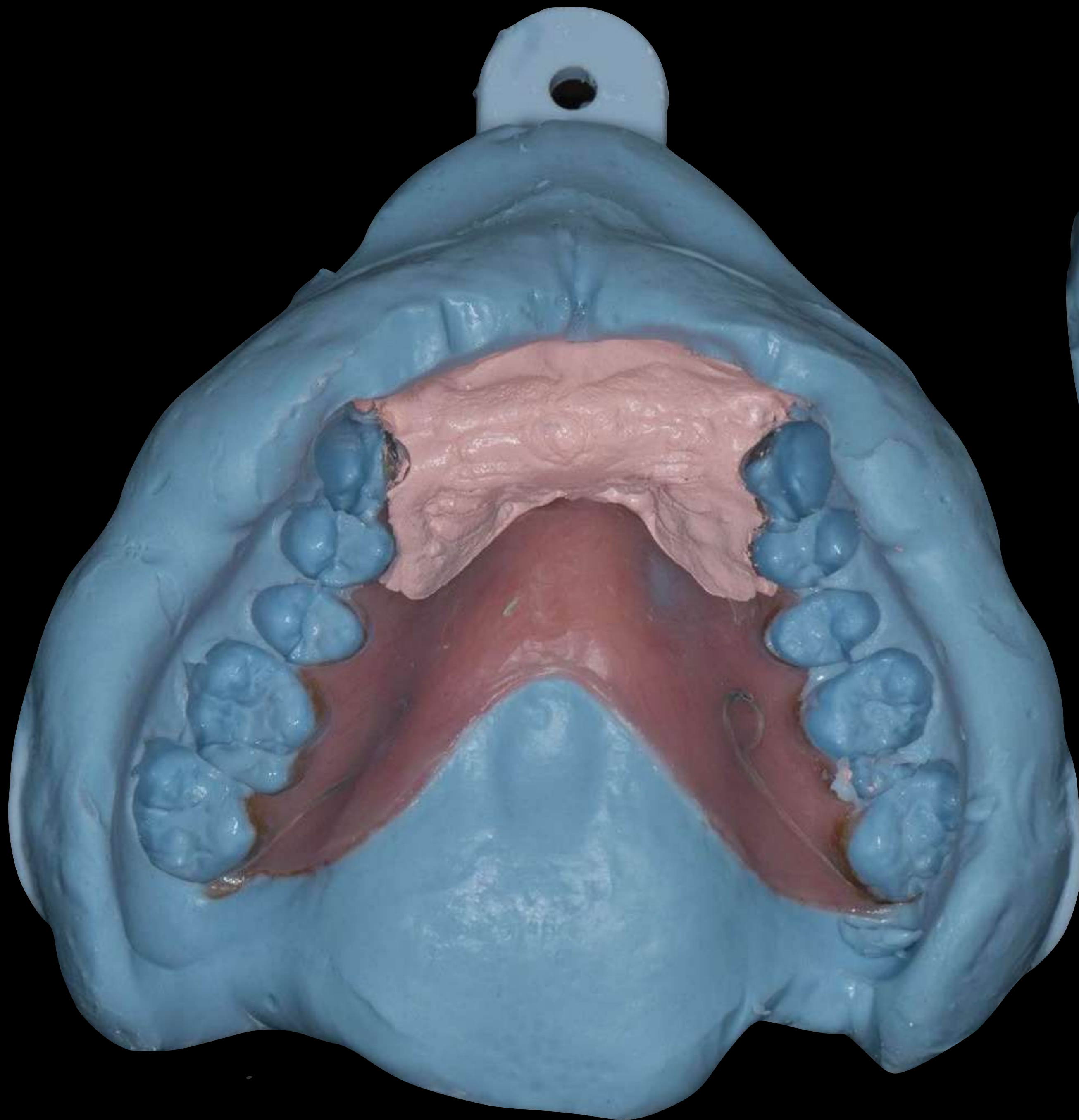


1 month after extractions

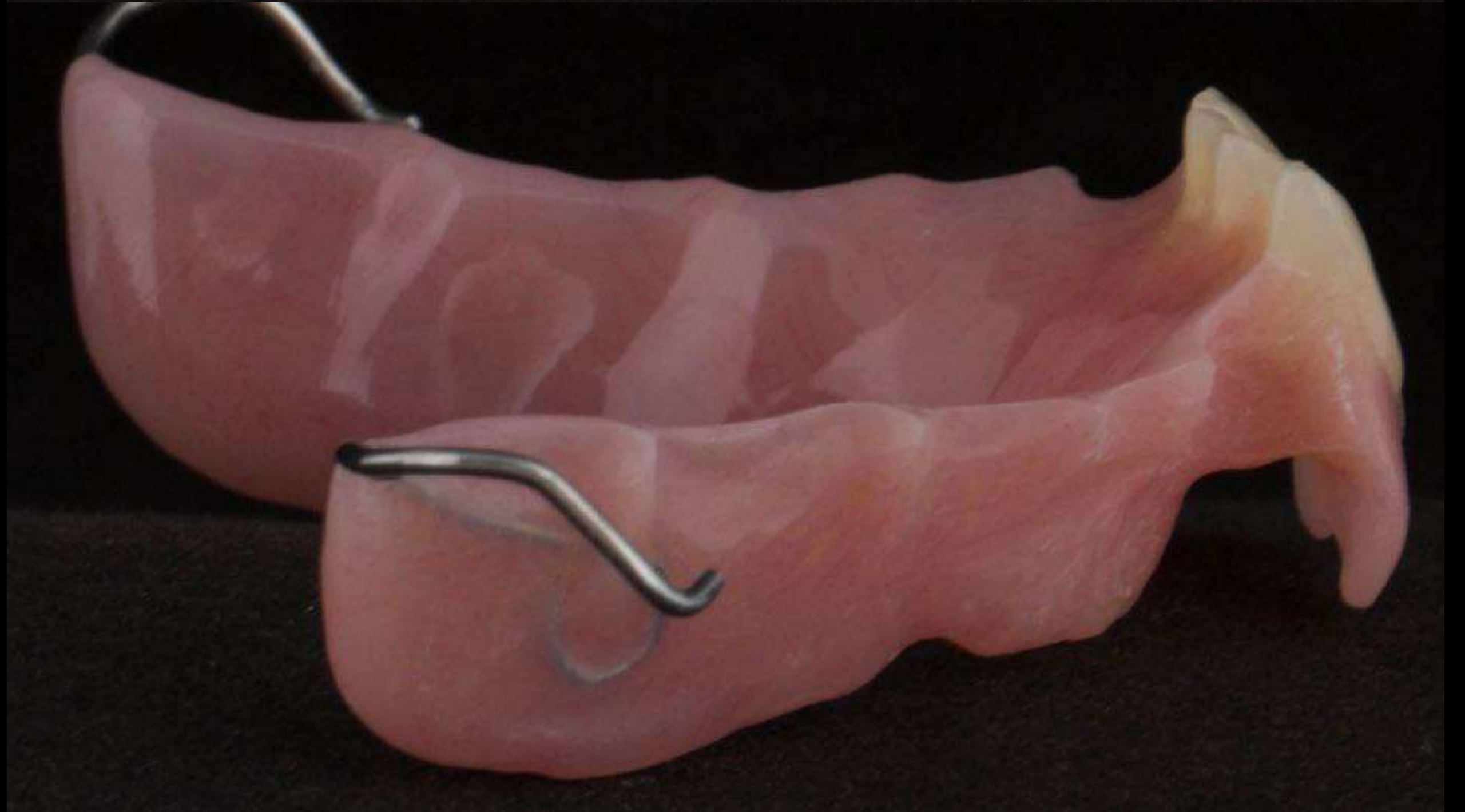
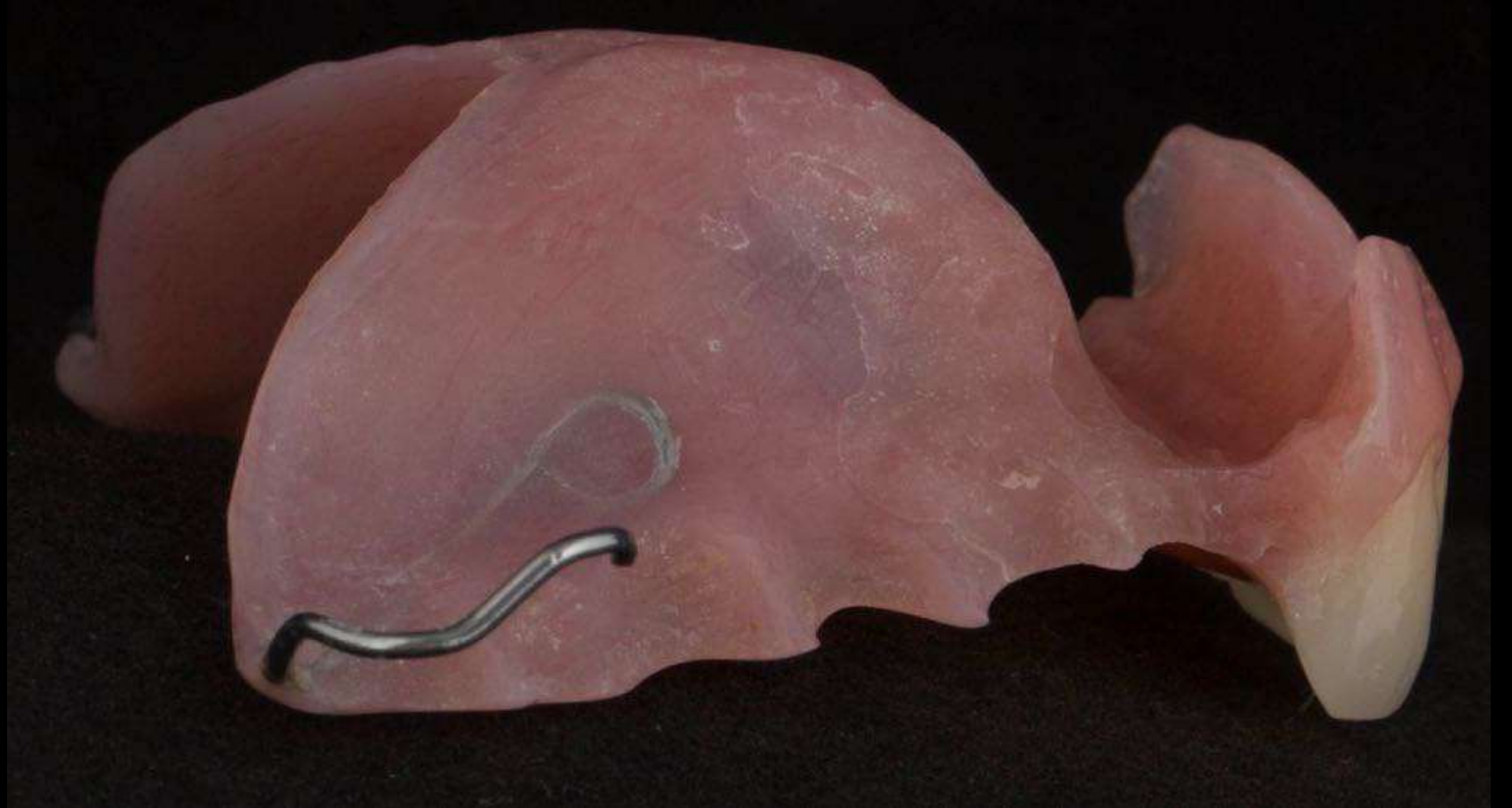


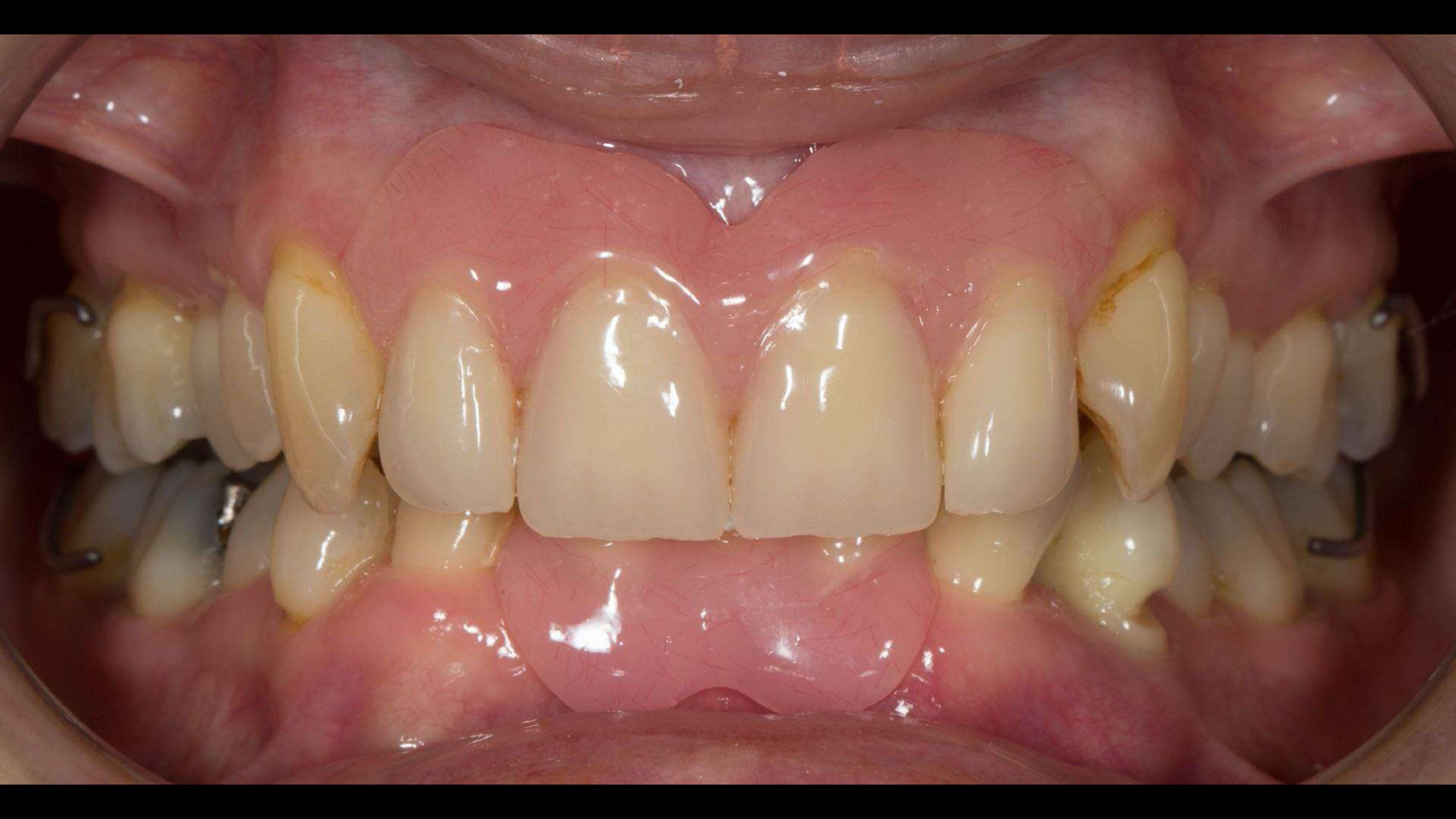

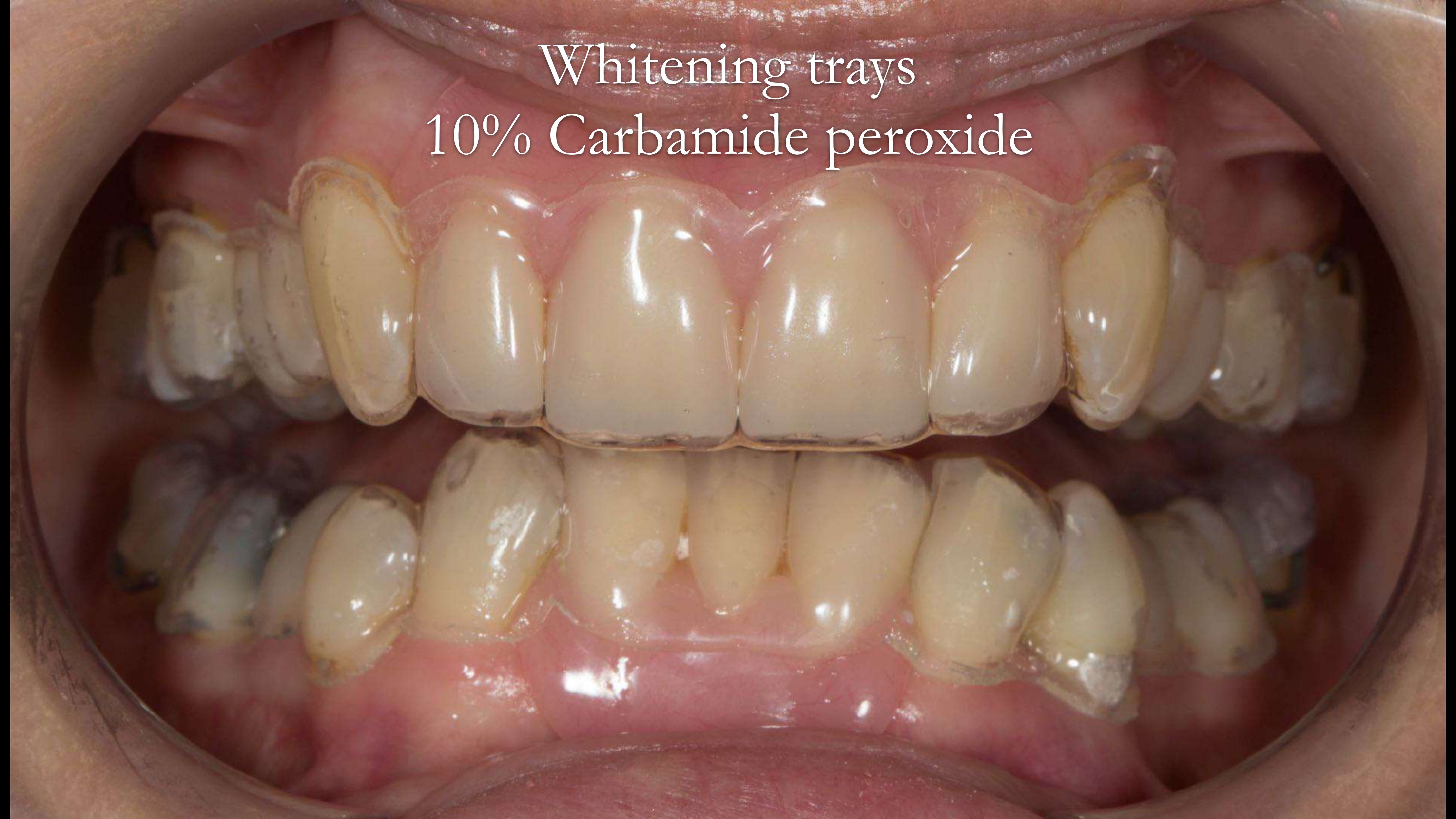


Lab reline

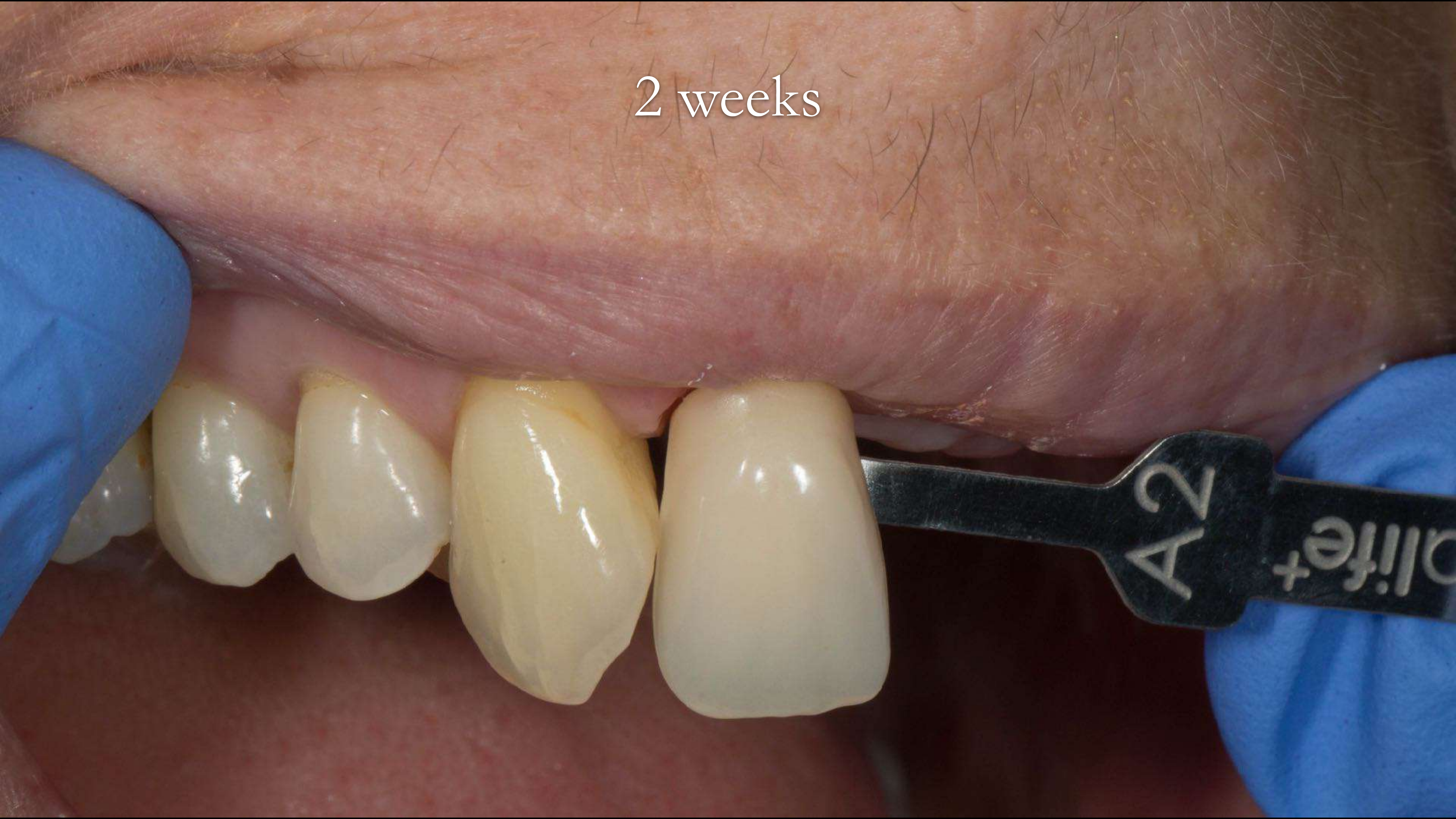



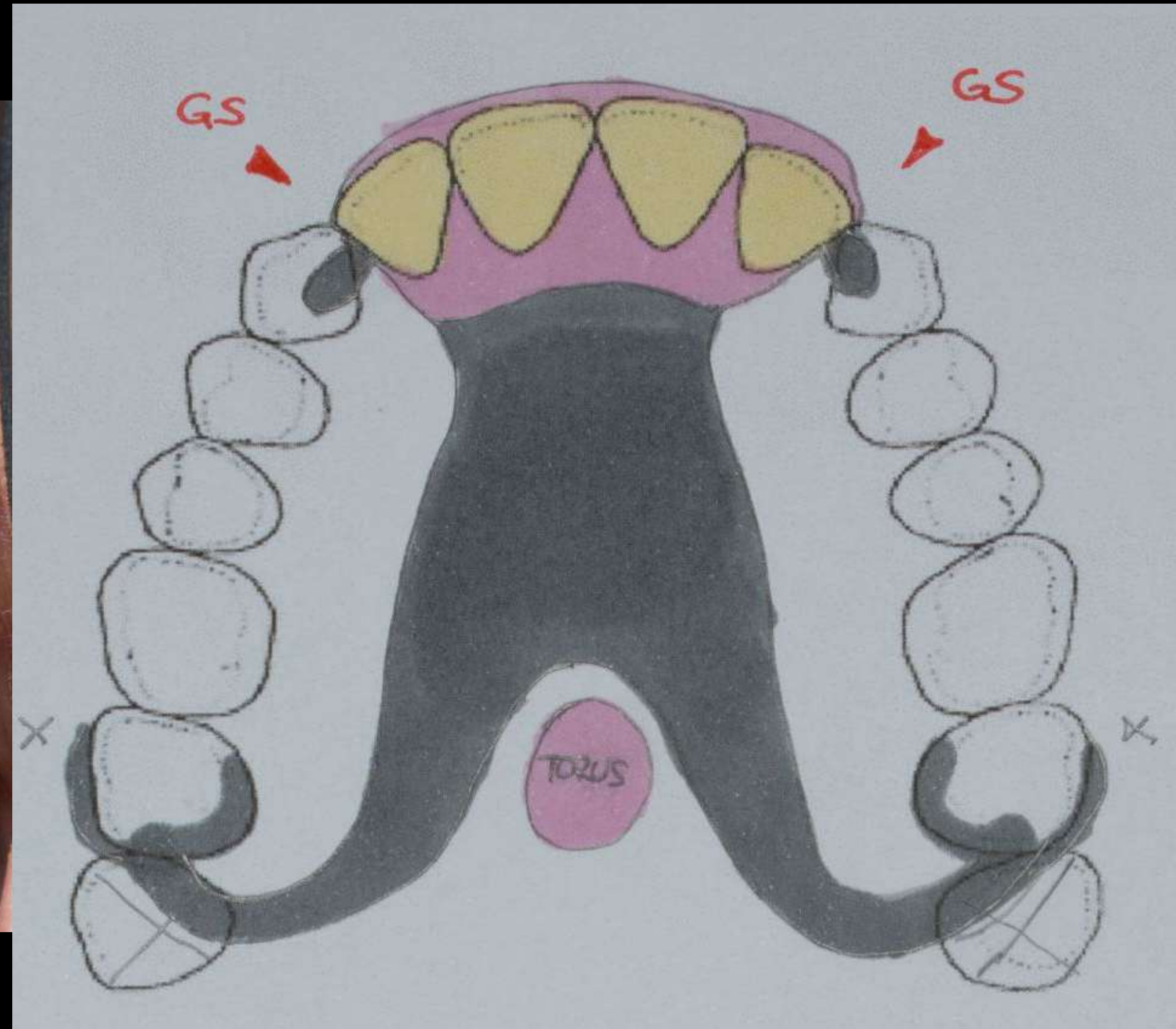
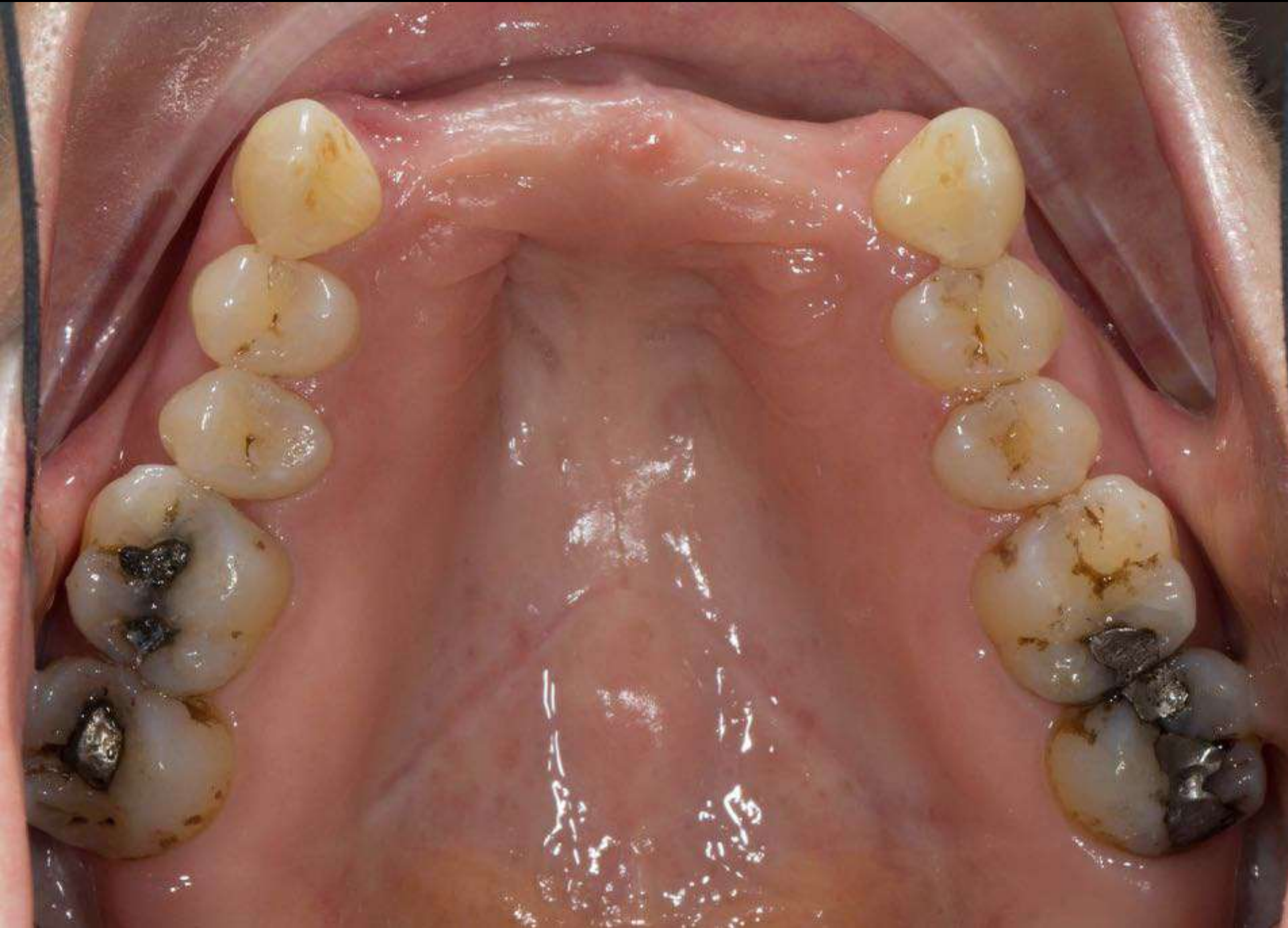
Whitening trays
10% Carbamide peroxide



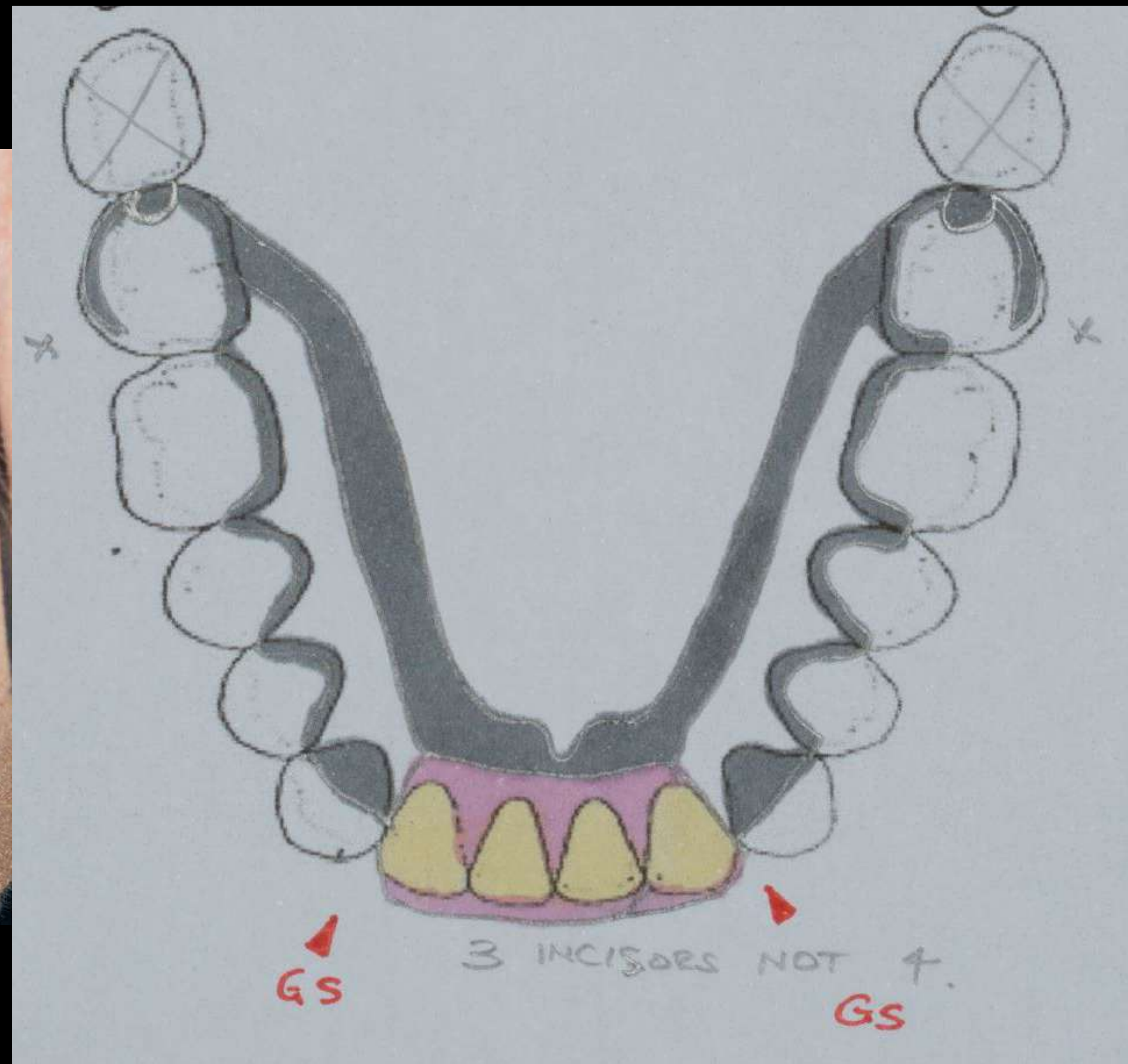
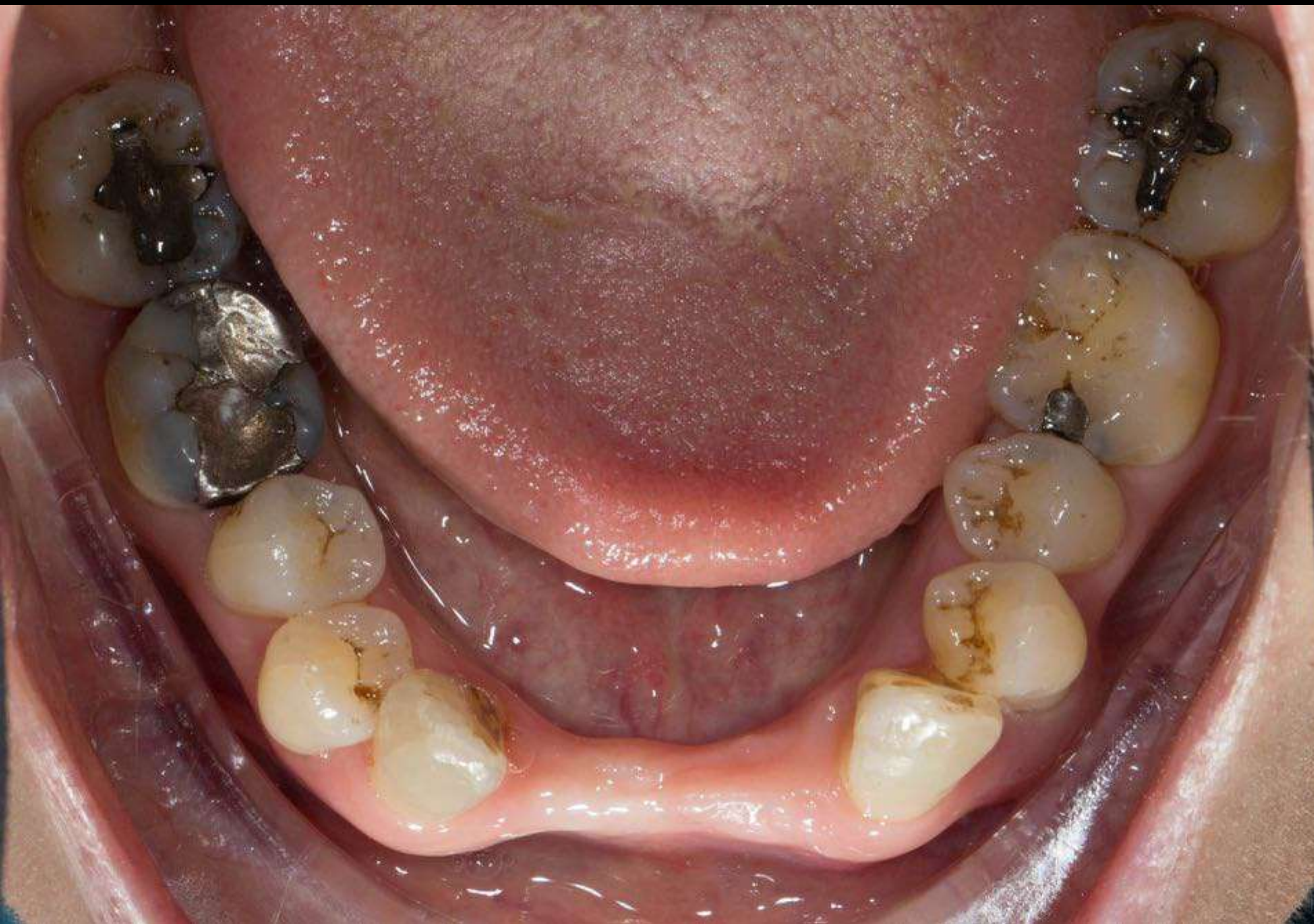2 weeks



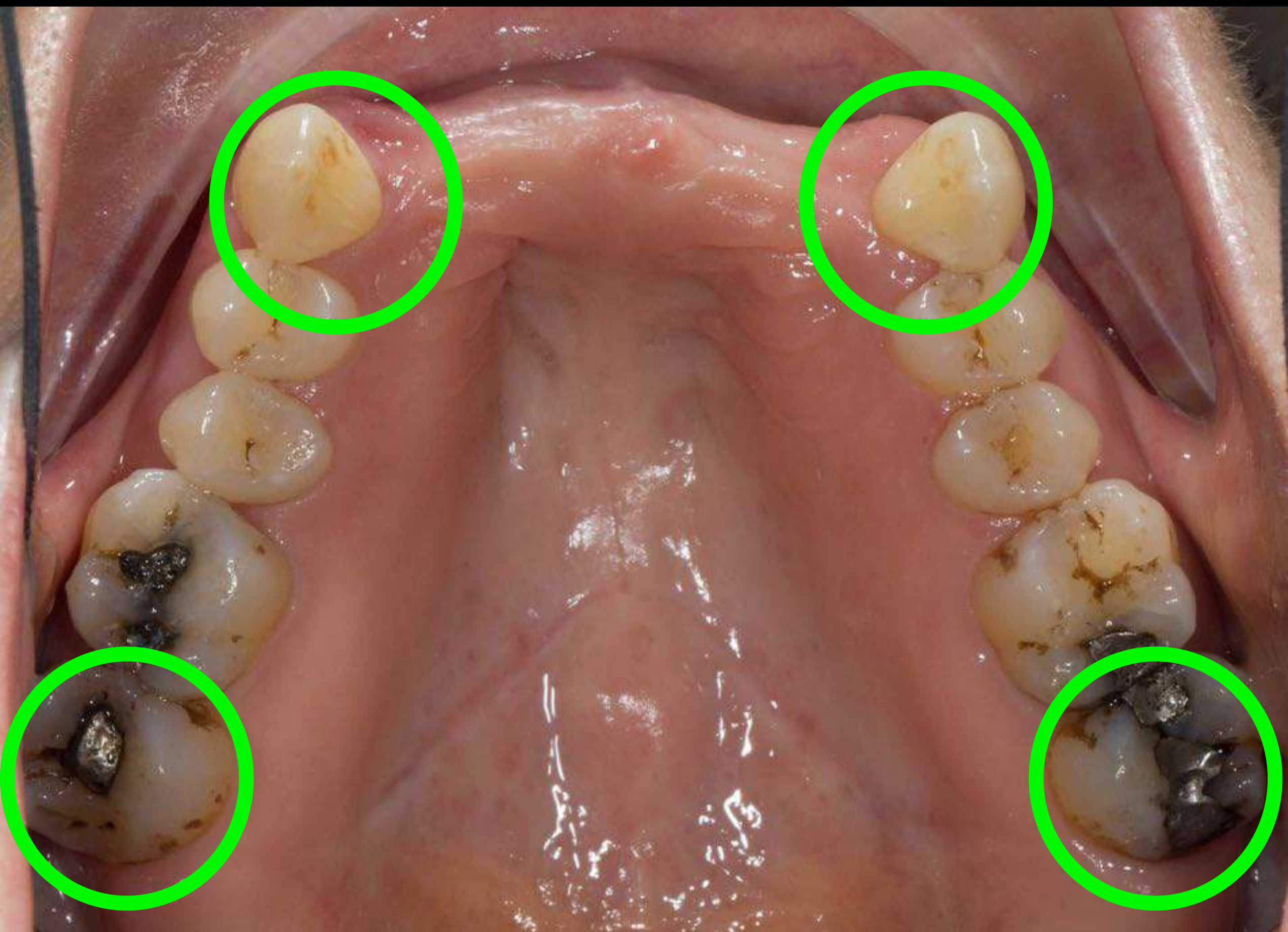
Definitive design



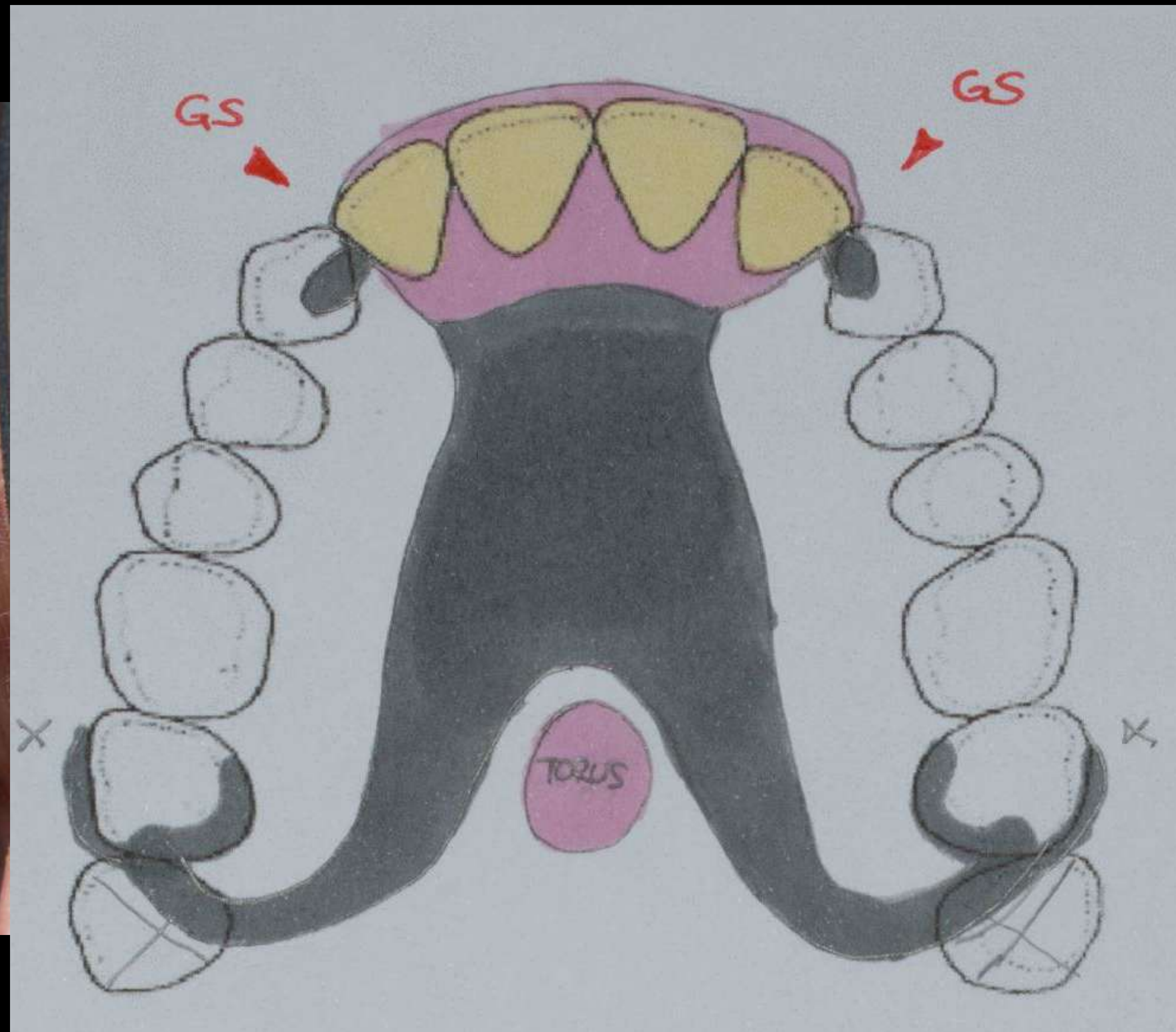
Definitive design



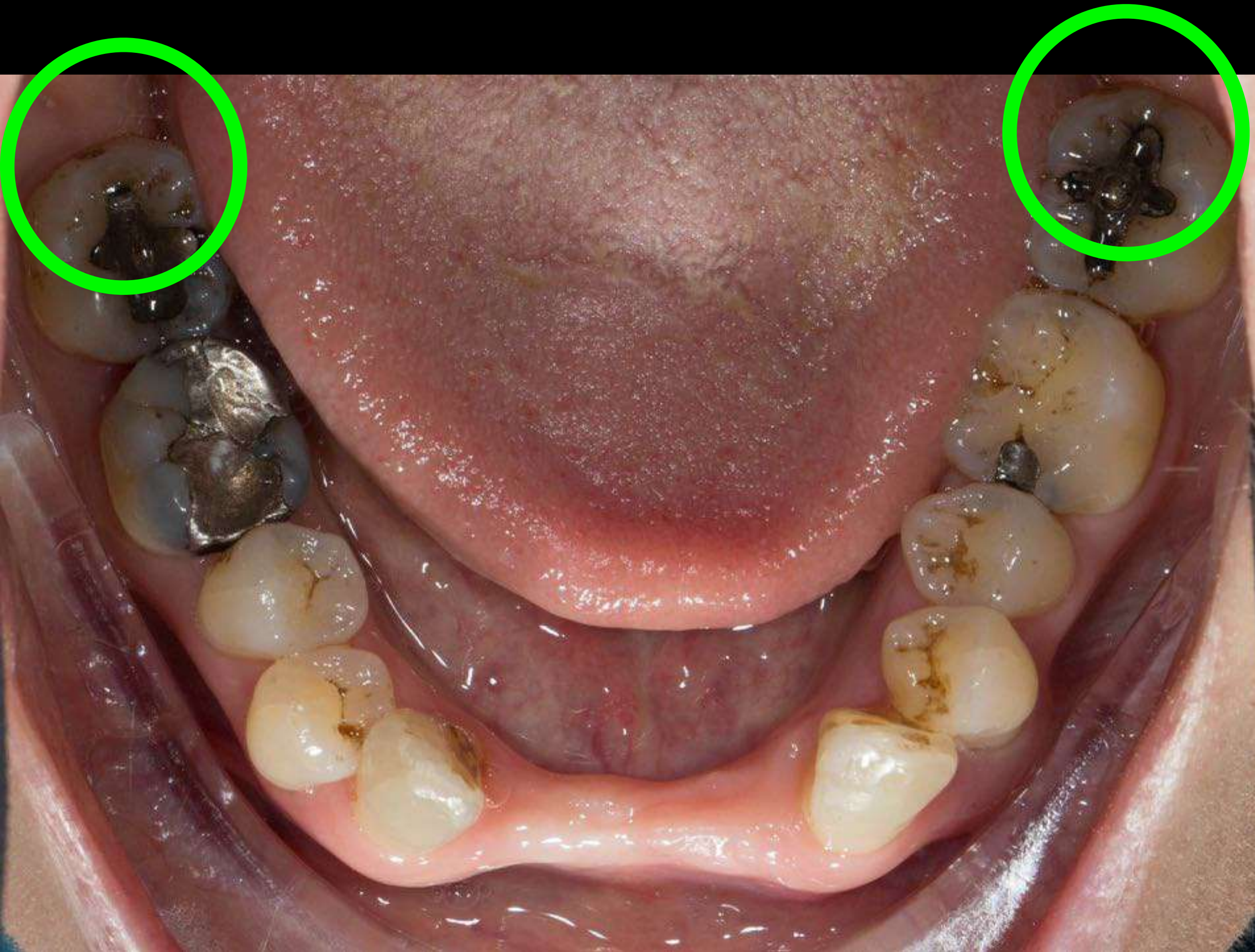
Rest seat preparation



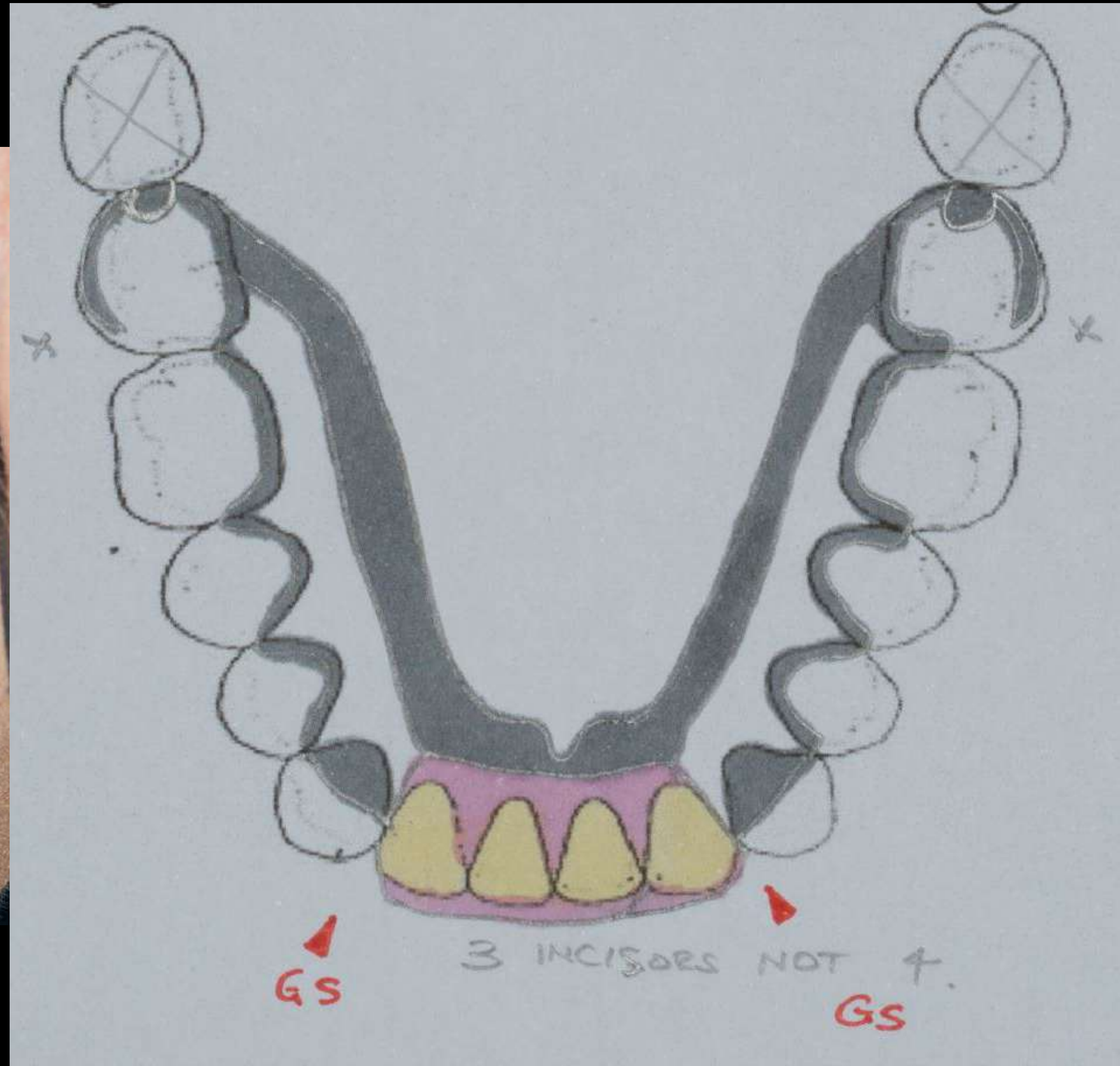
Occlusal space



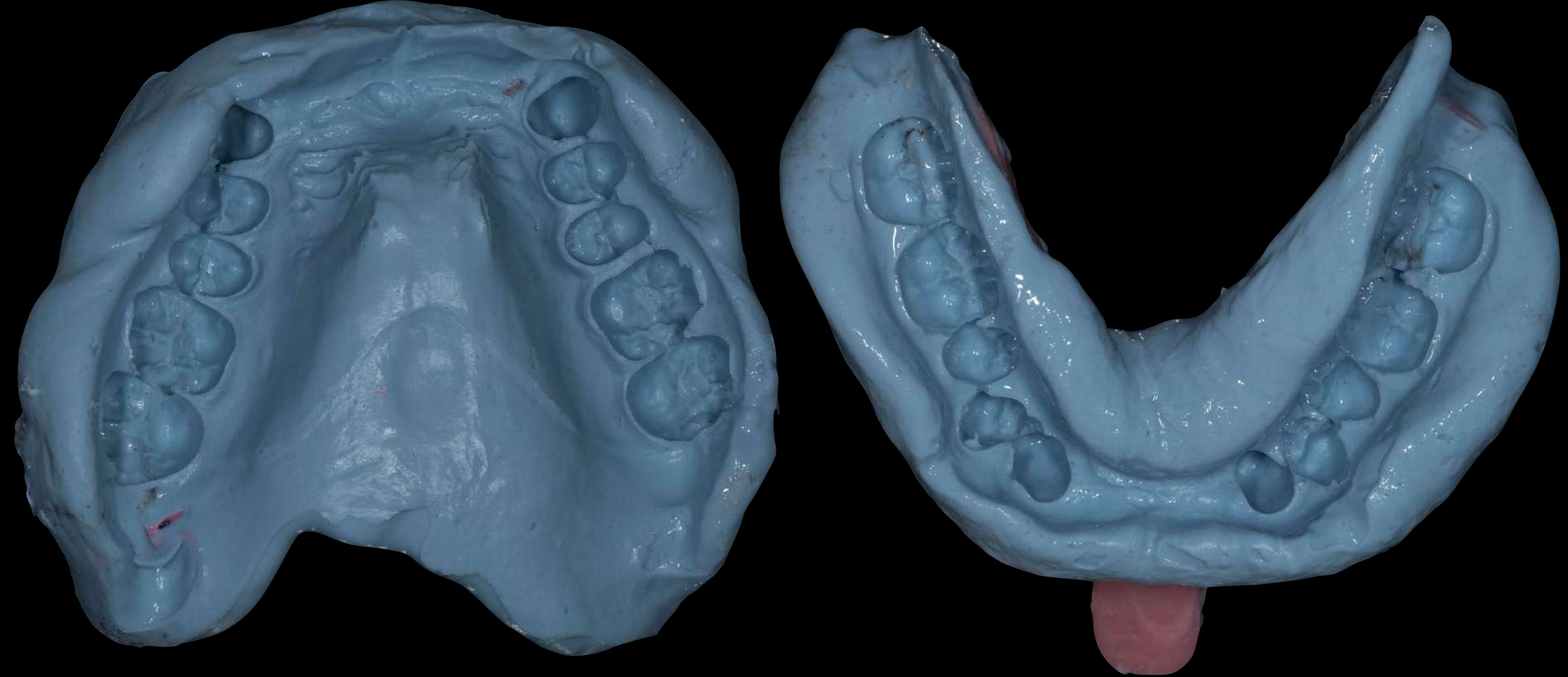
Rest seat preparation



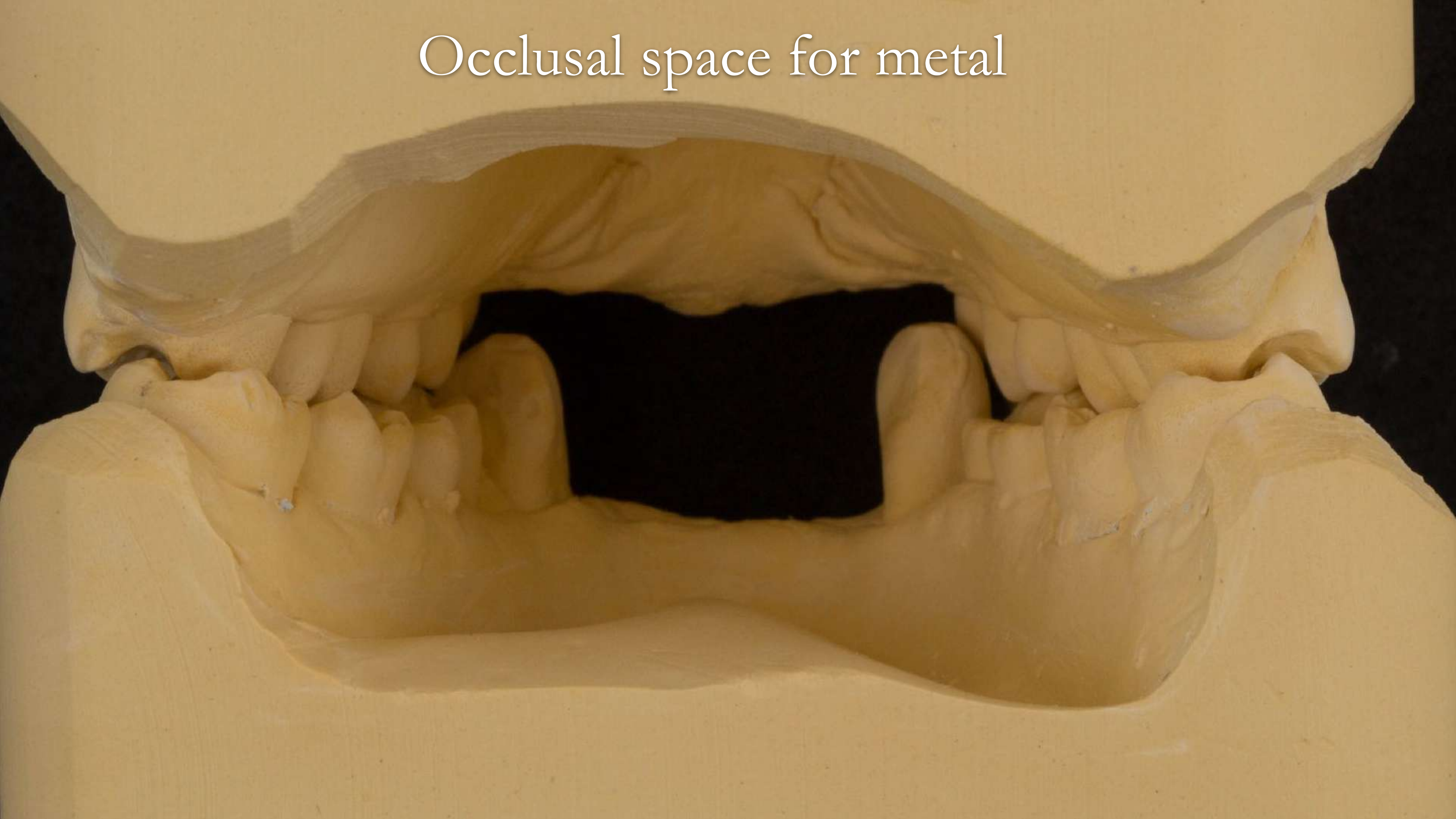
Occlusal space

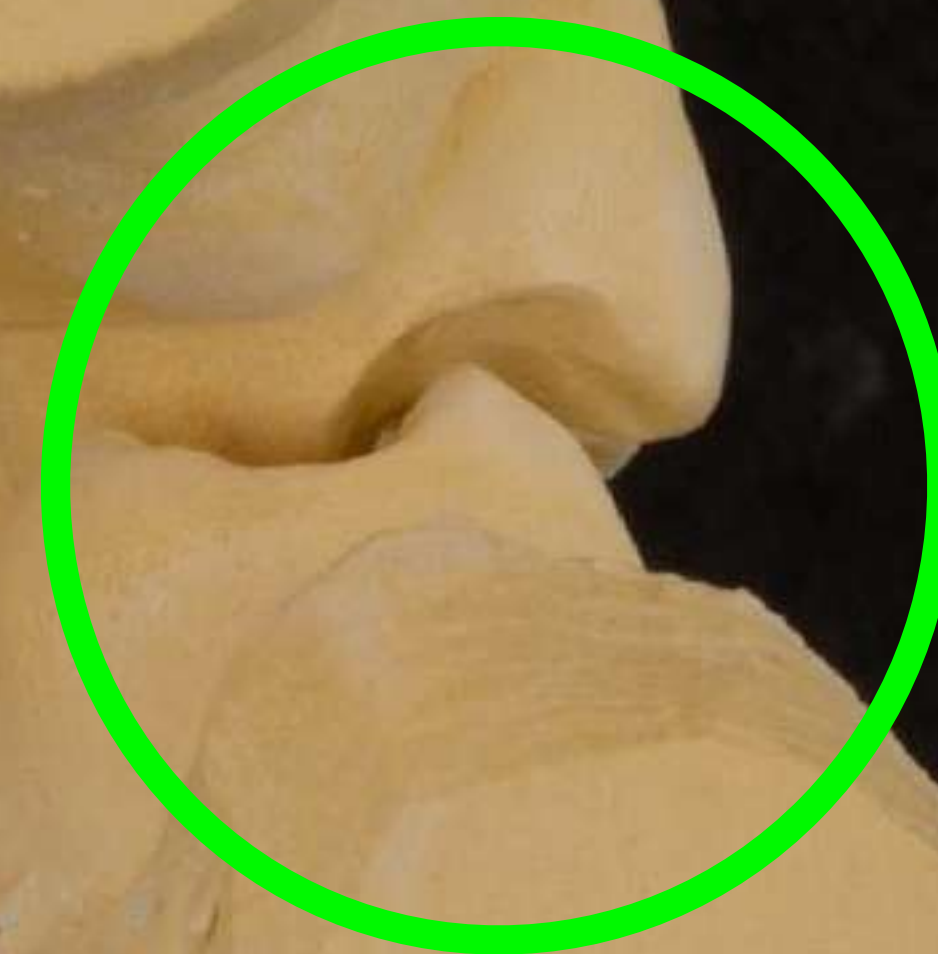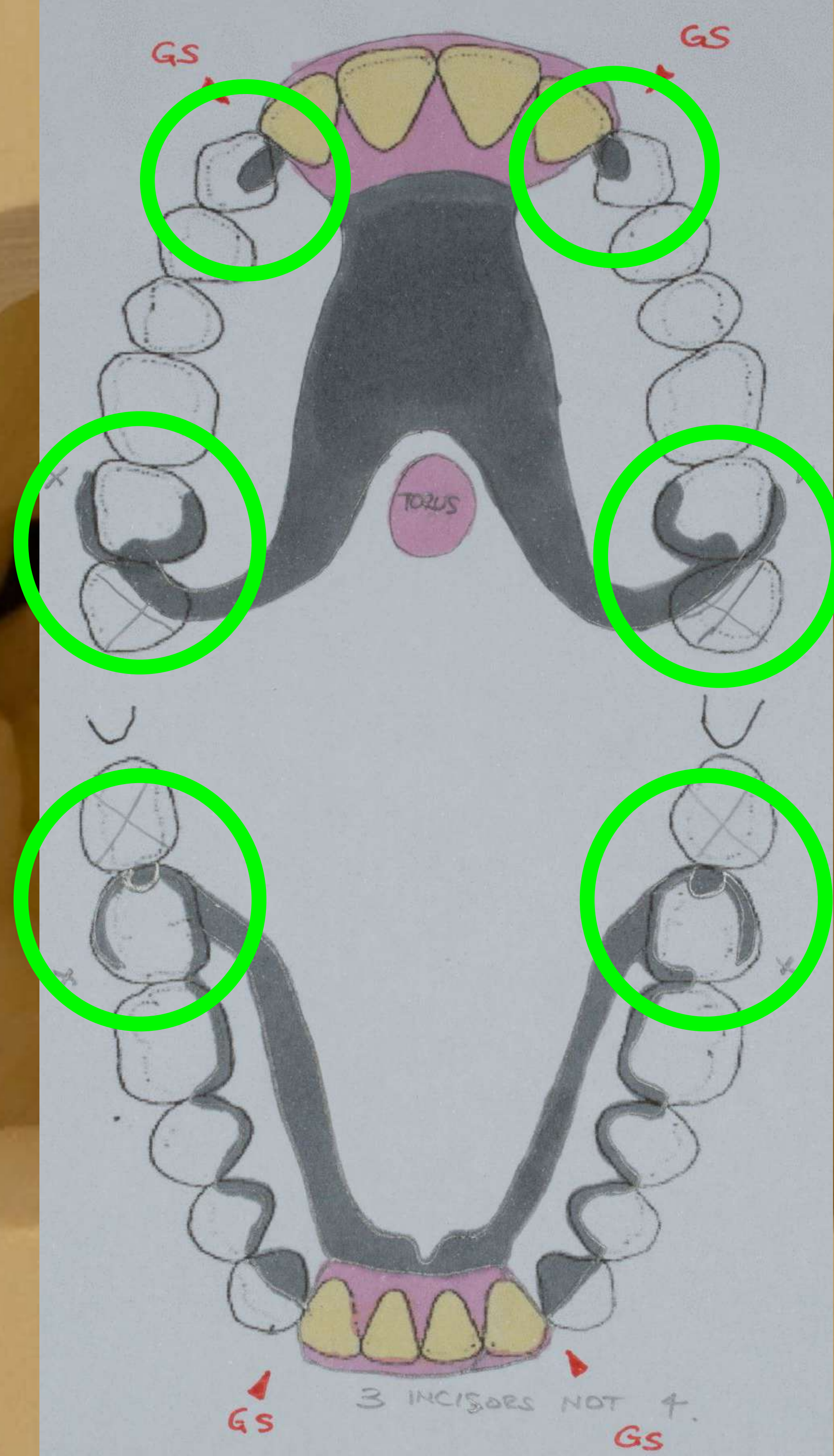


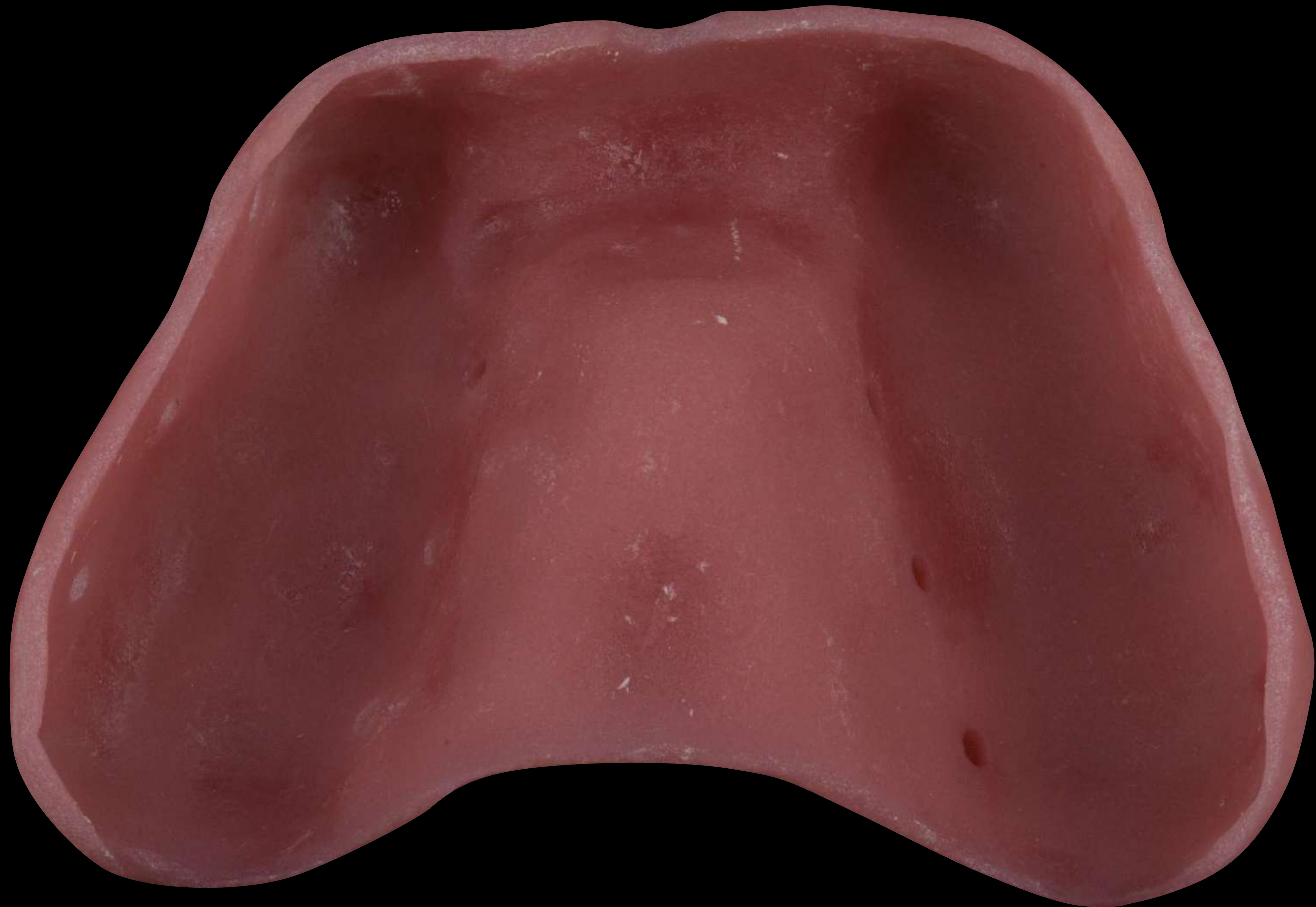
Check impressions



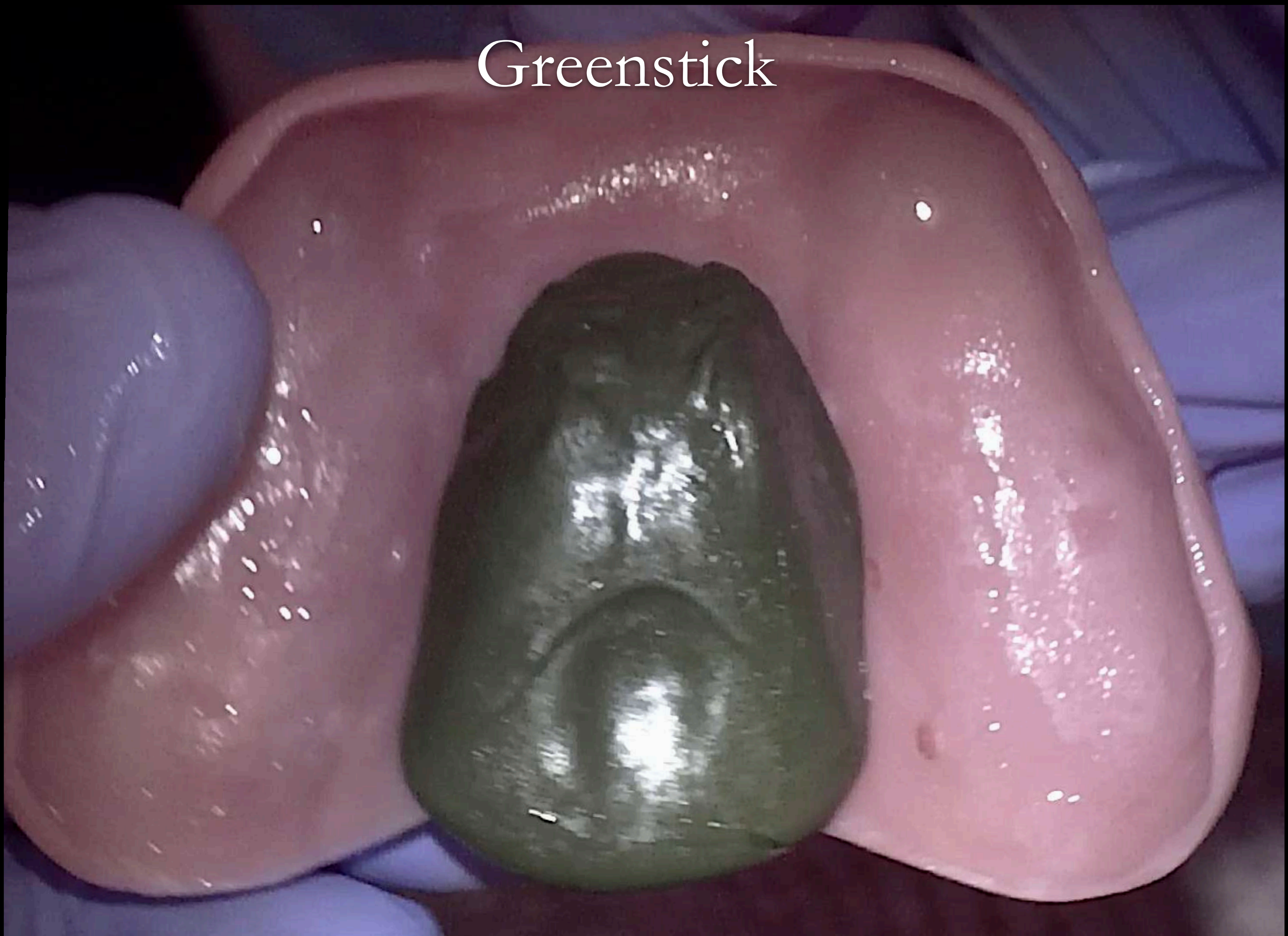Occlusal space for metal



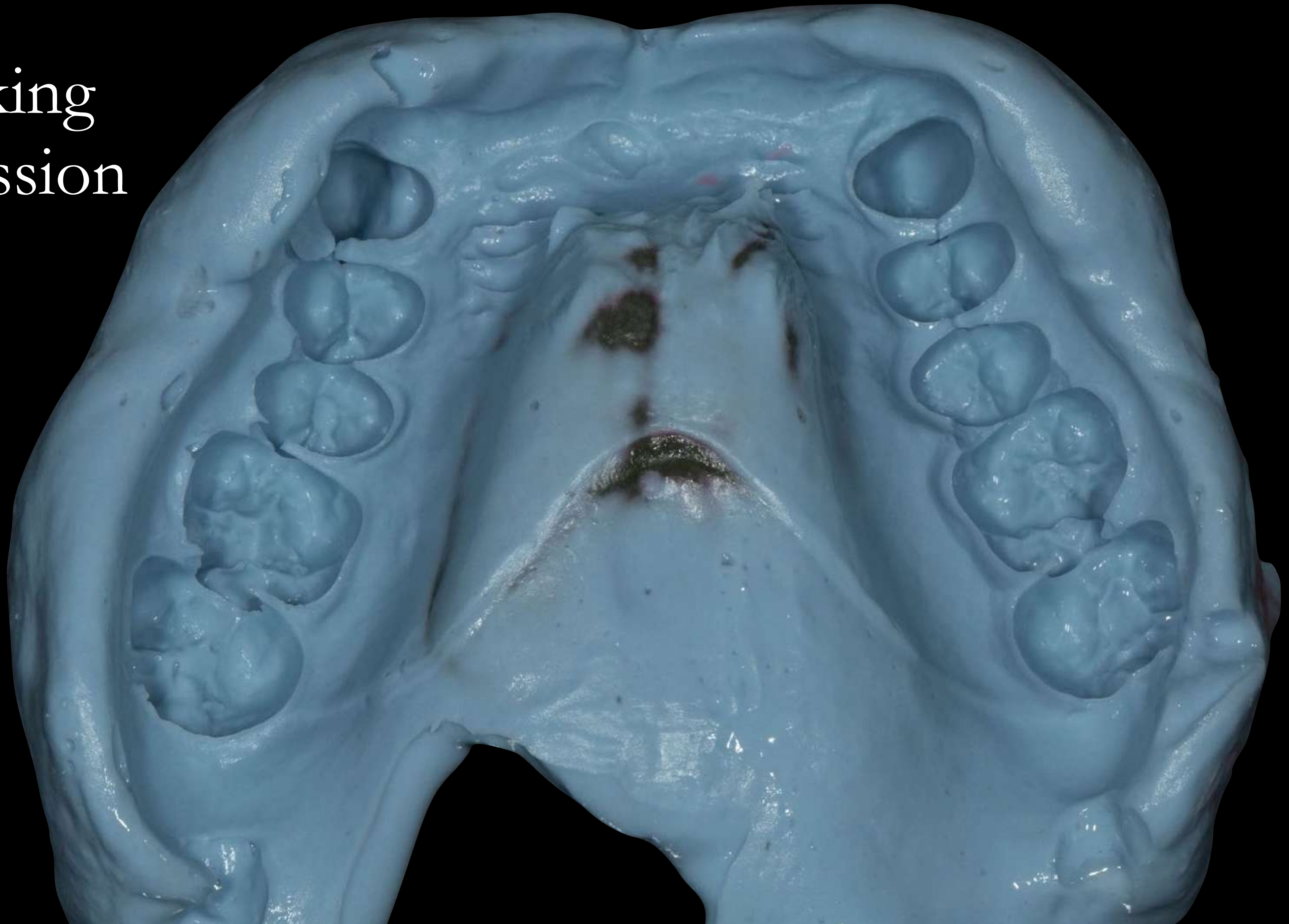




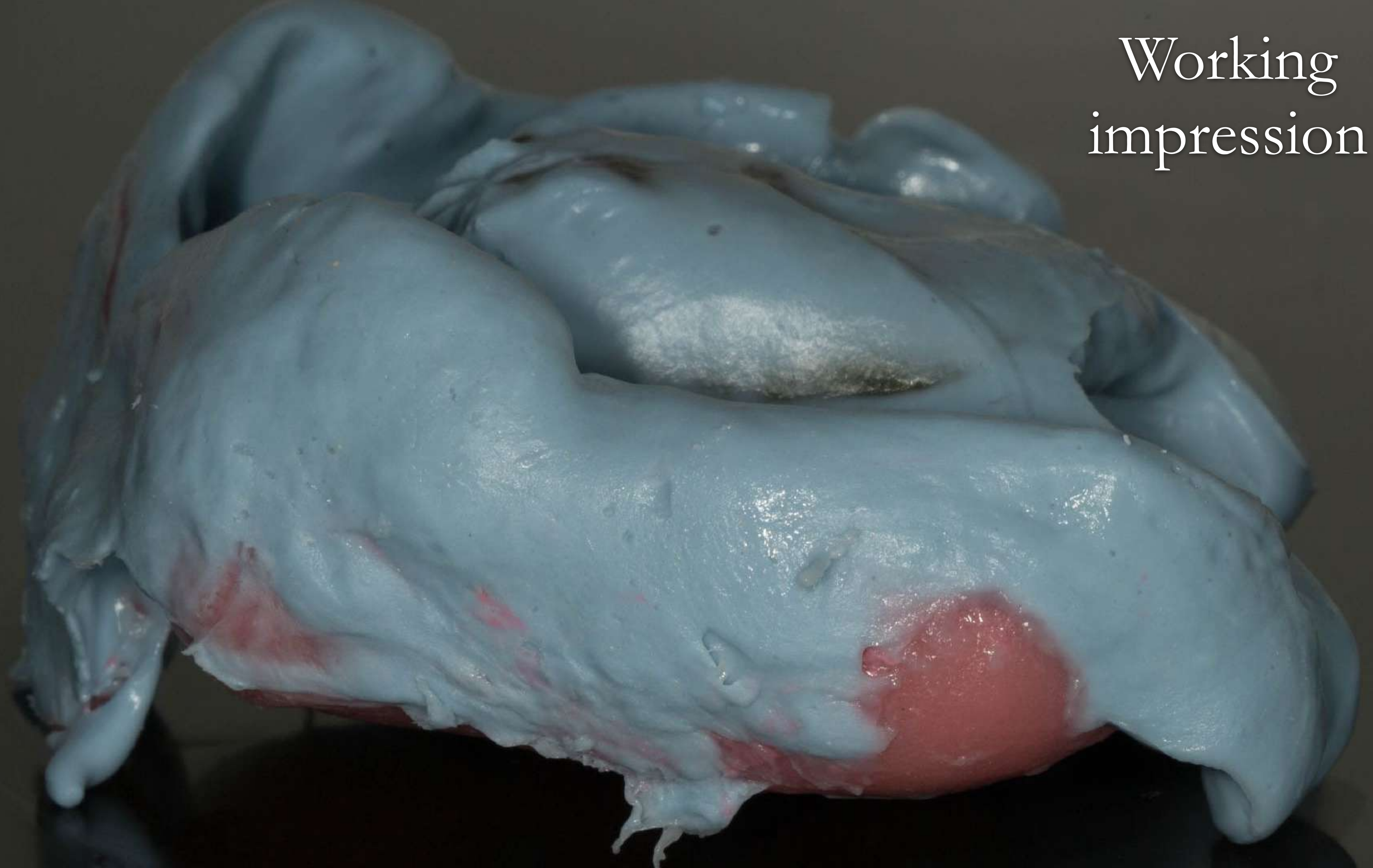Greenstick

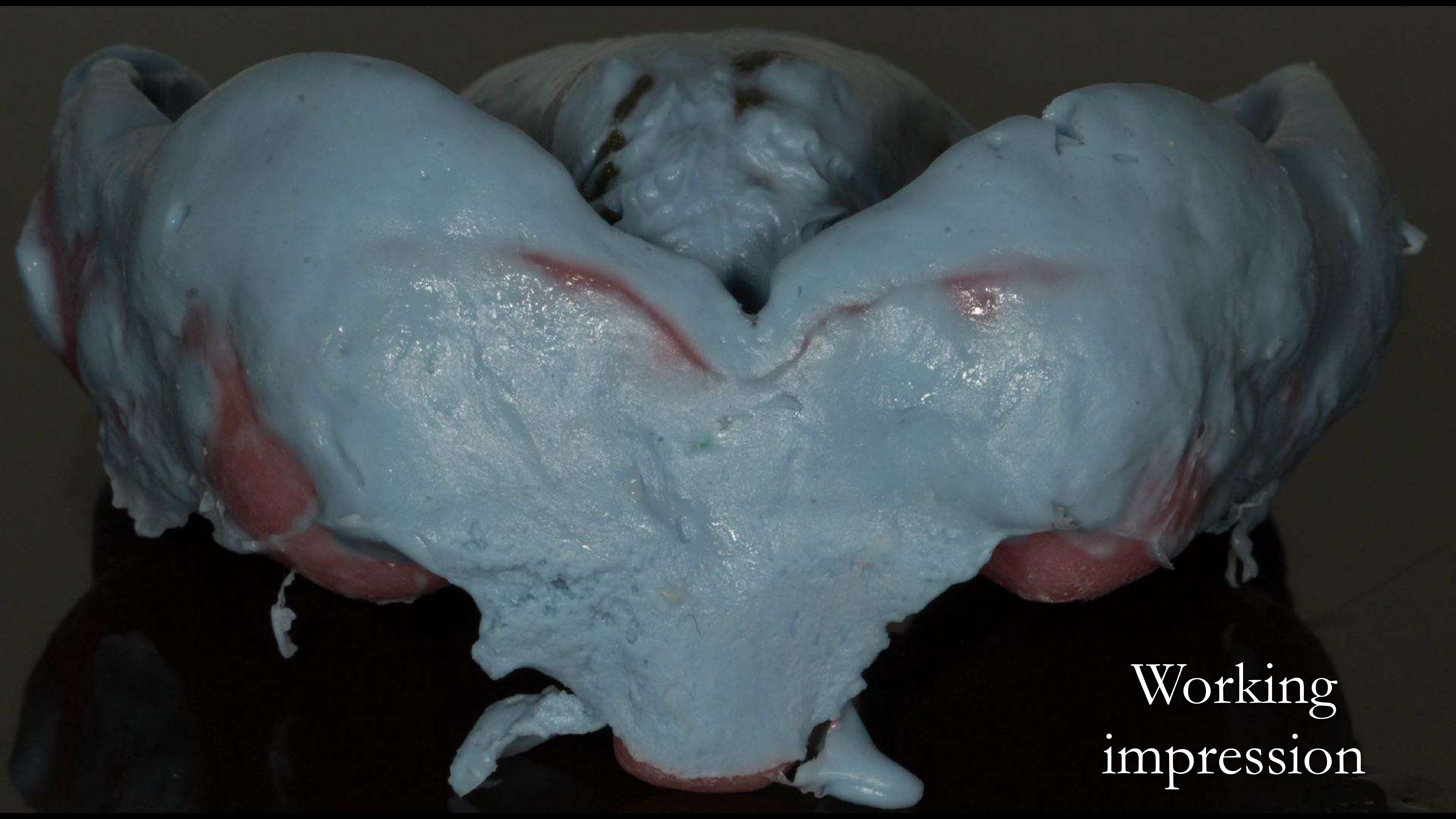

Working
impression



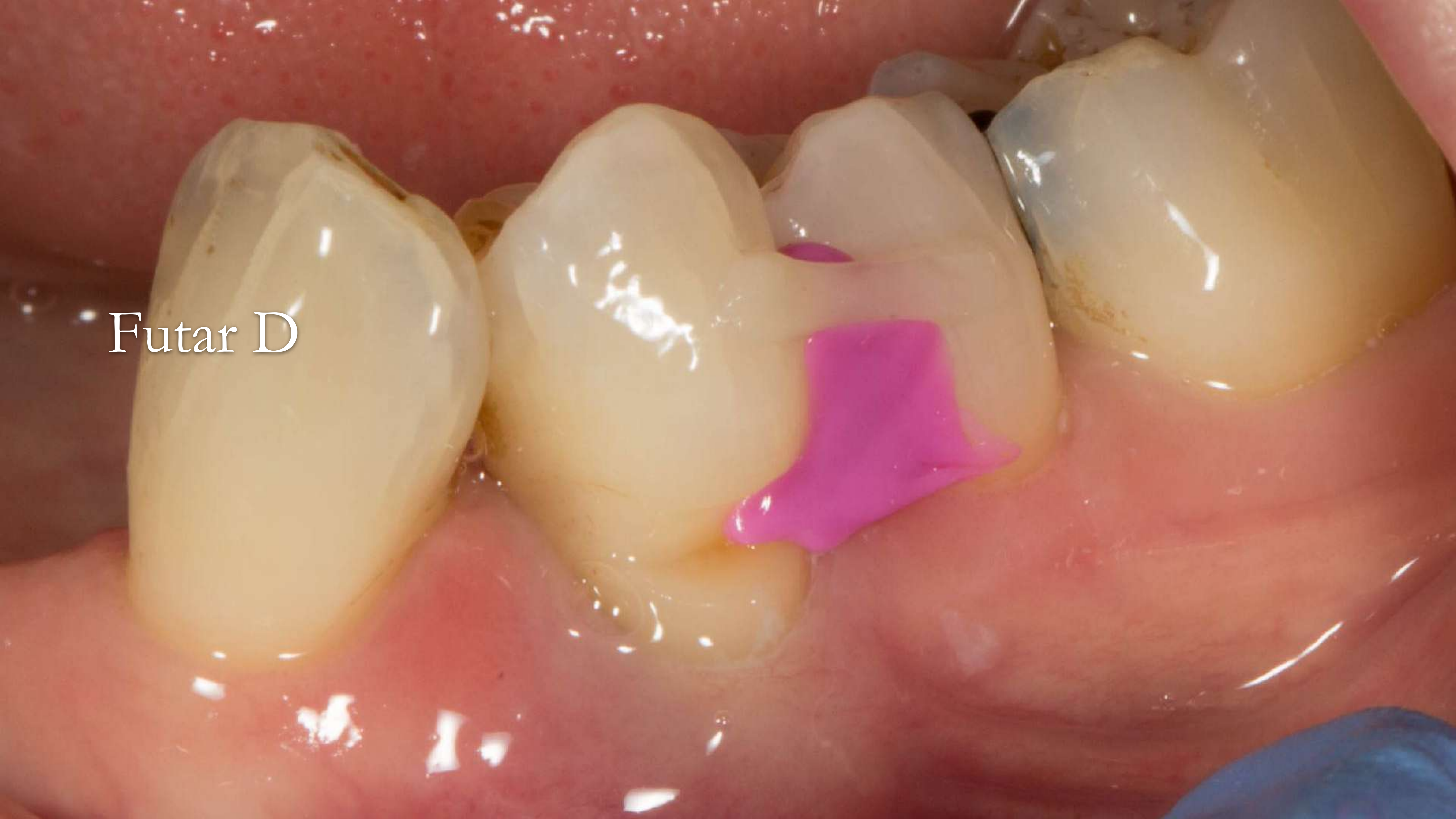Working
impression



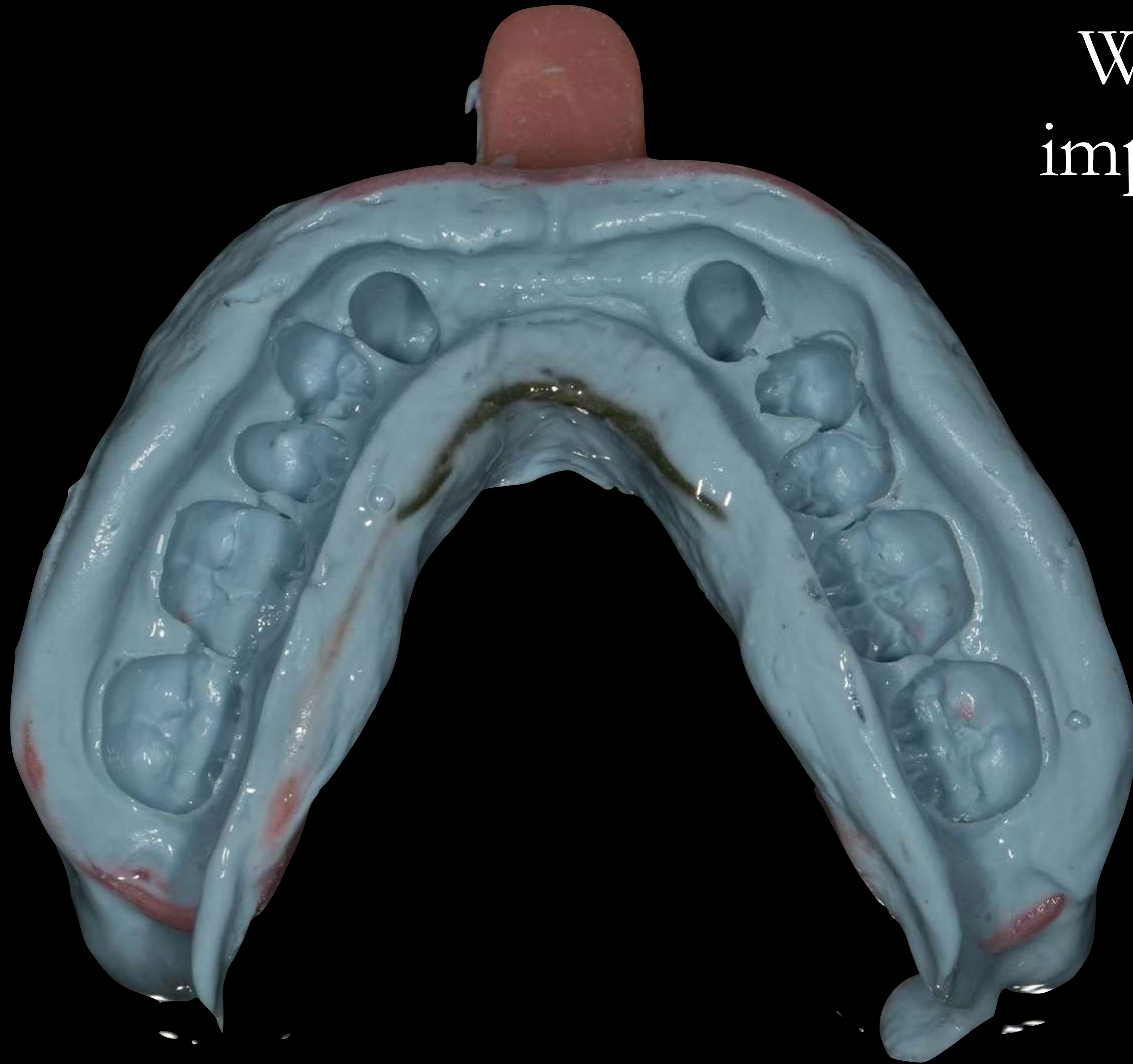


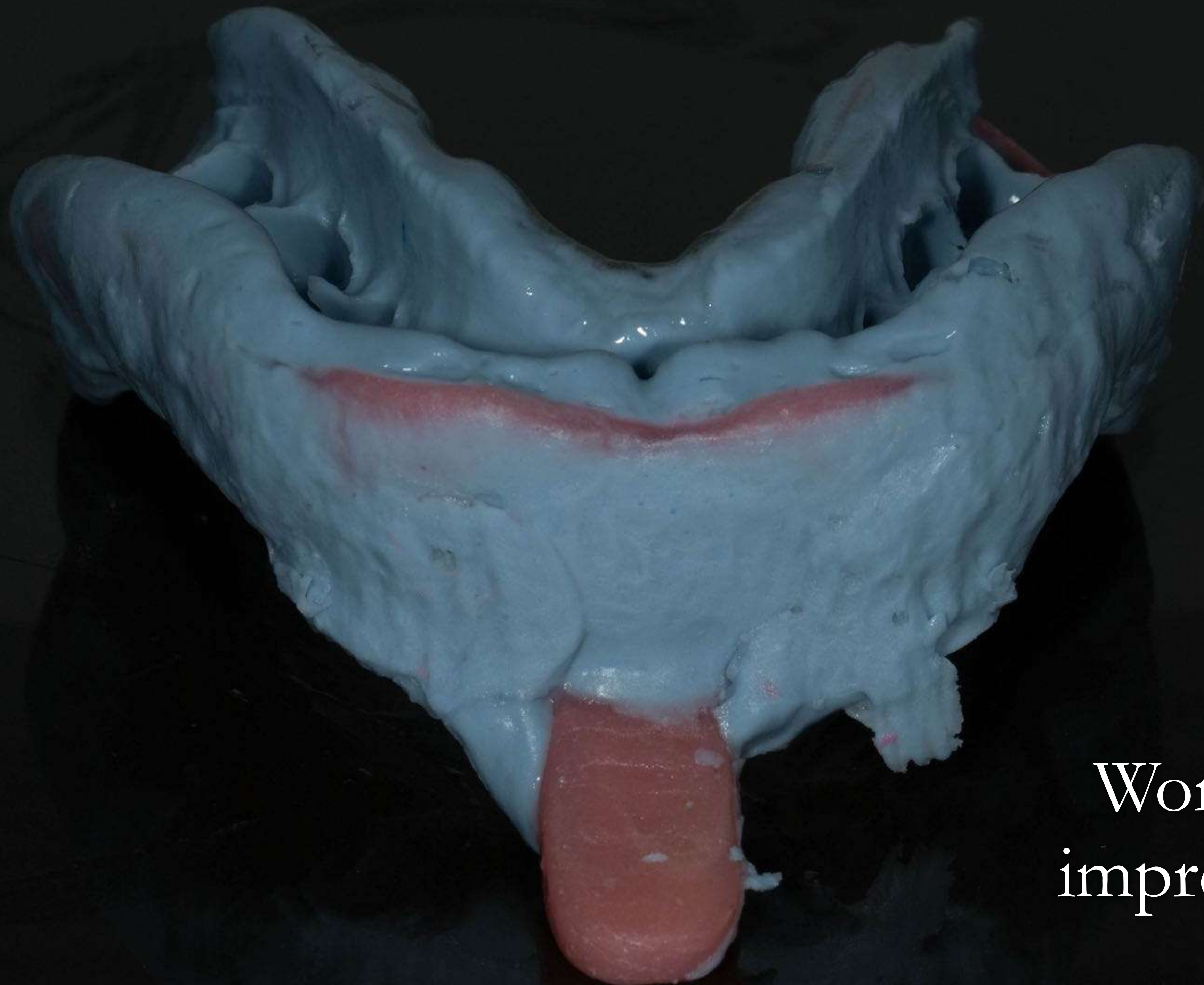Working
impression

Futar D

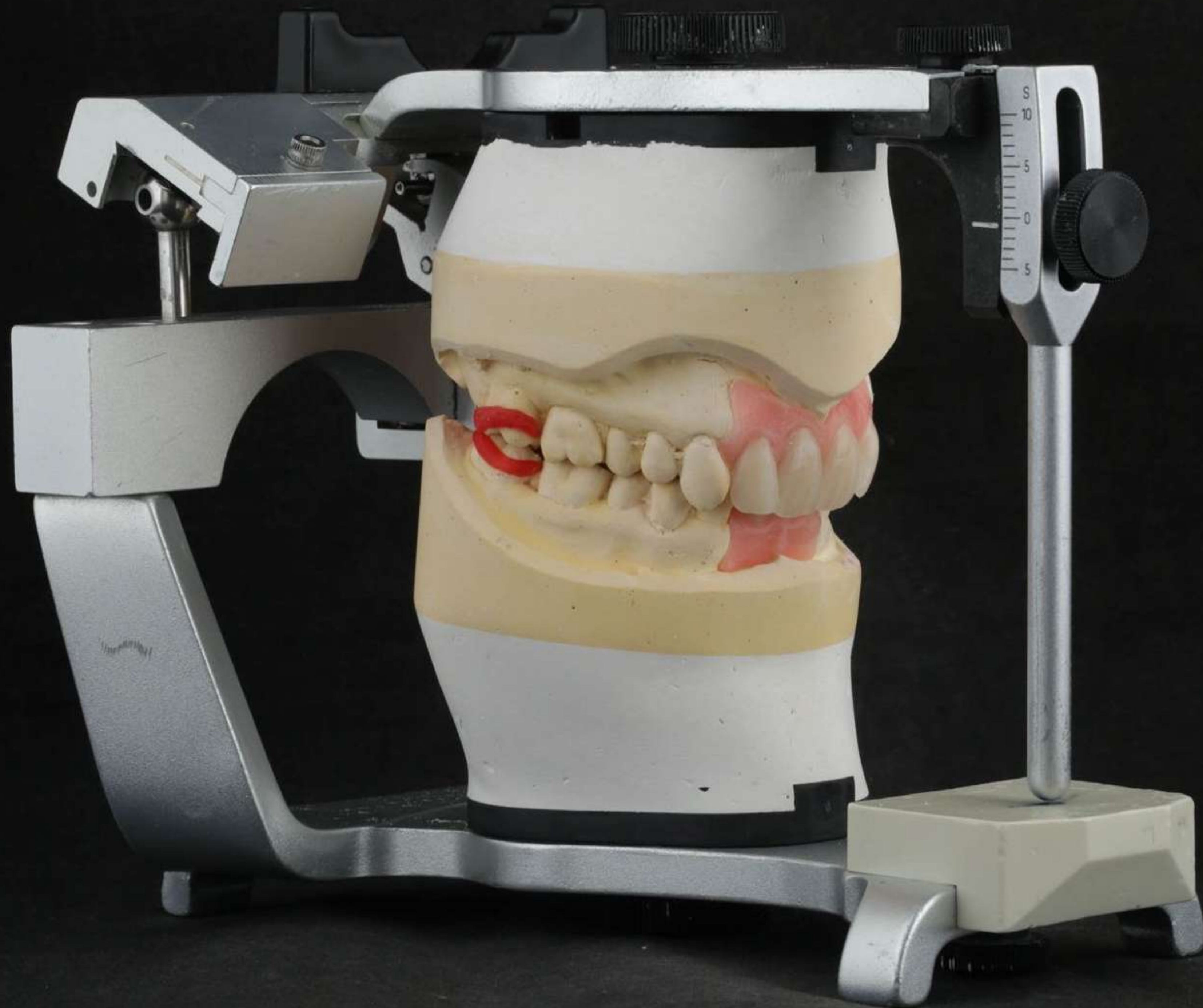

Working
impression



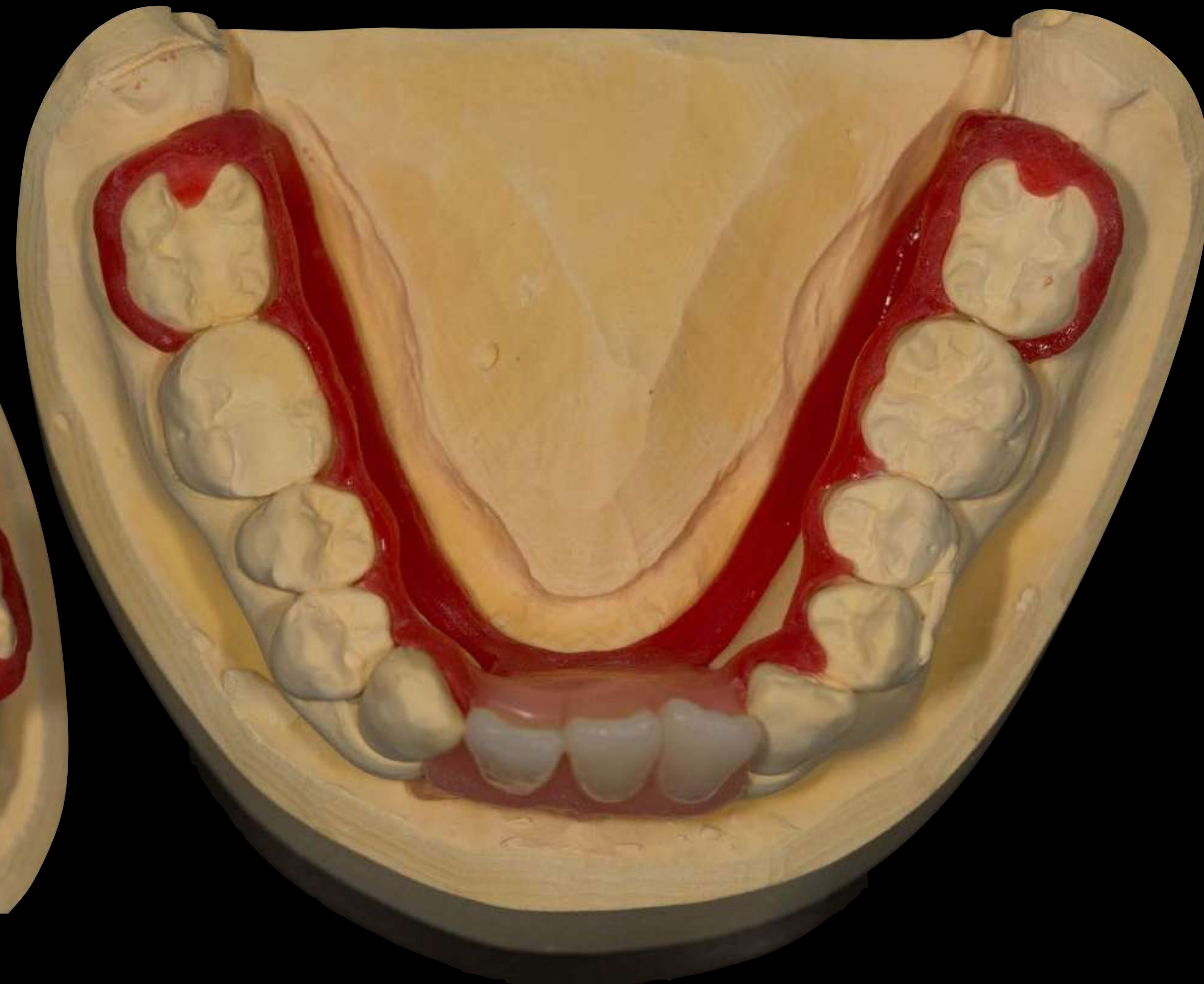
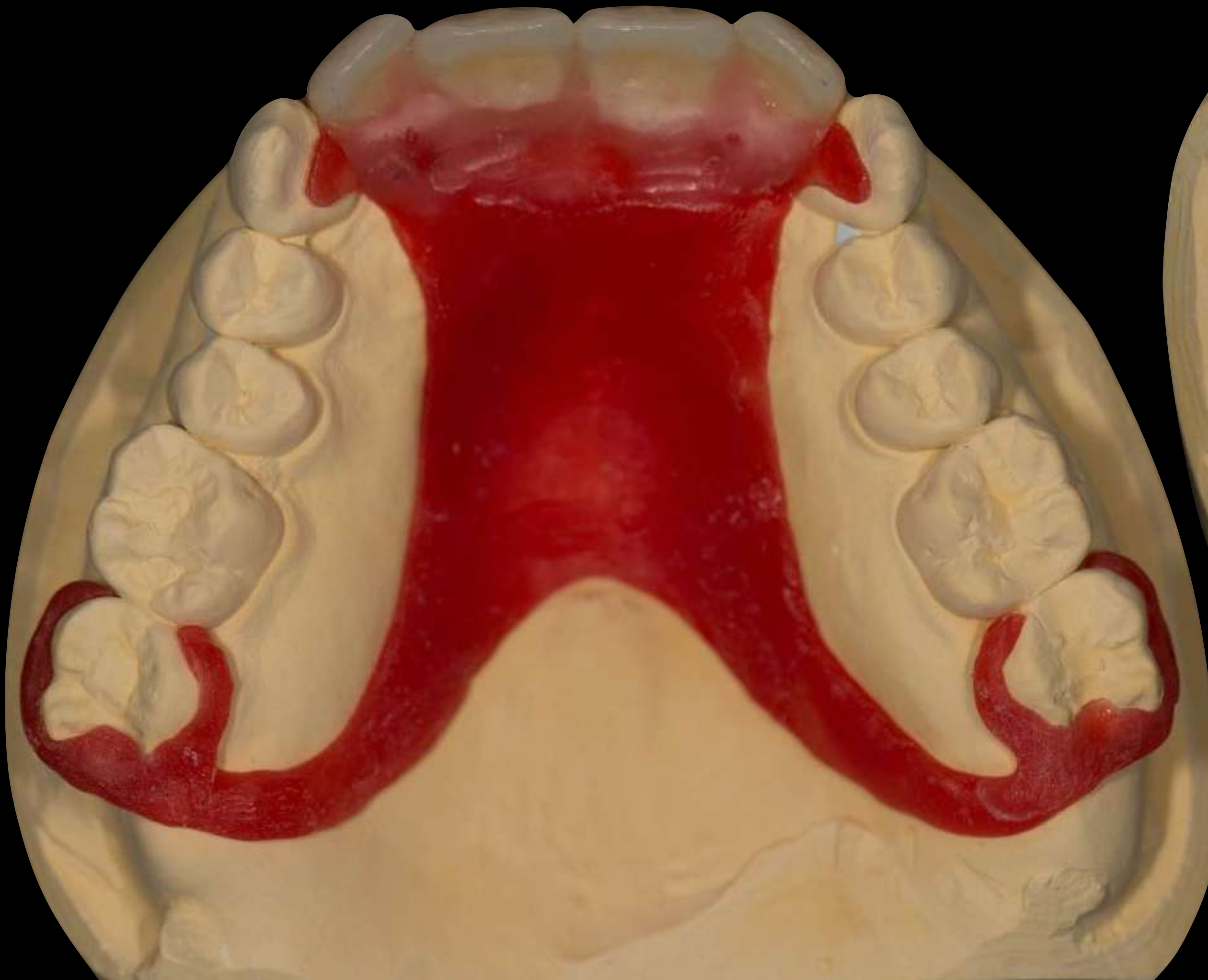

Working
impression

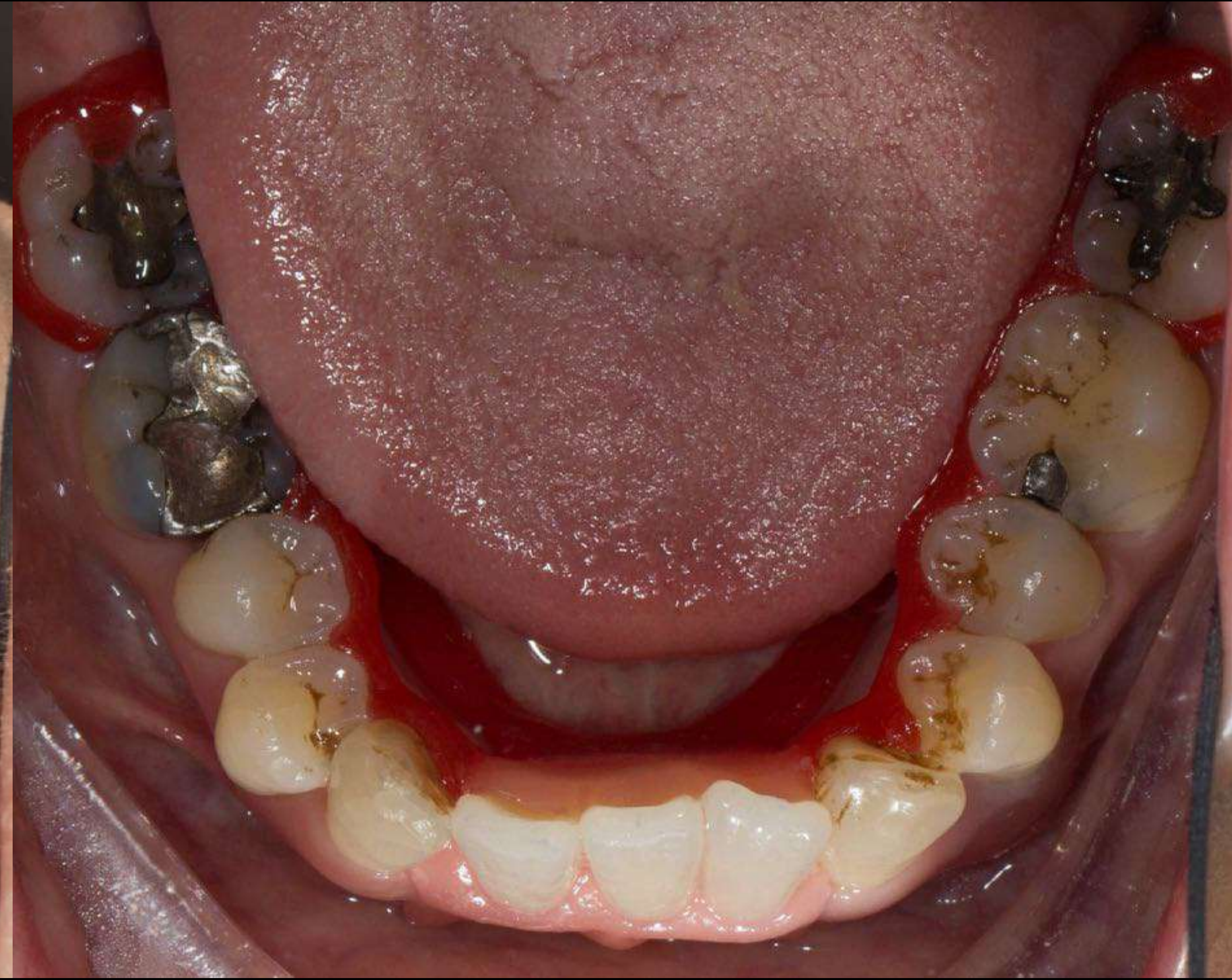
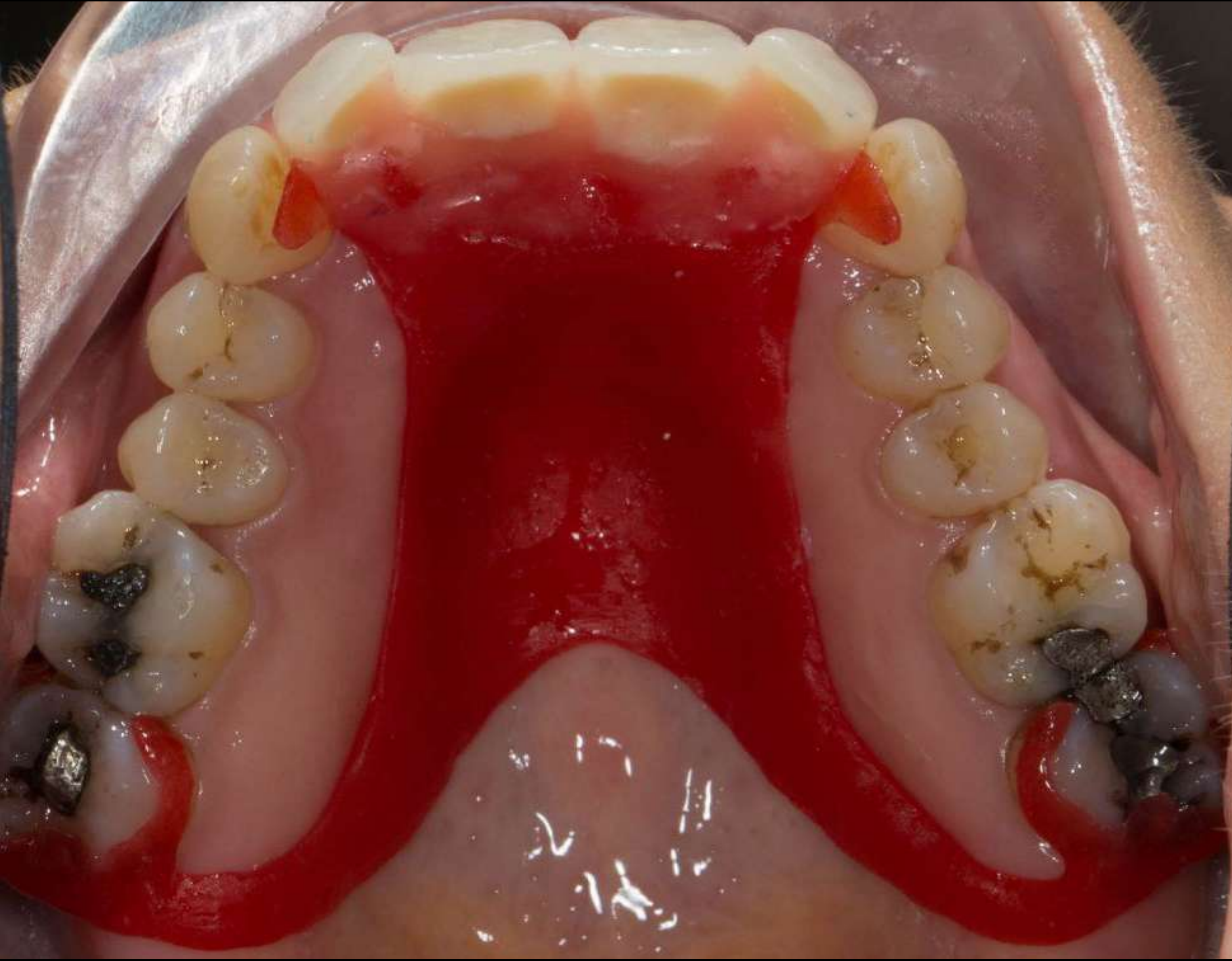


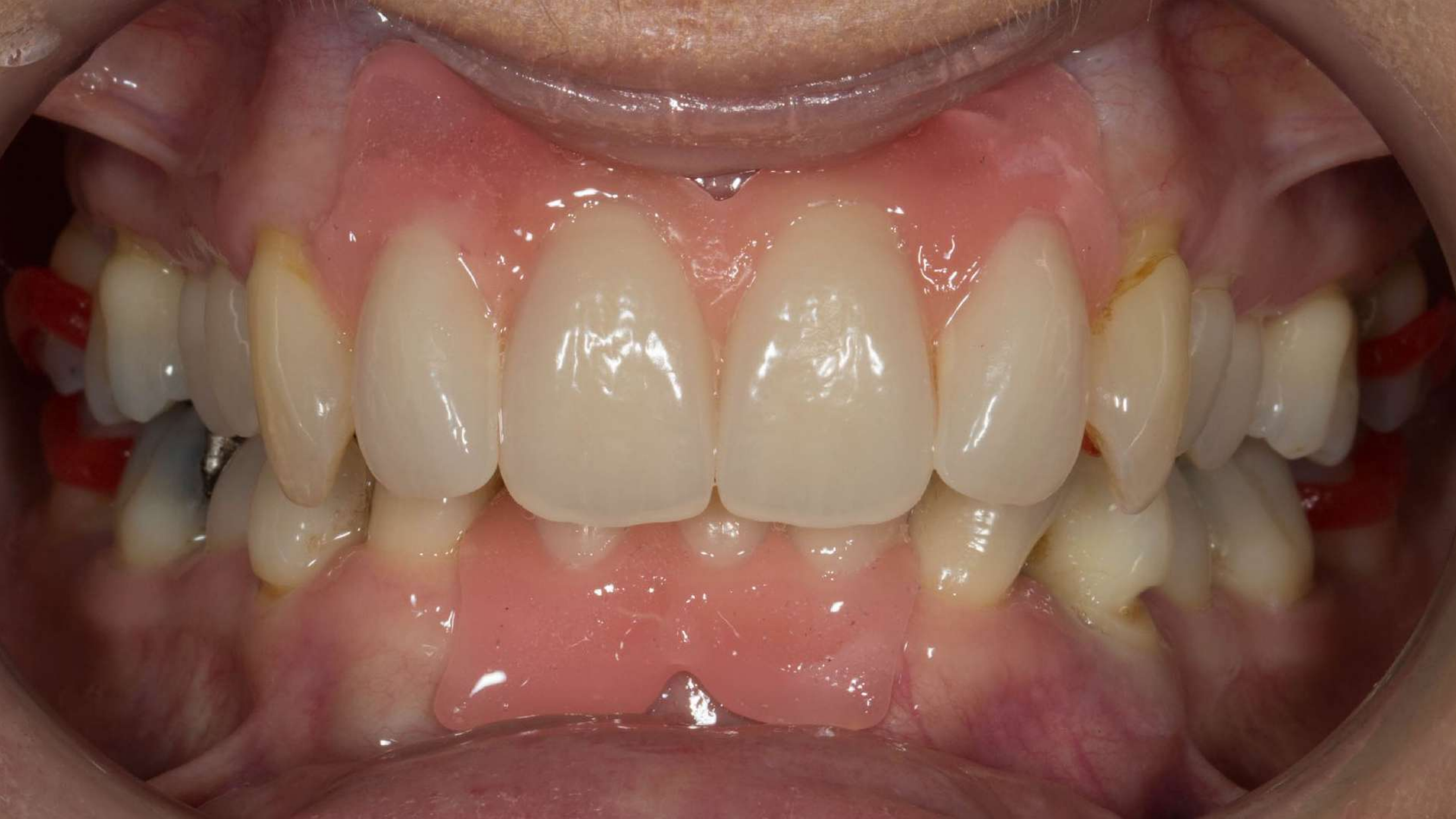Try in

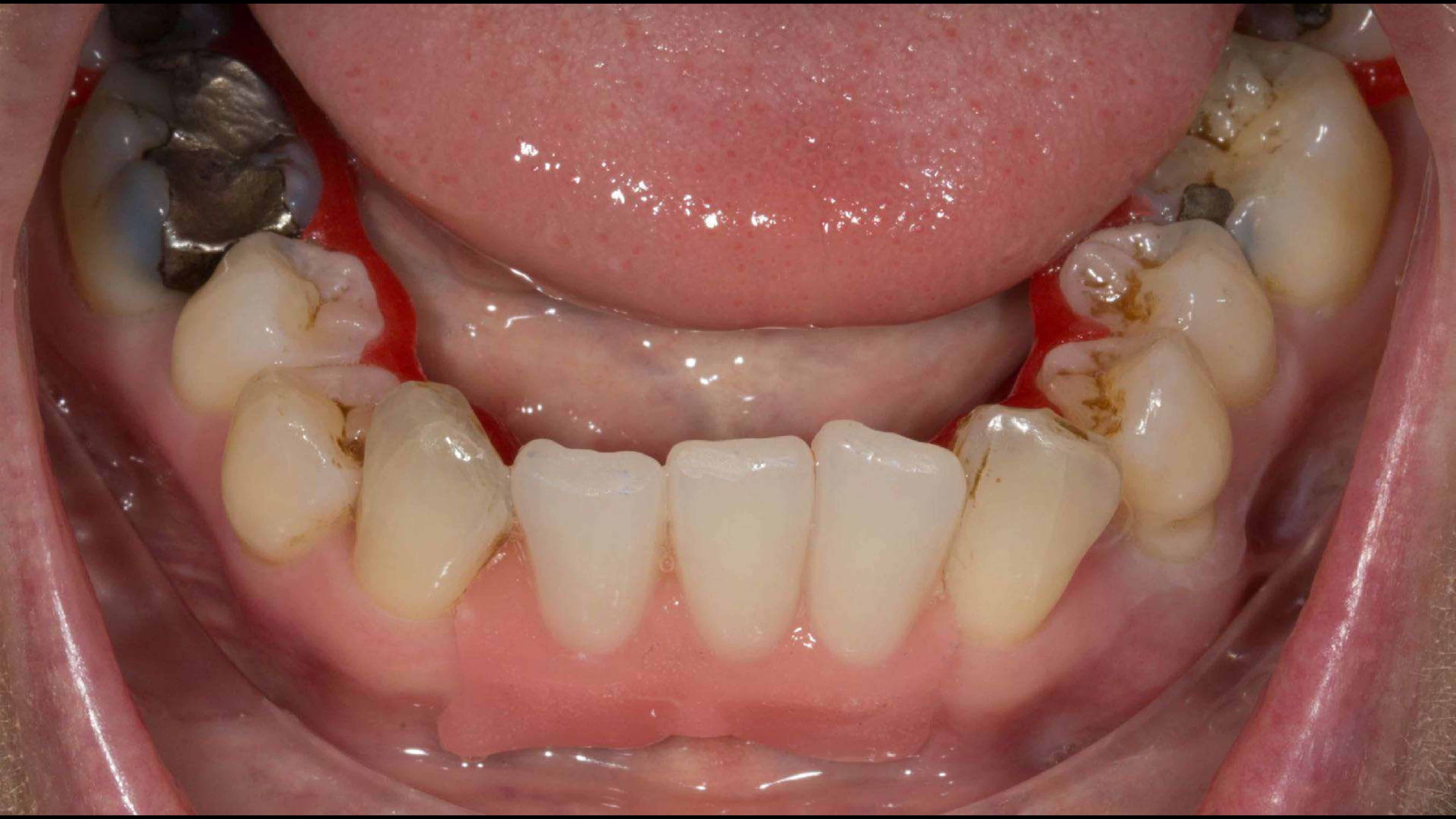Try in on duralay frameworks

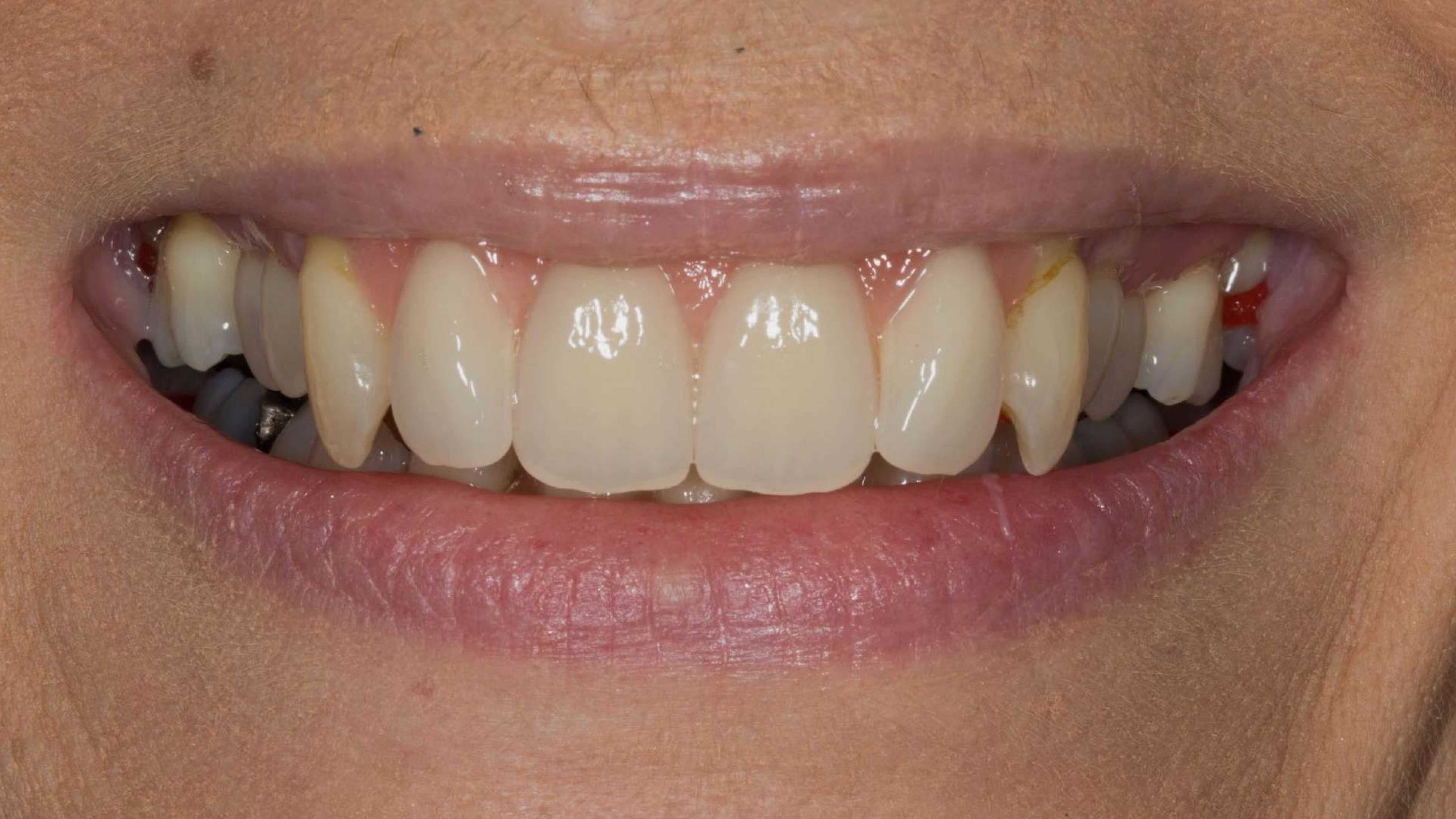


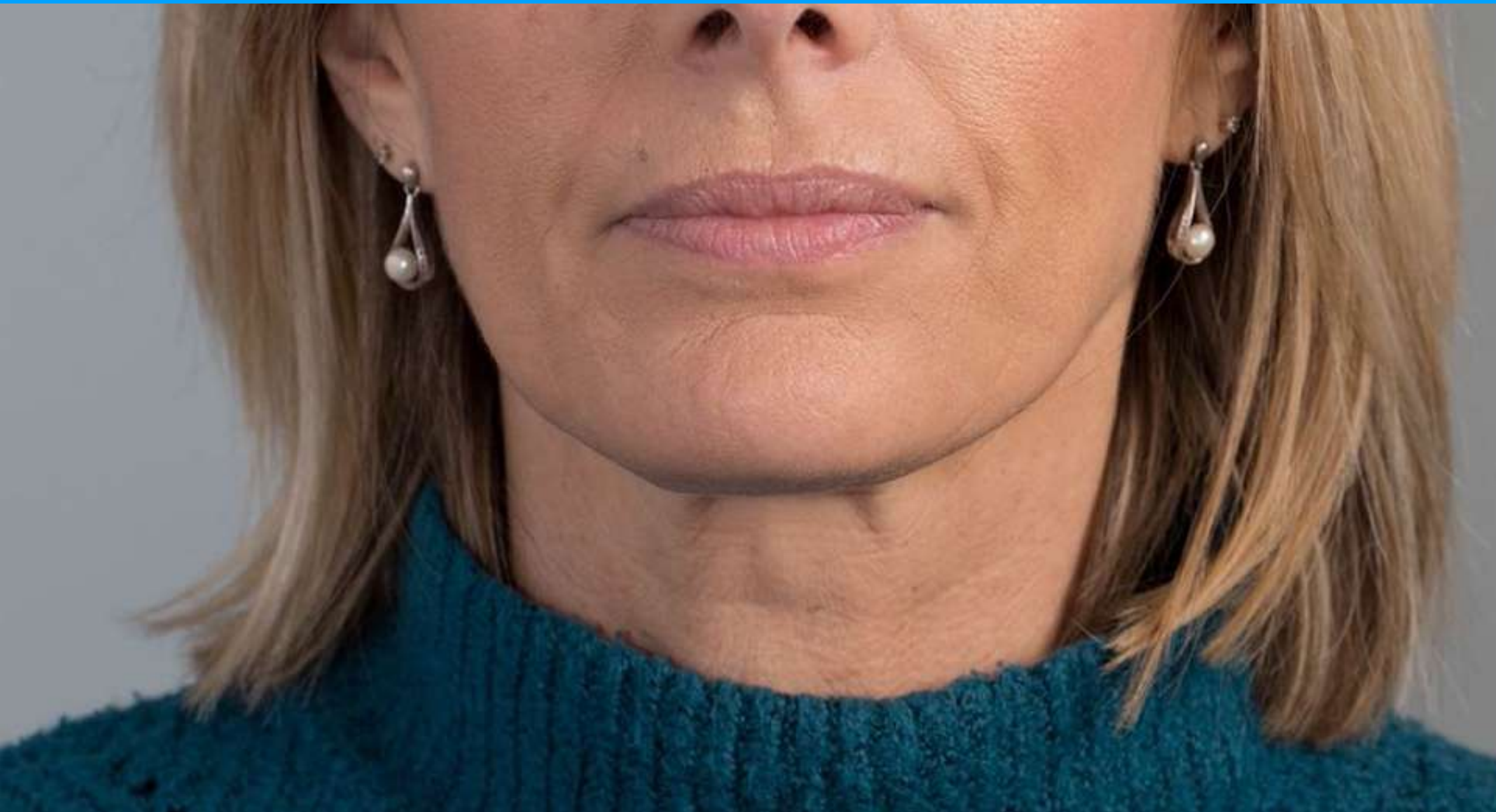Try in on duralay frameworks

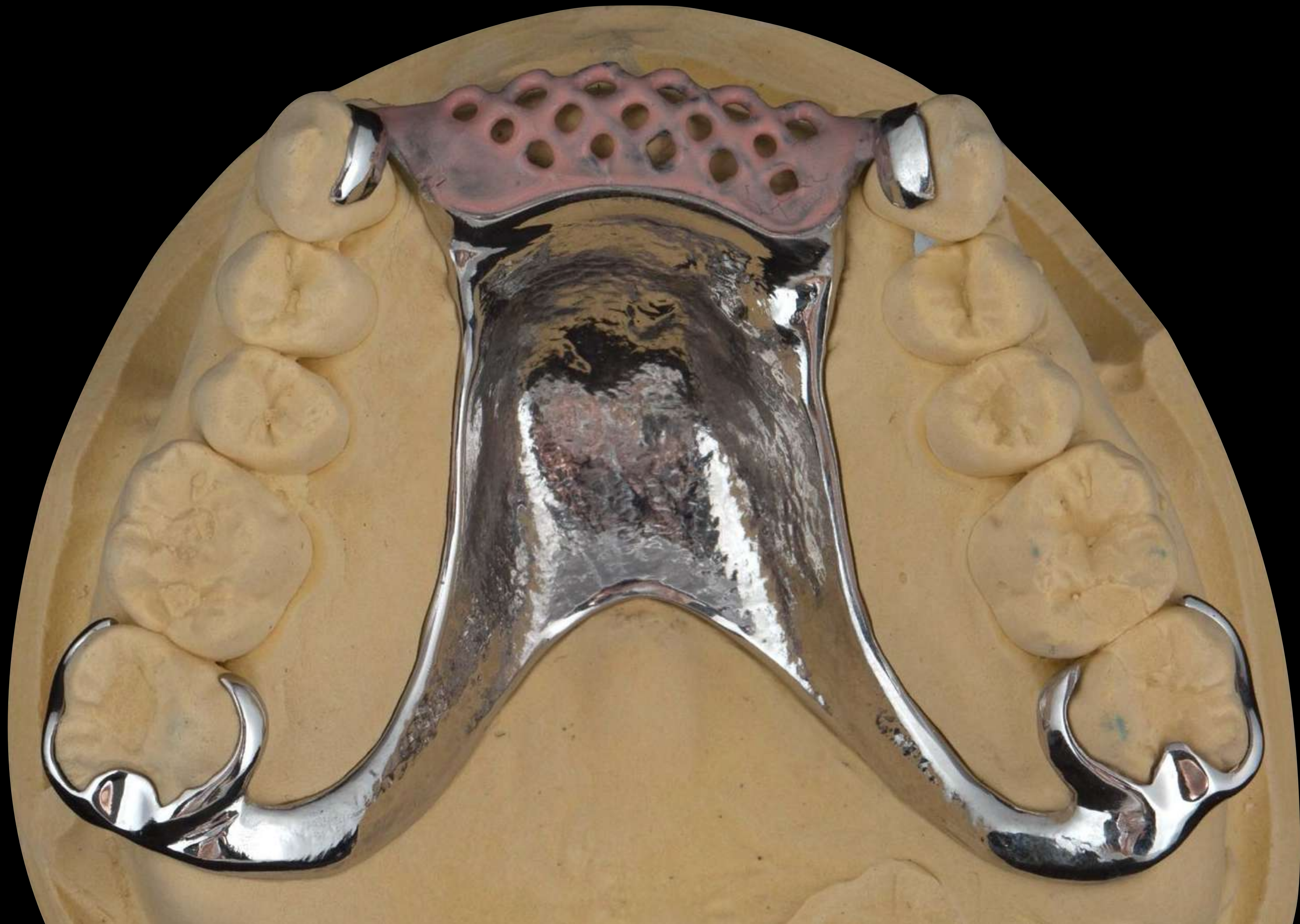


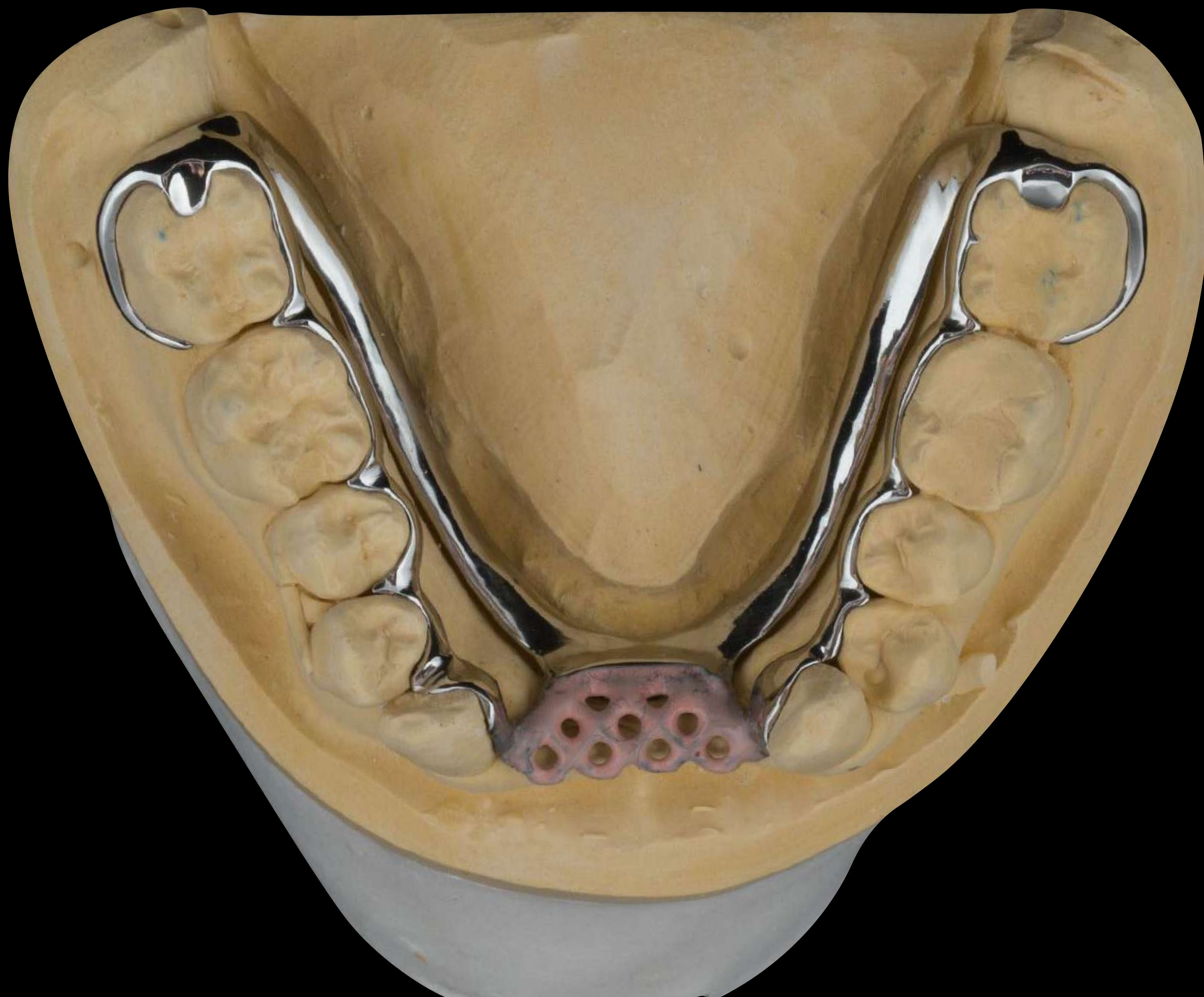


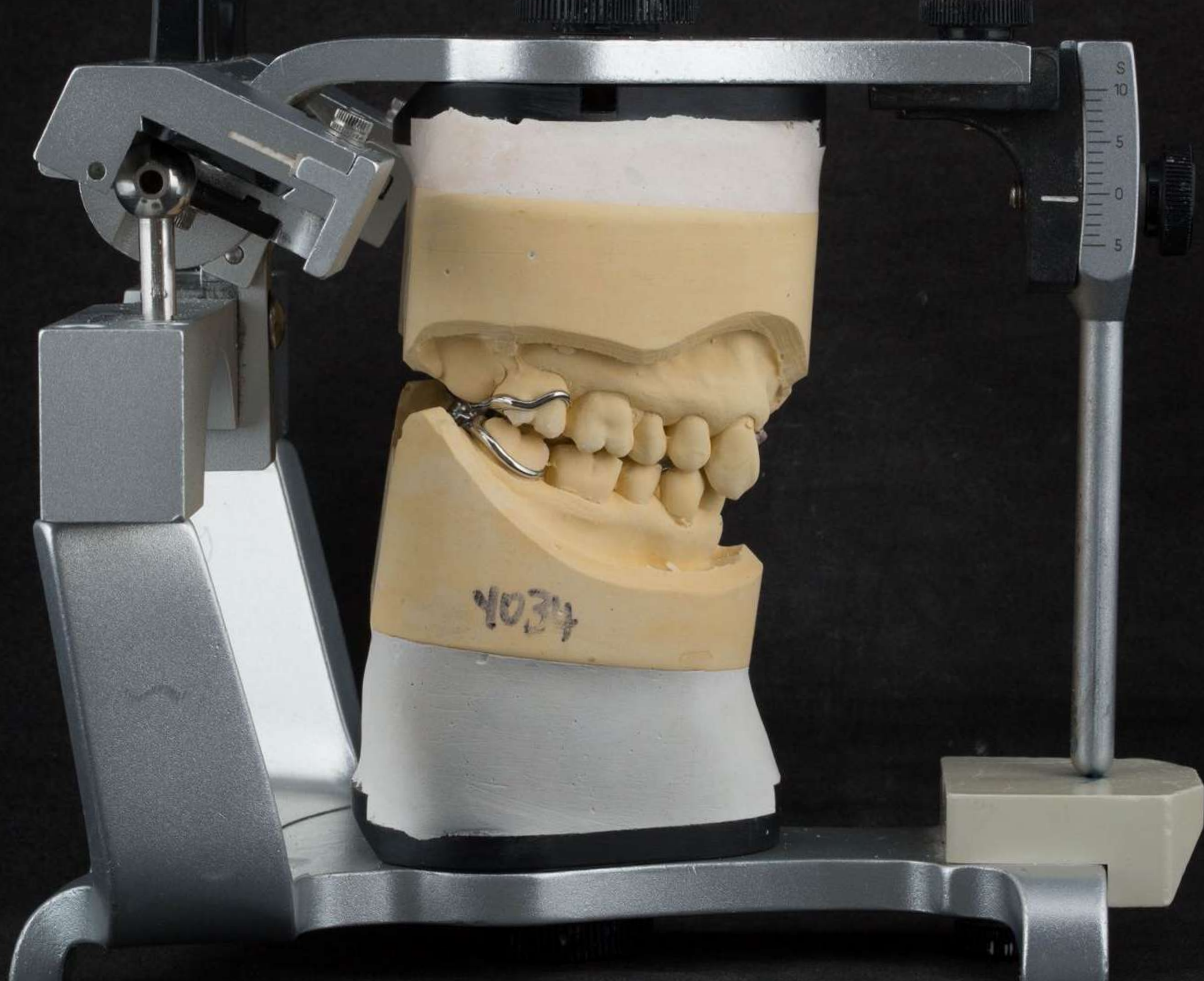


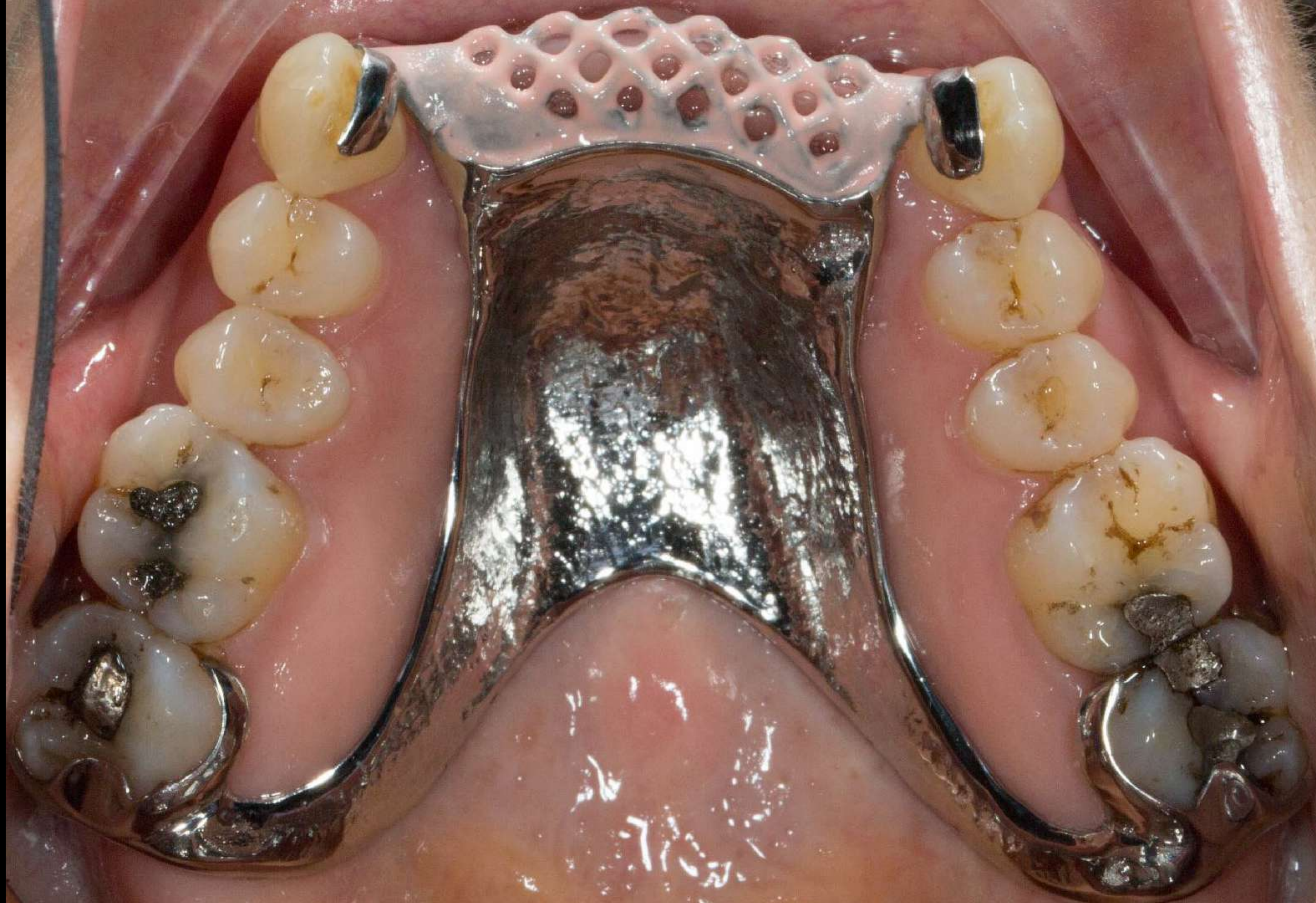

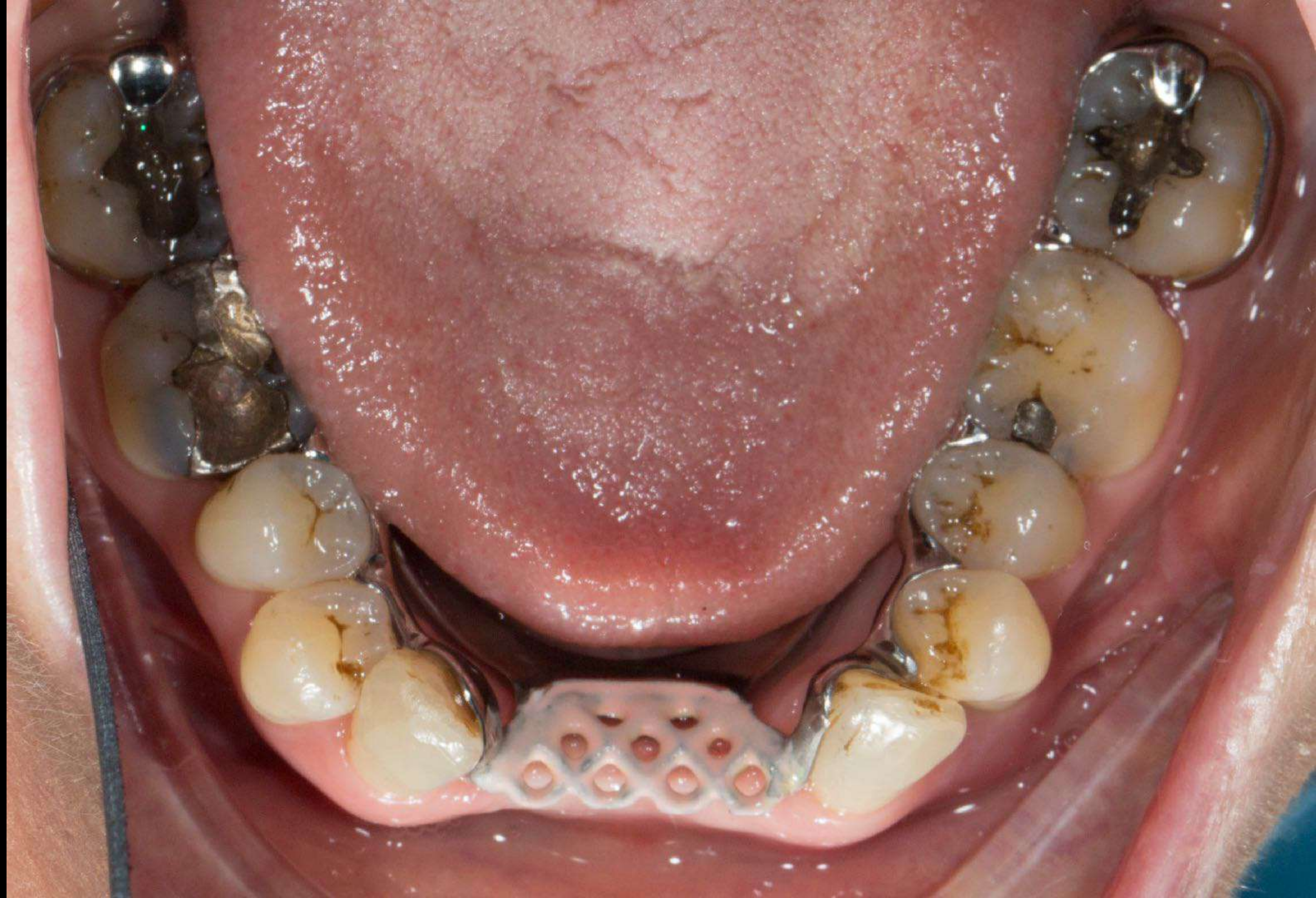



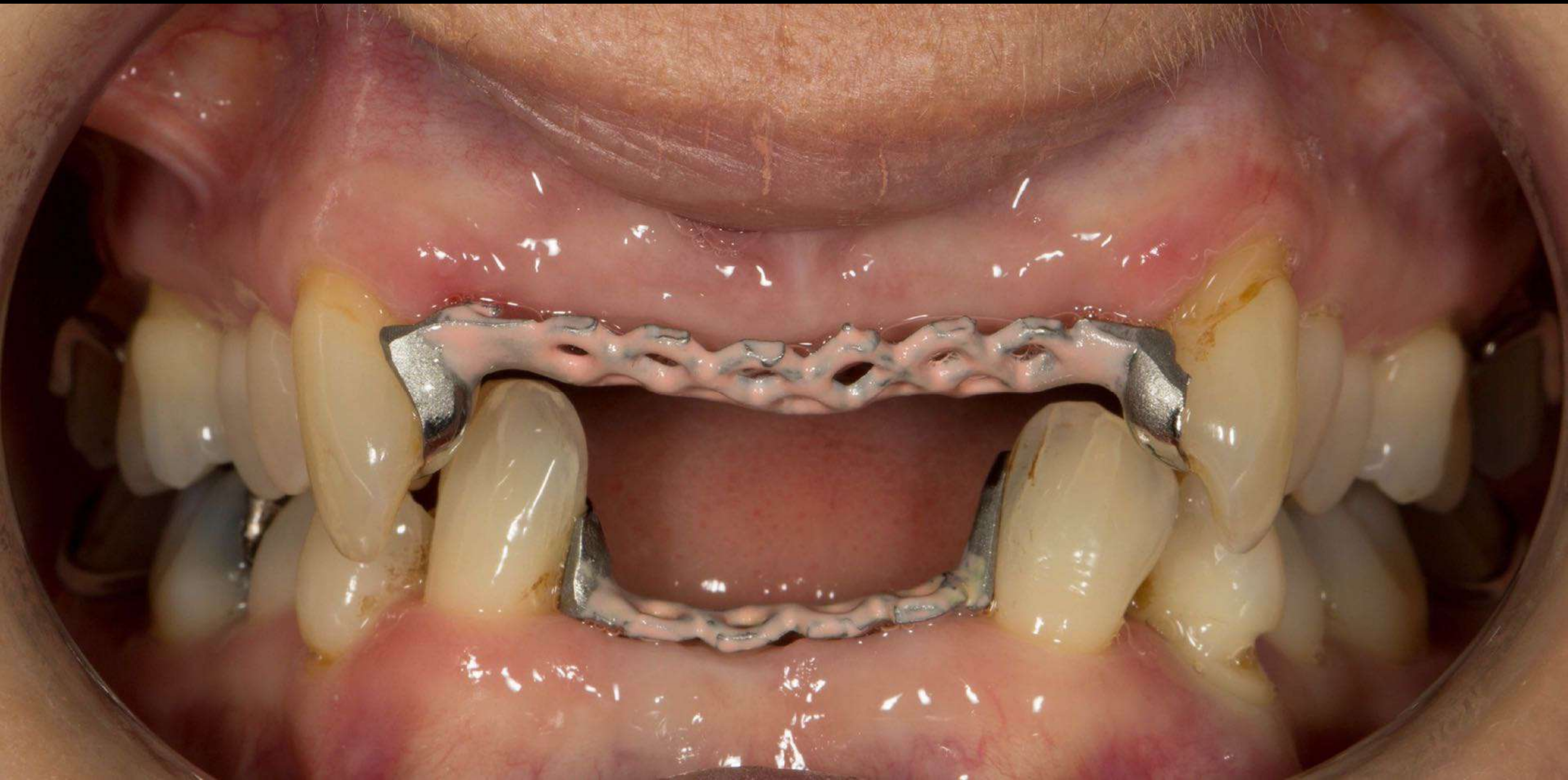


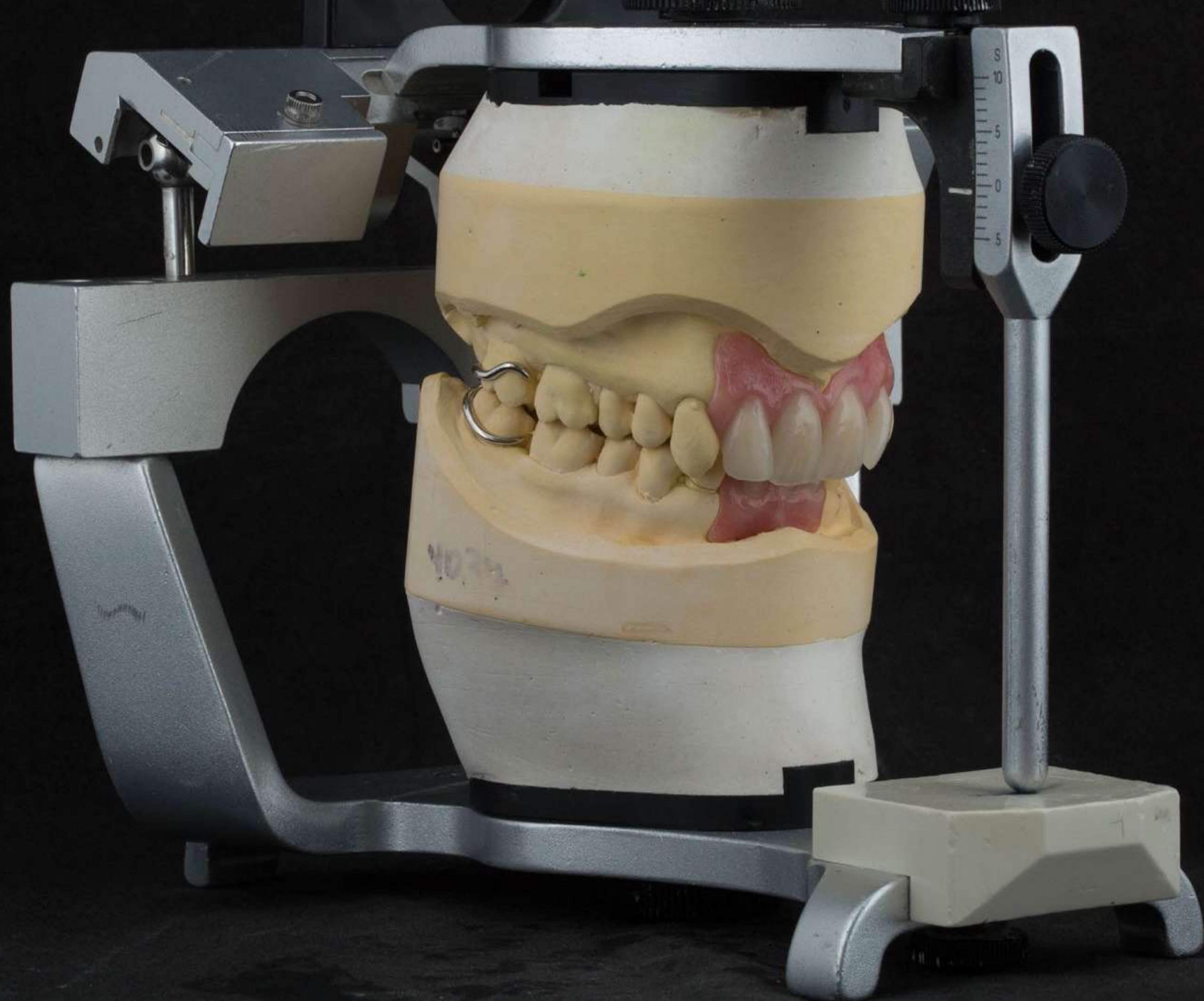

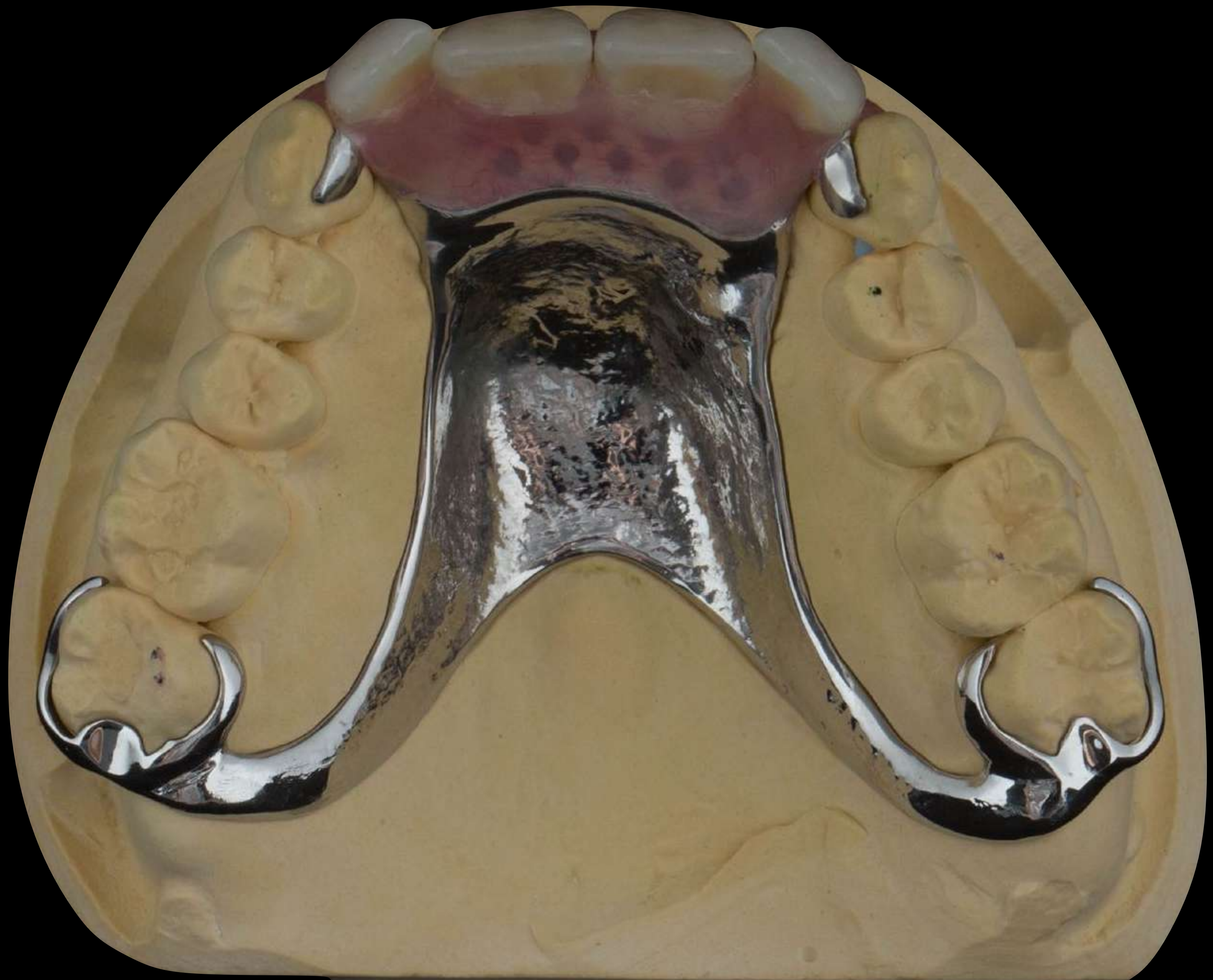





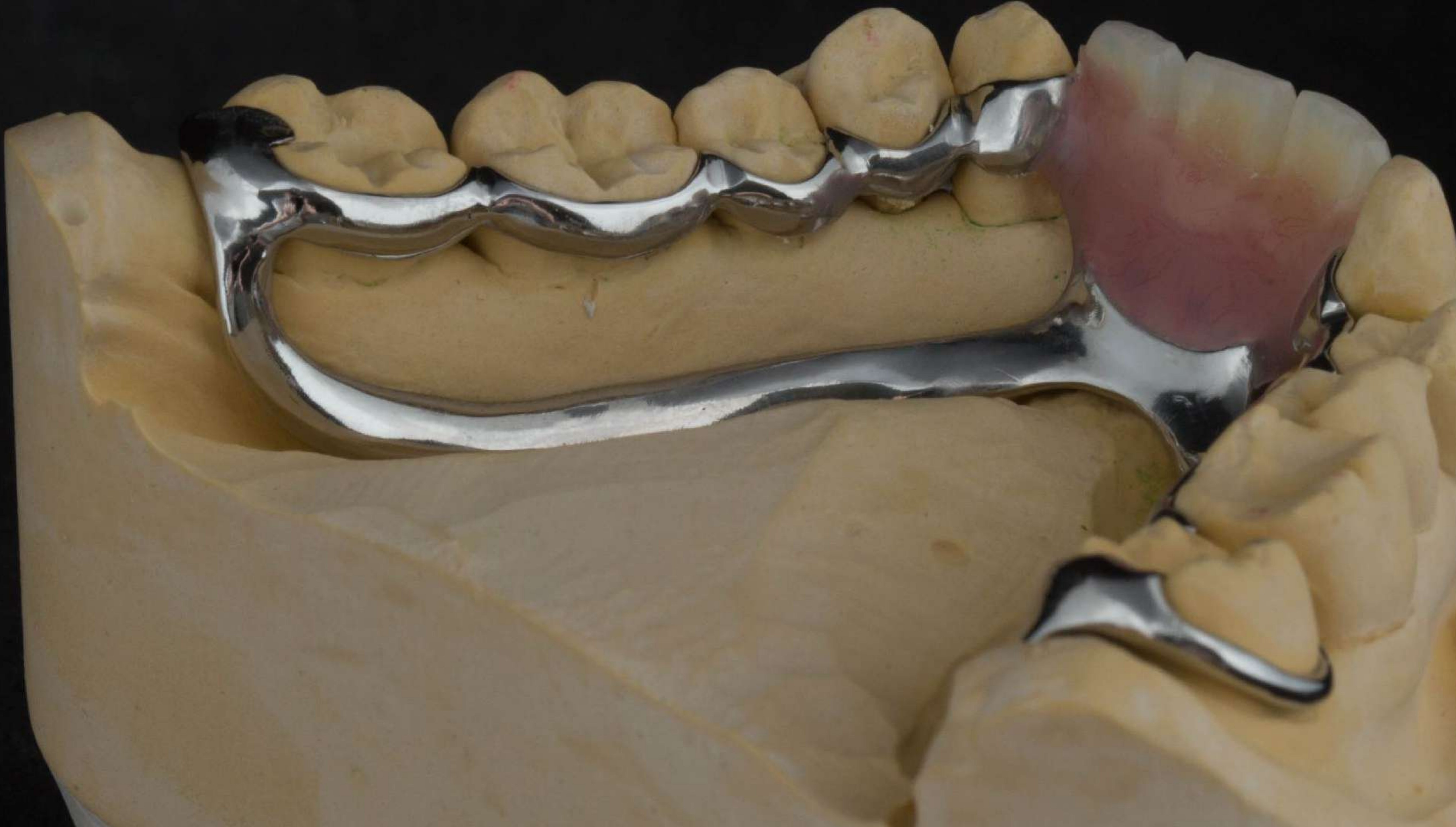


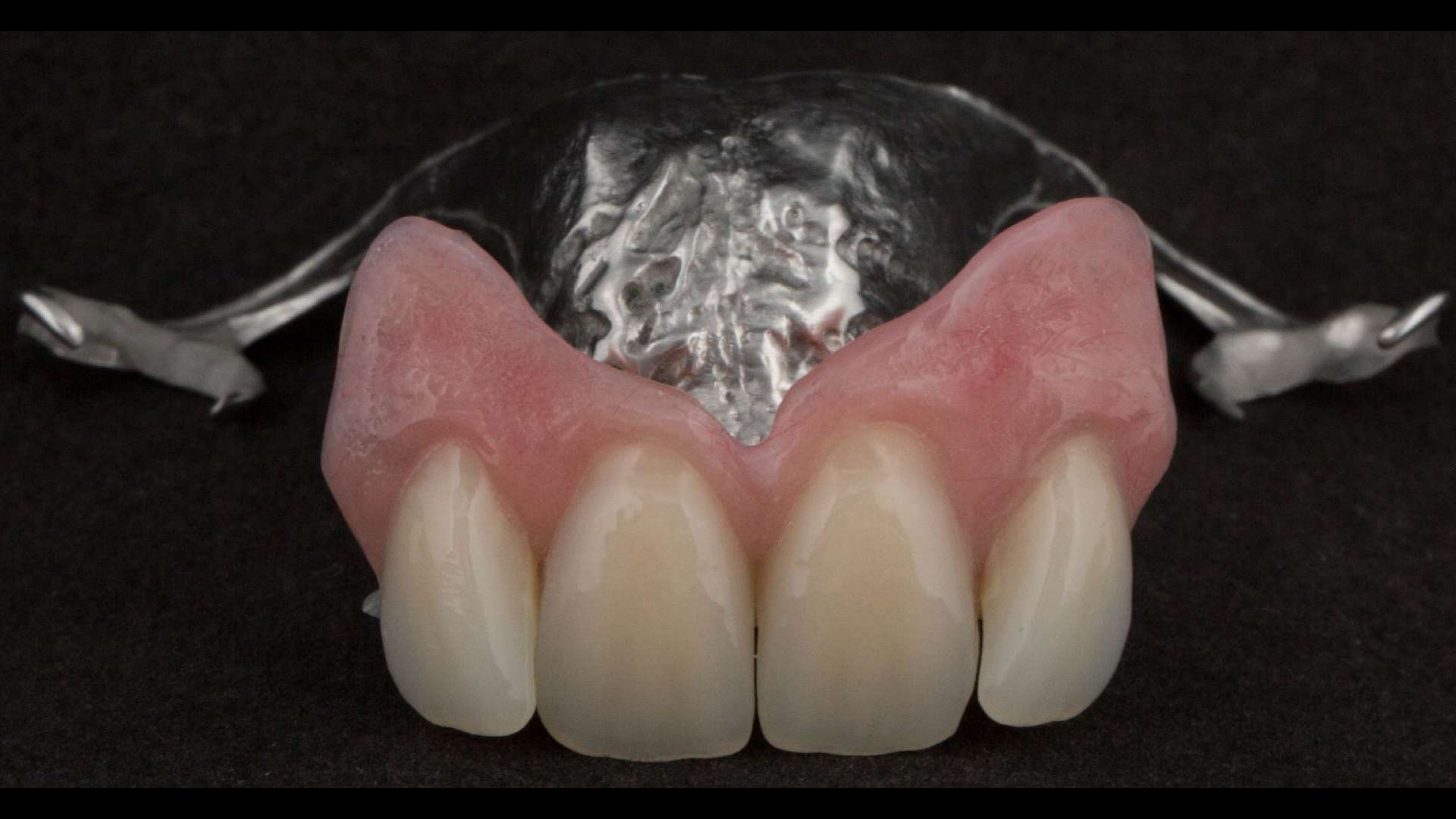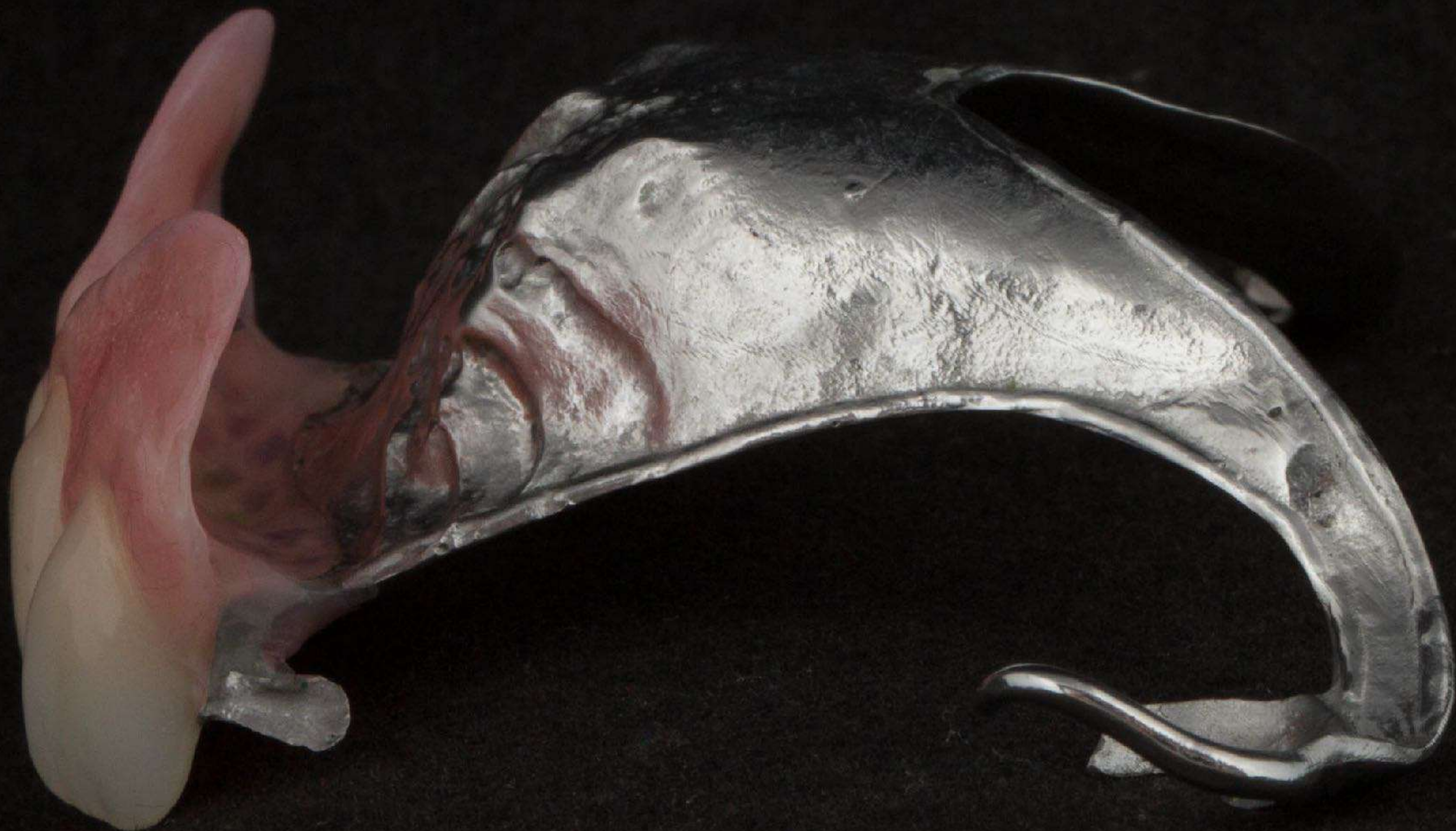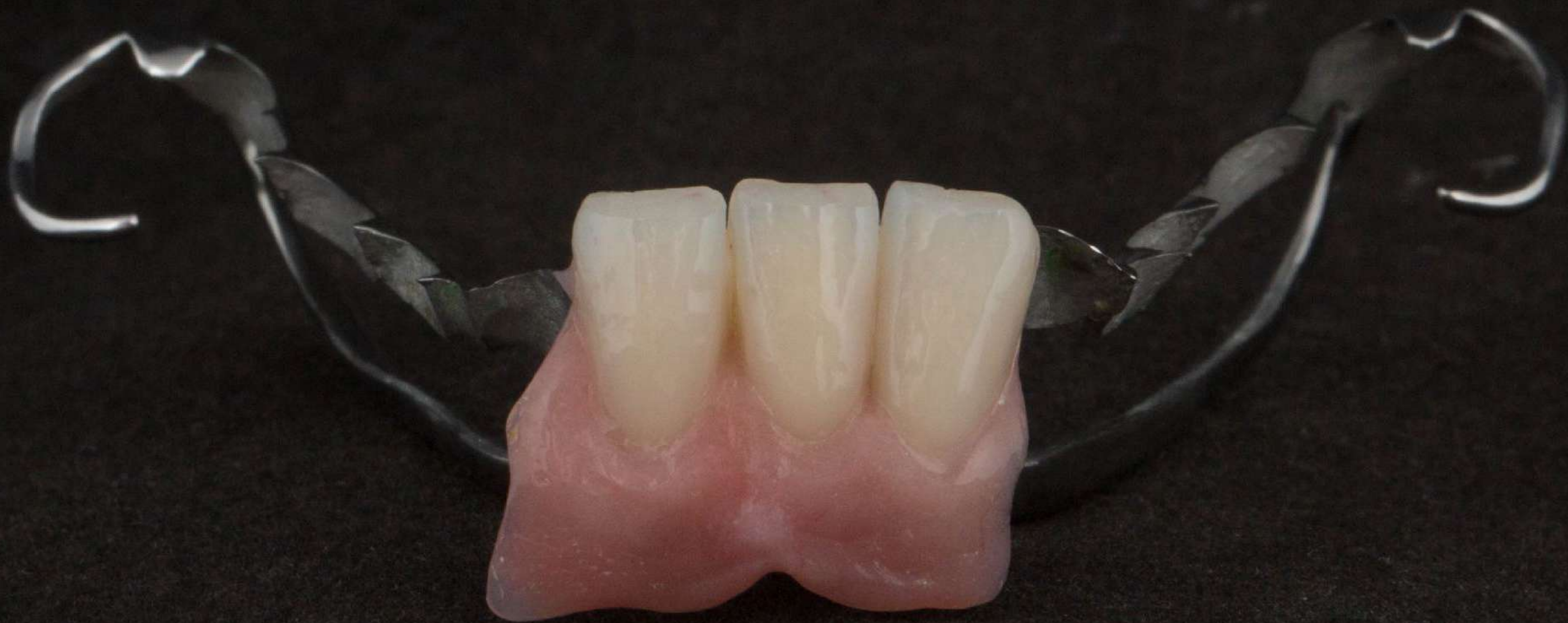Finish

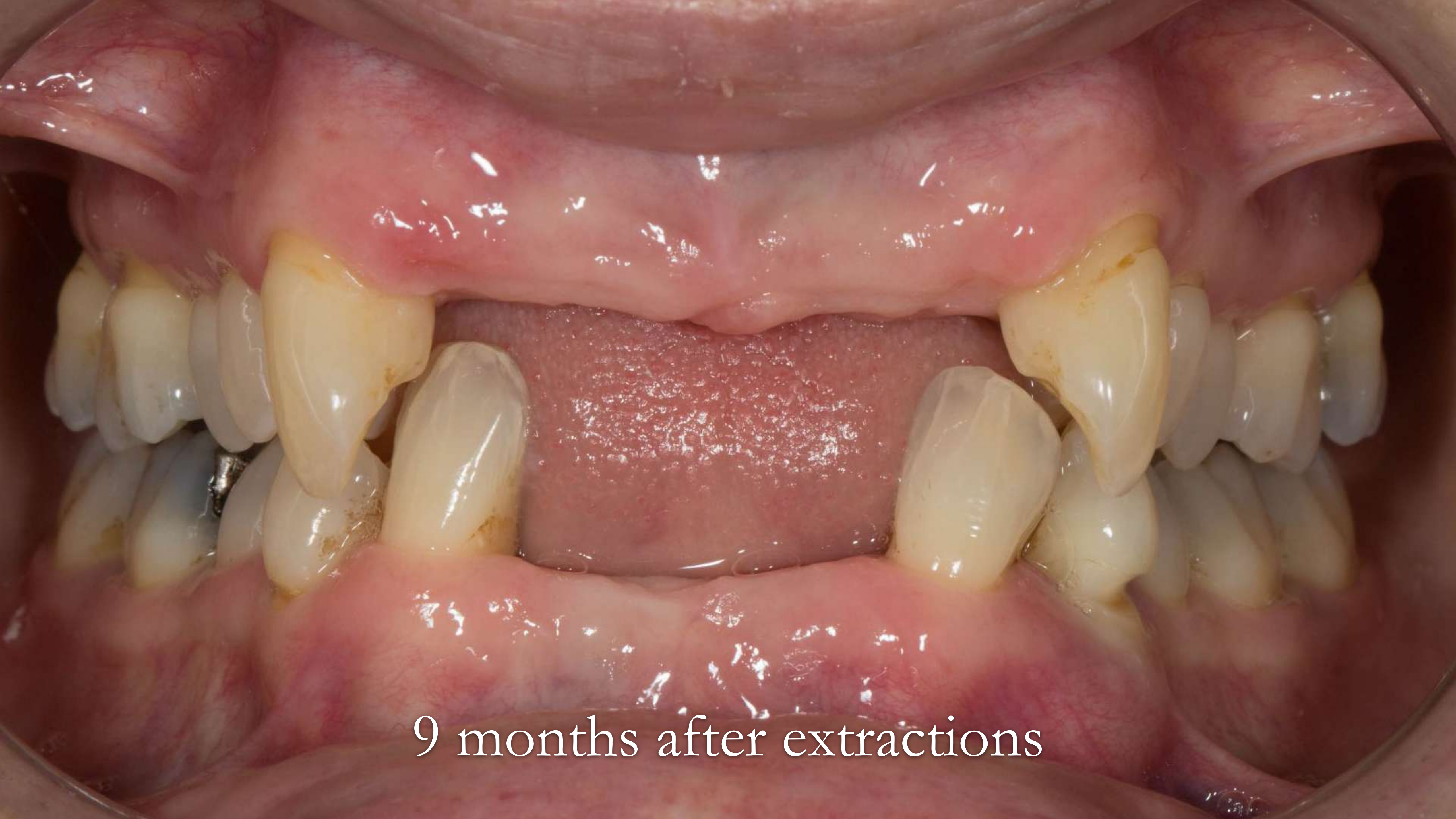




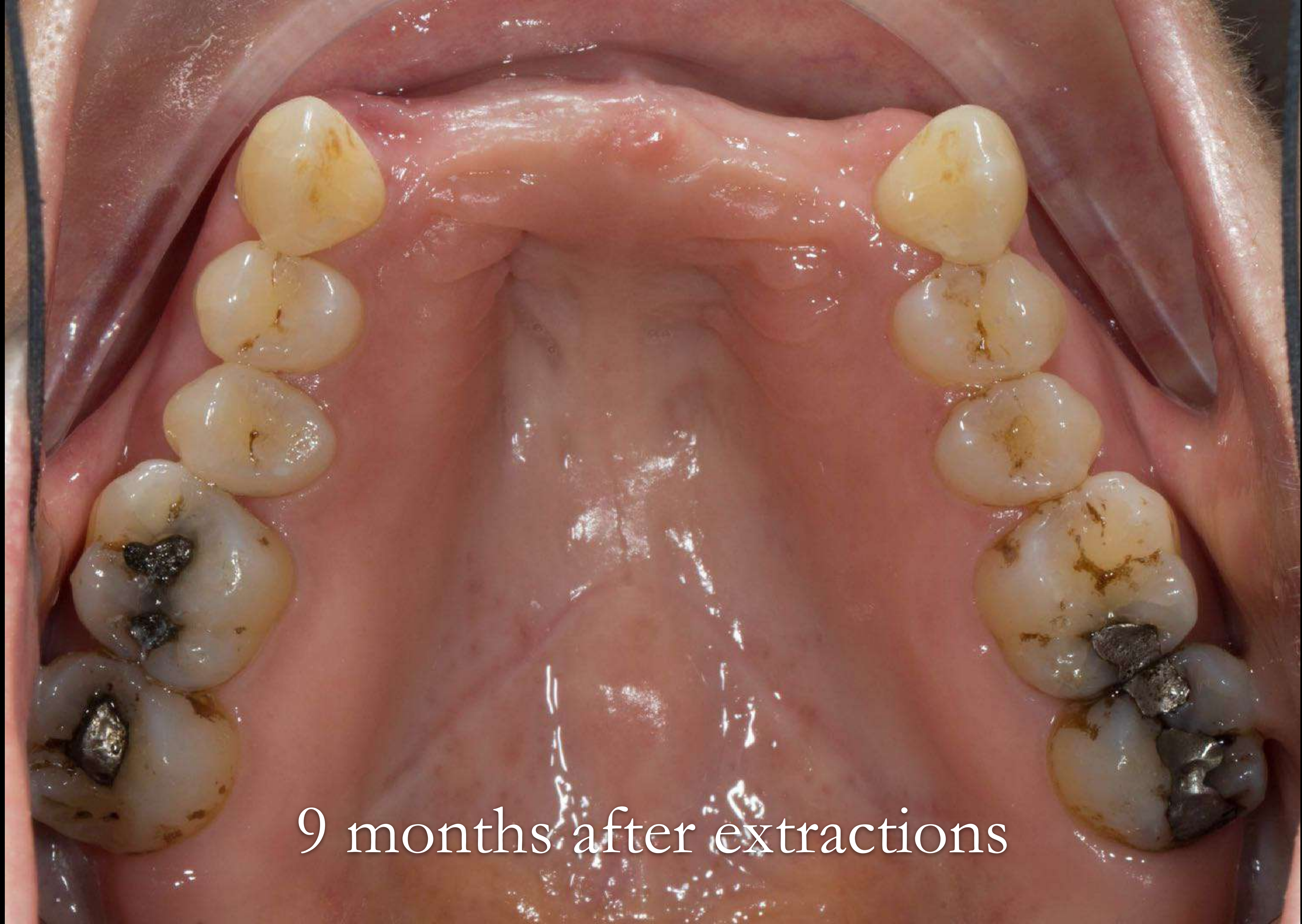






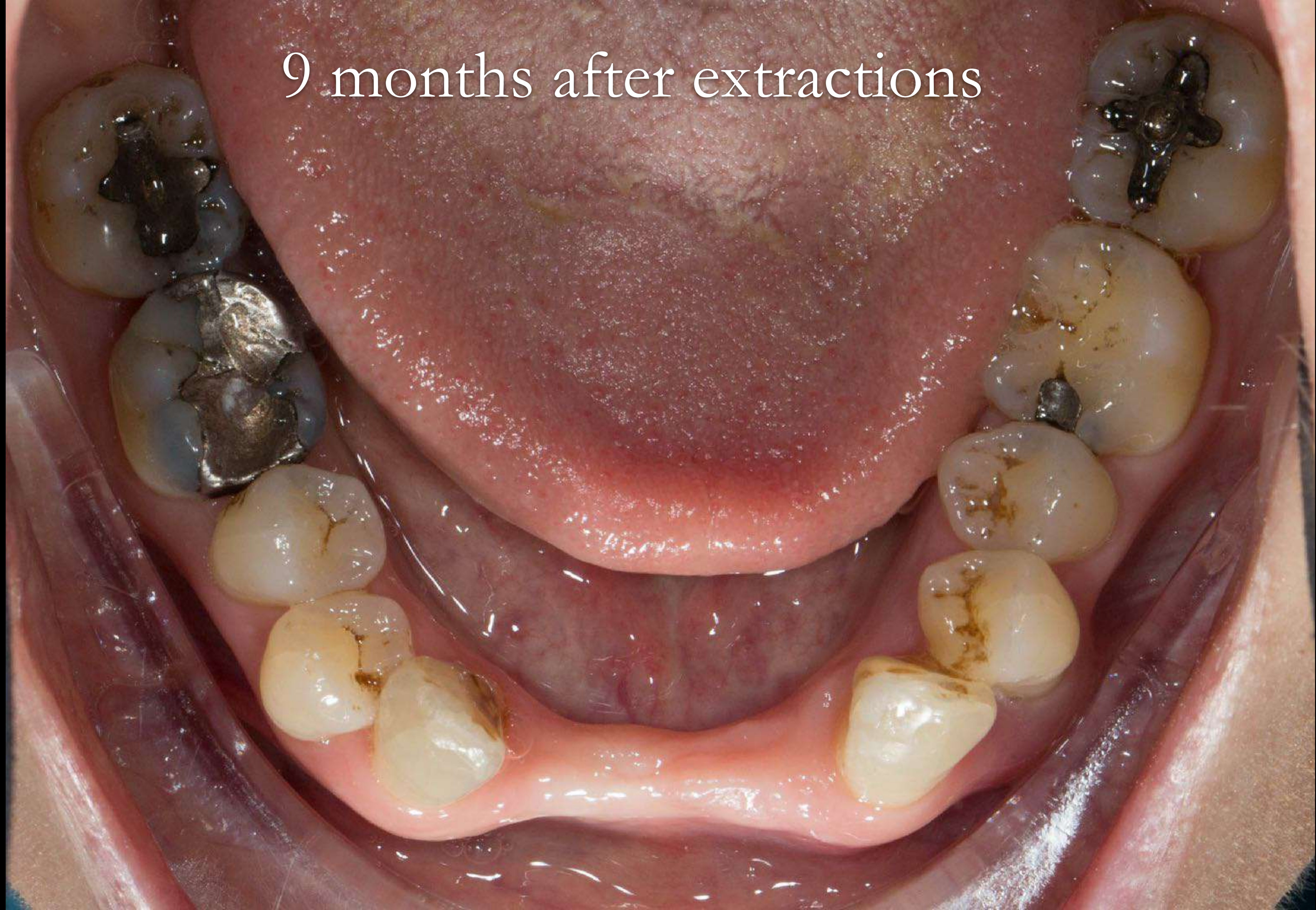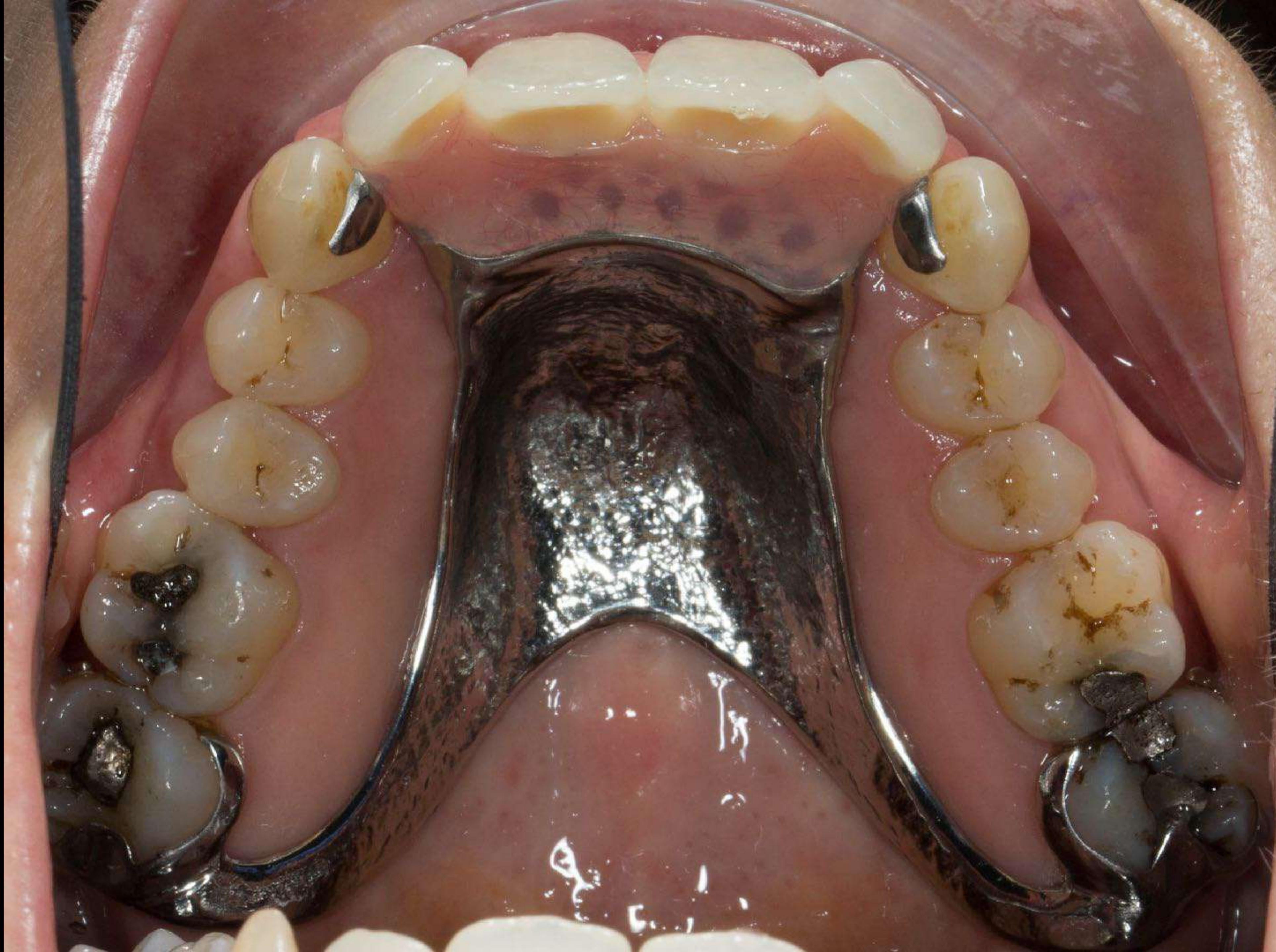9 months after extractions

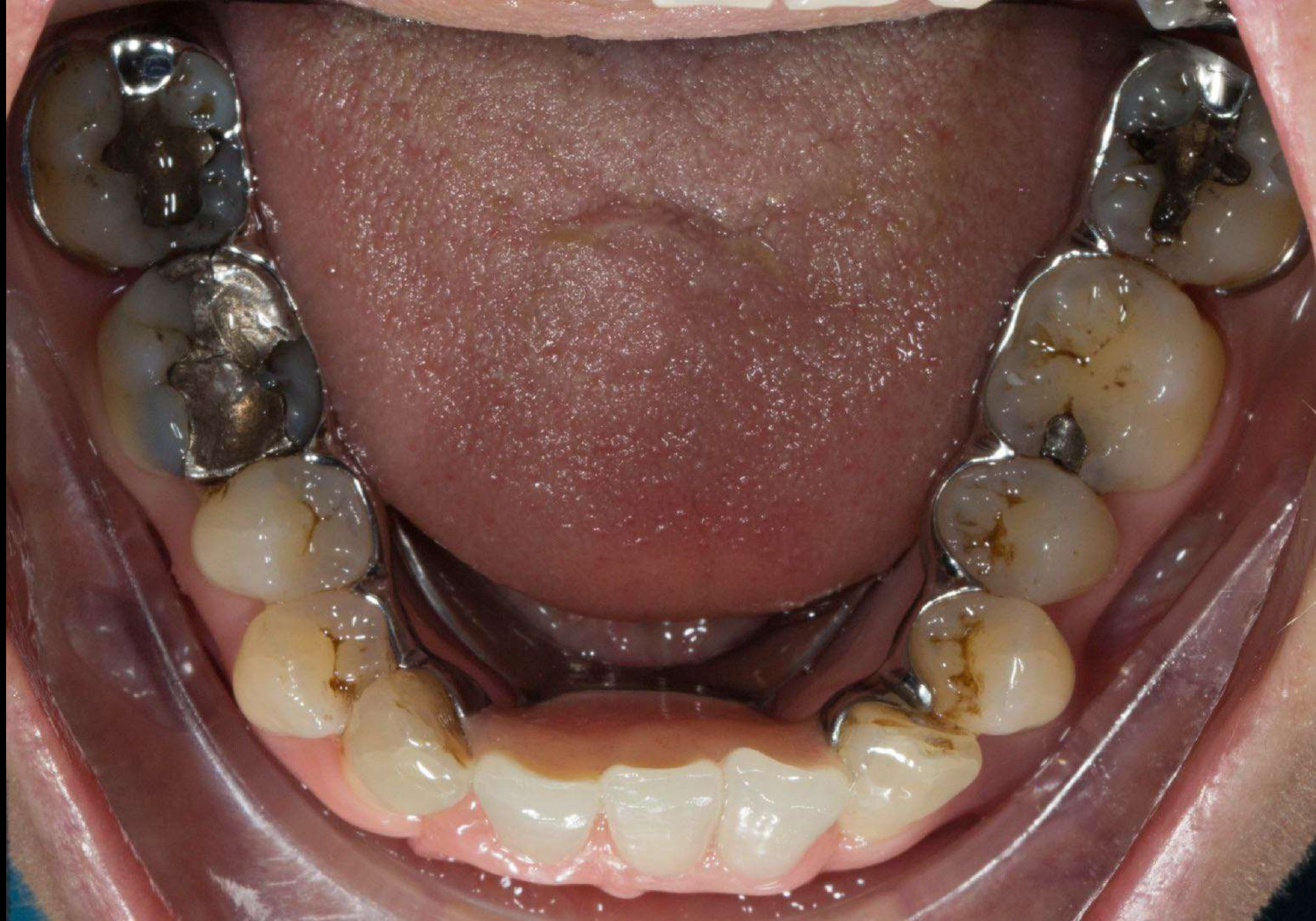


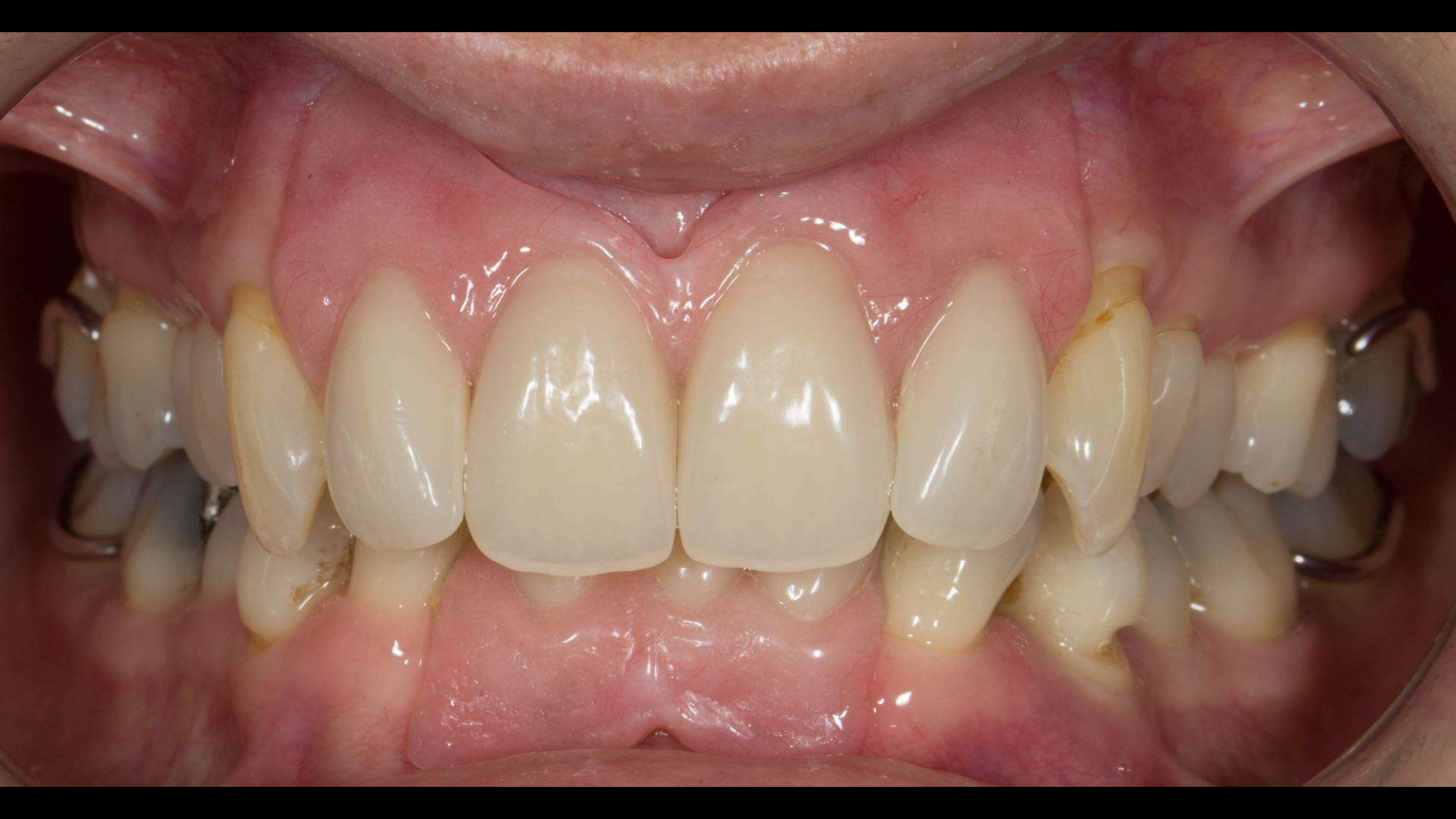9 months after extractions

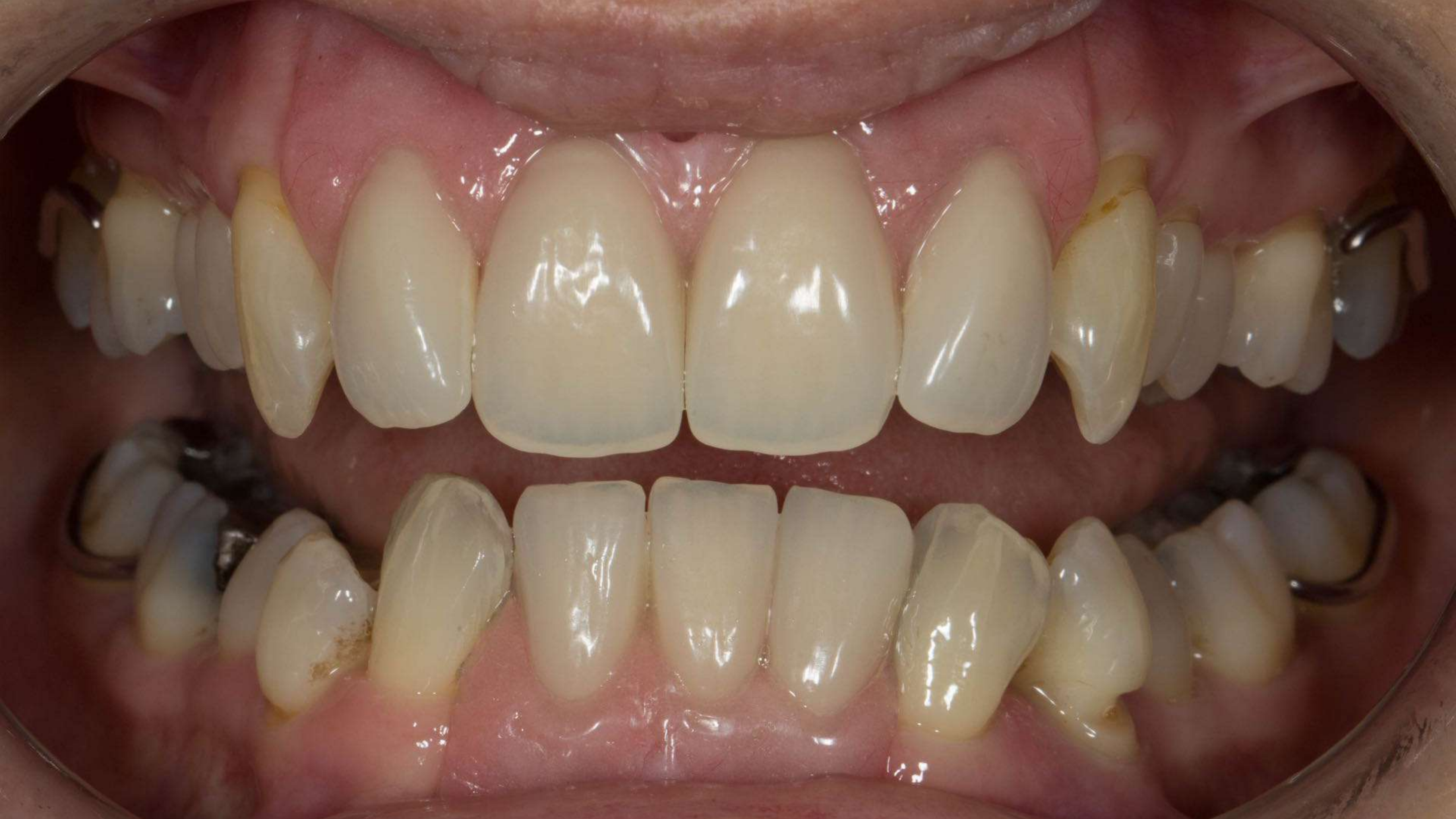9 months after extractions

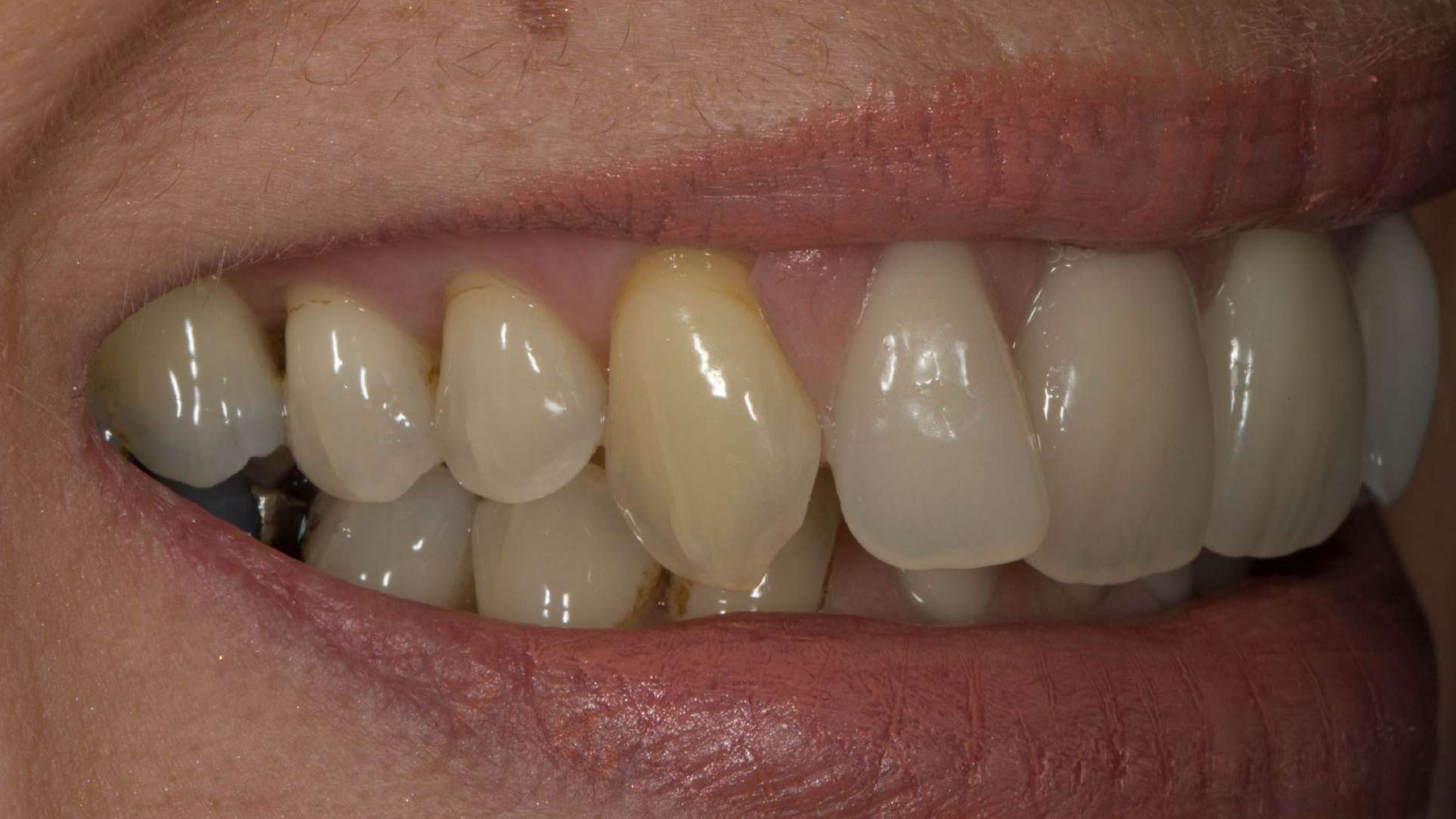


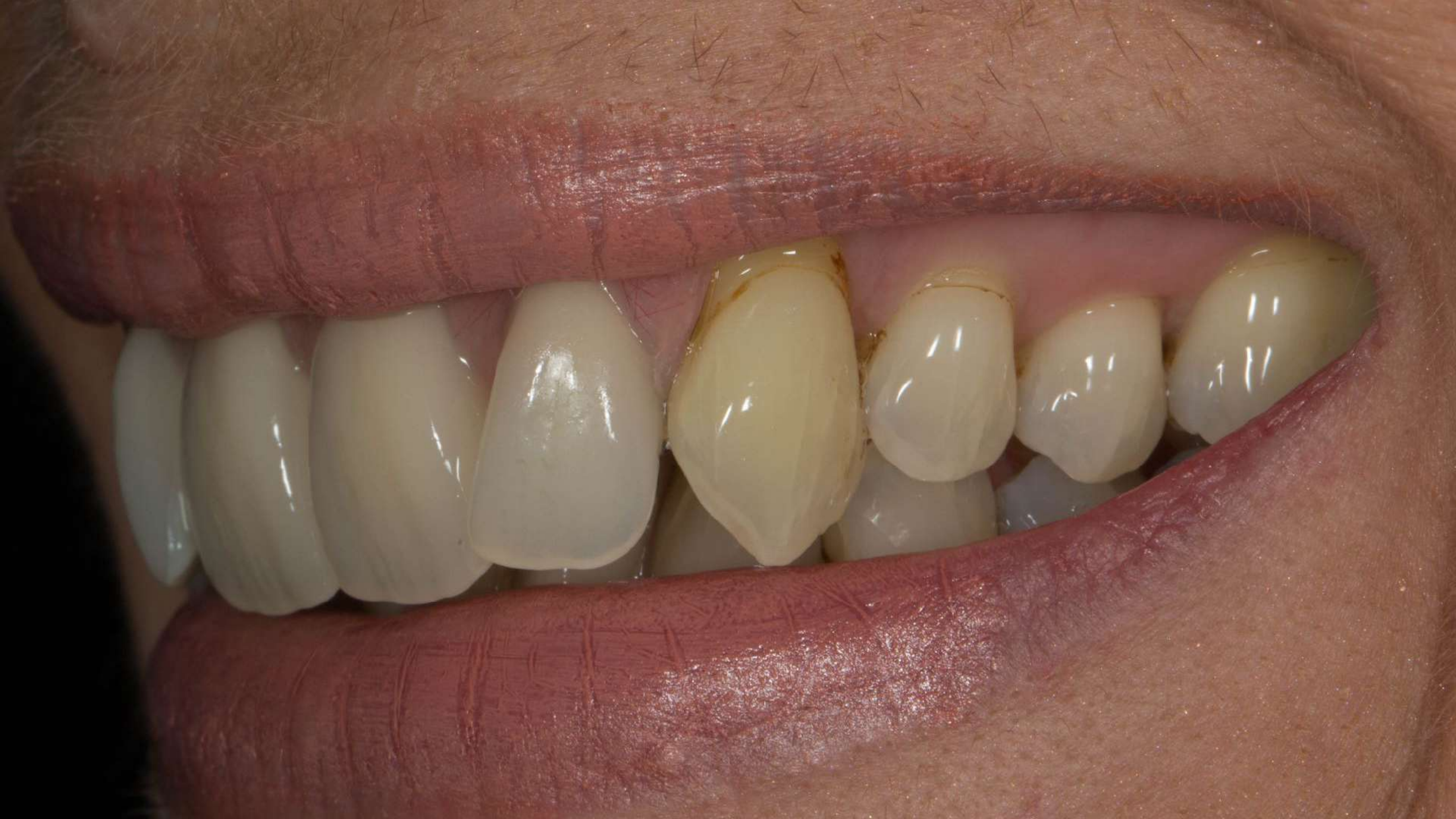
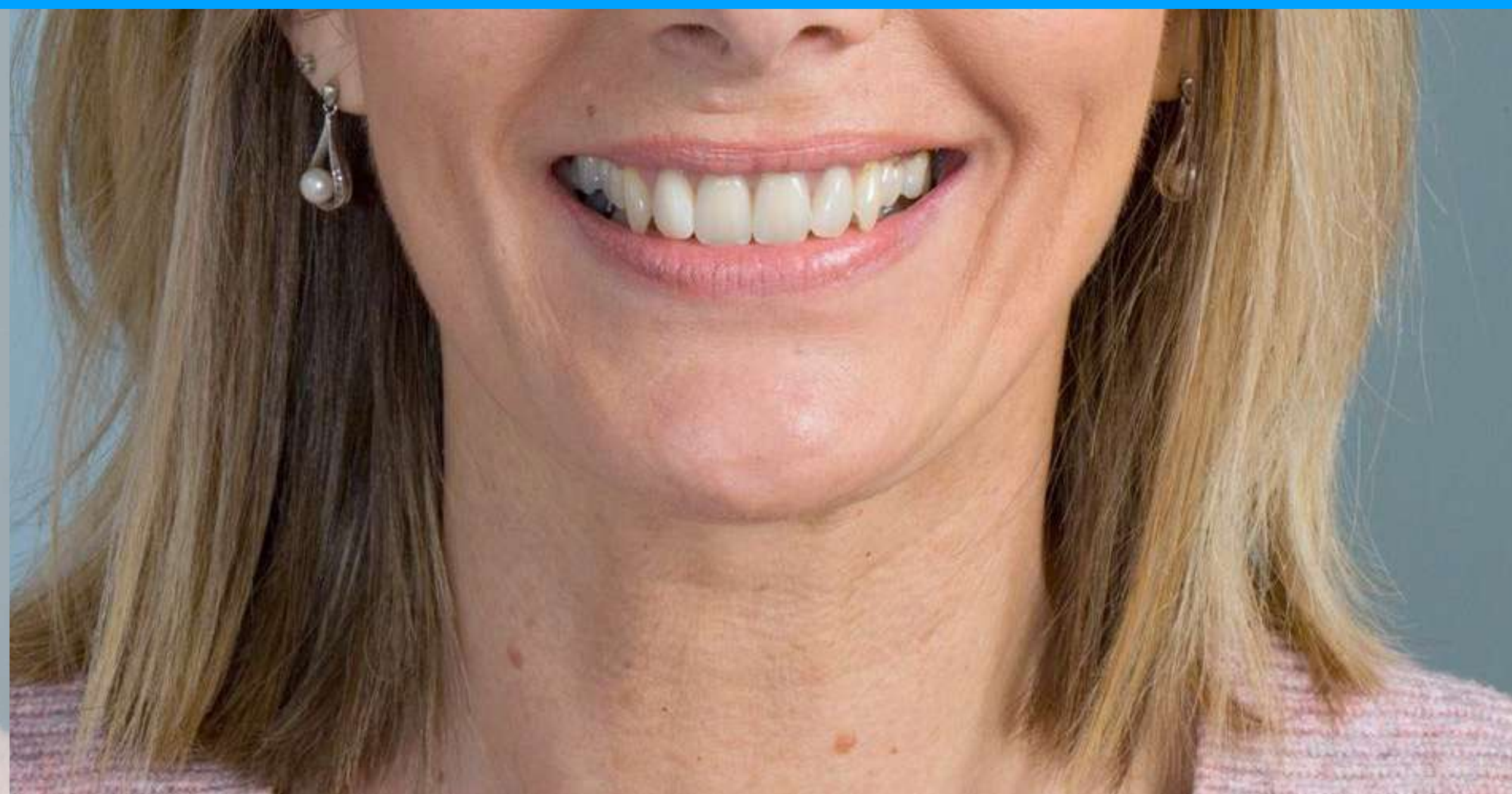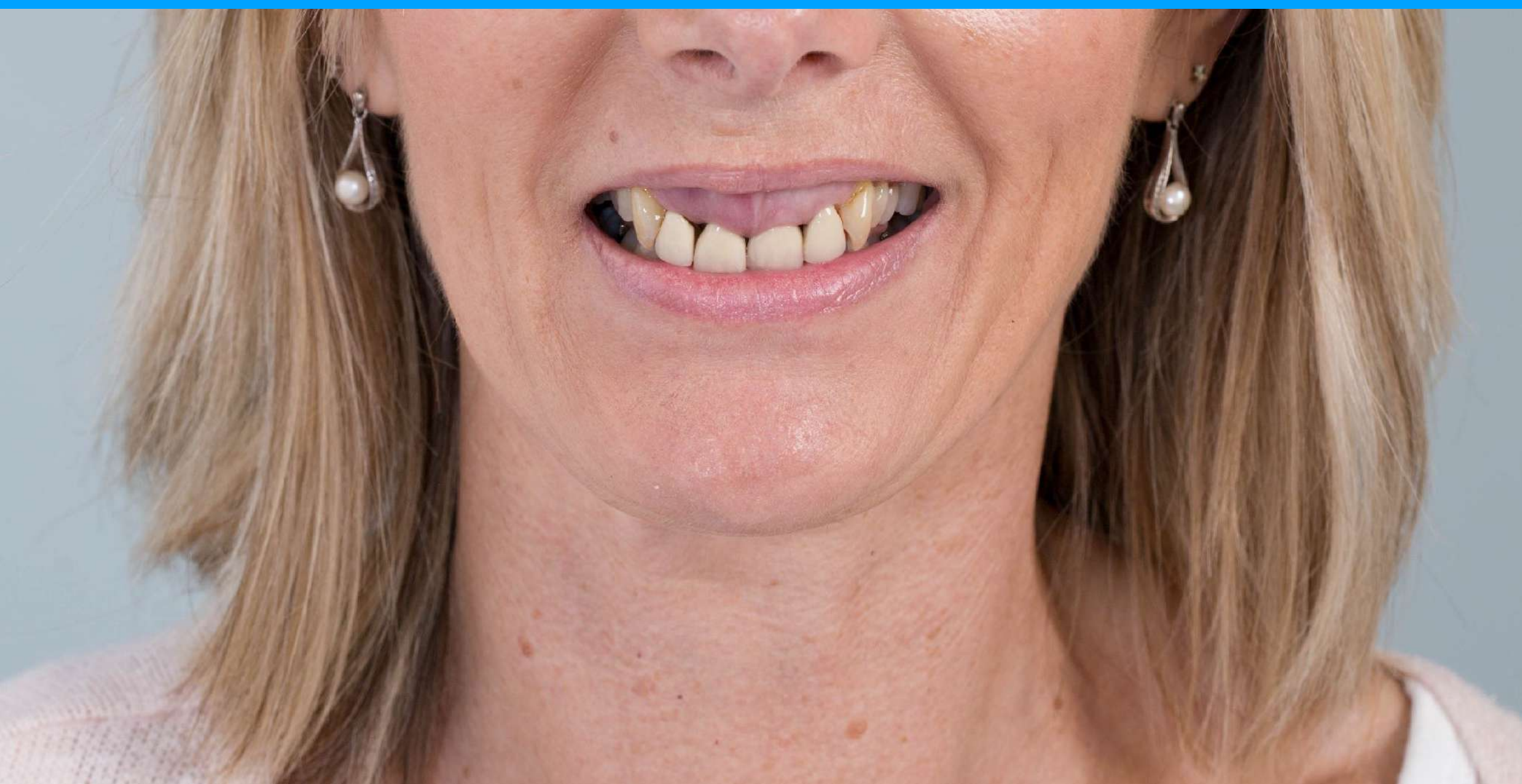


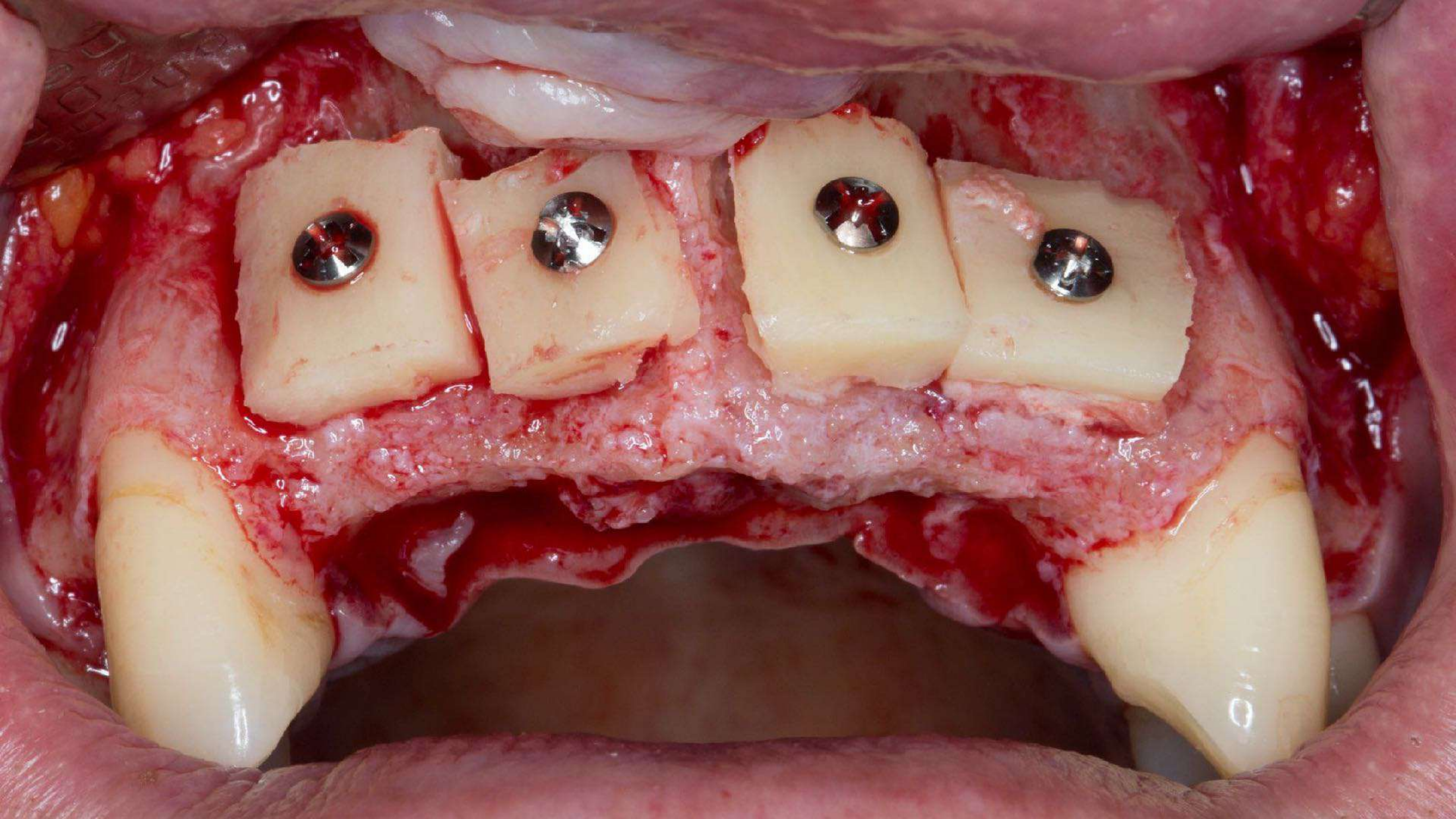


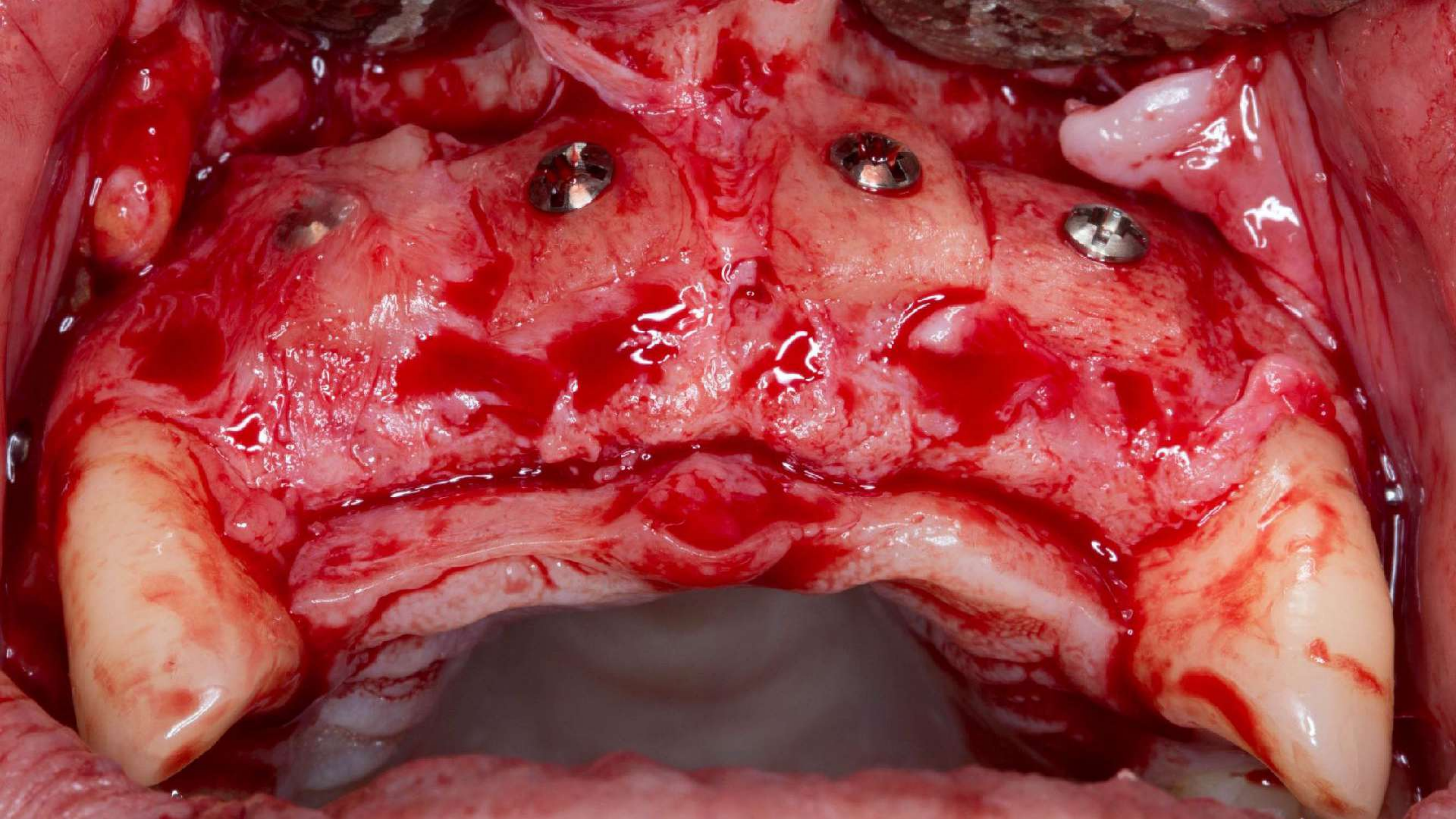


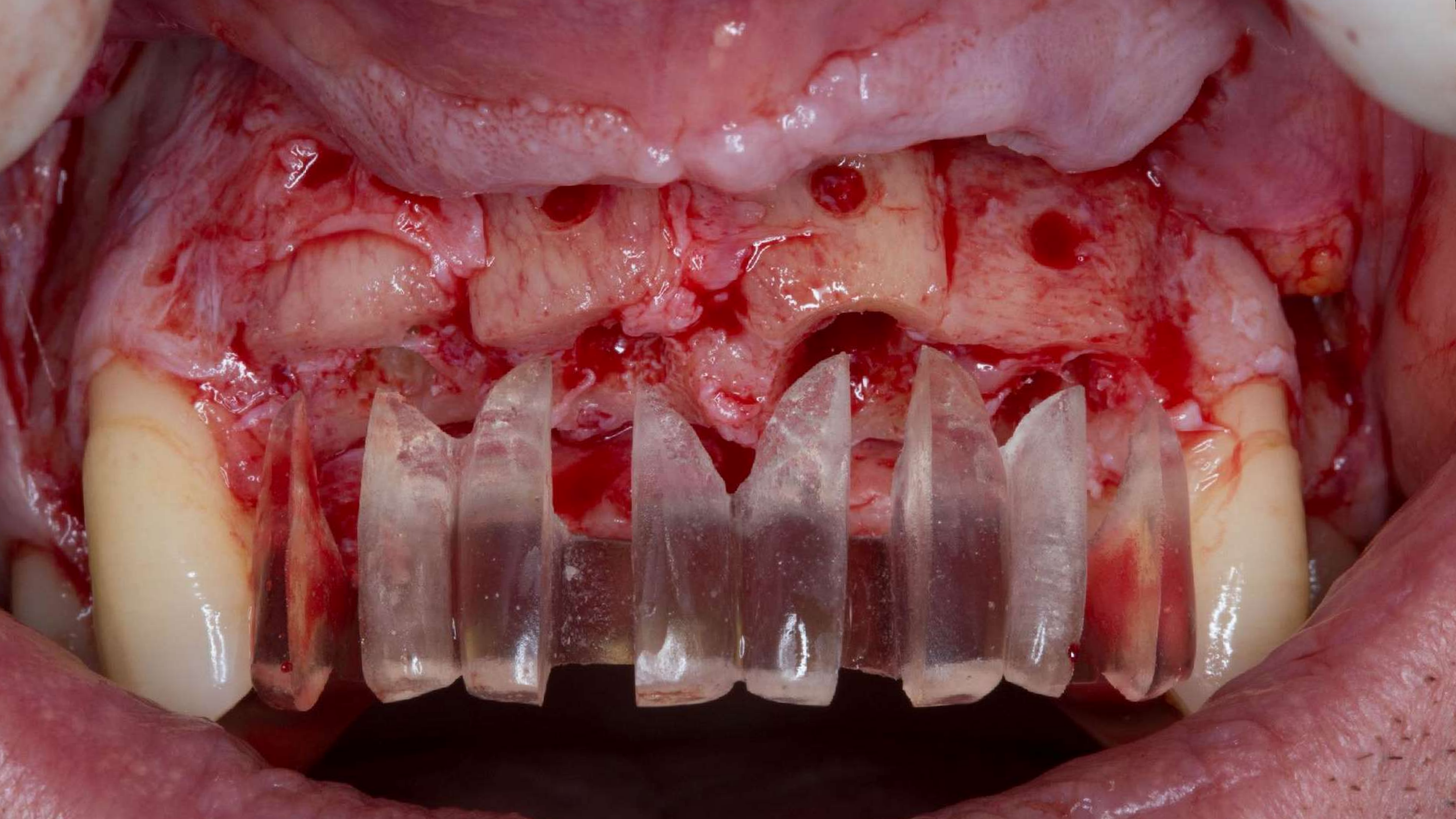


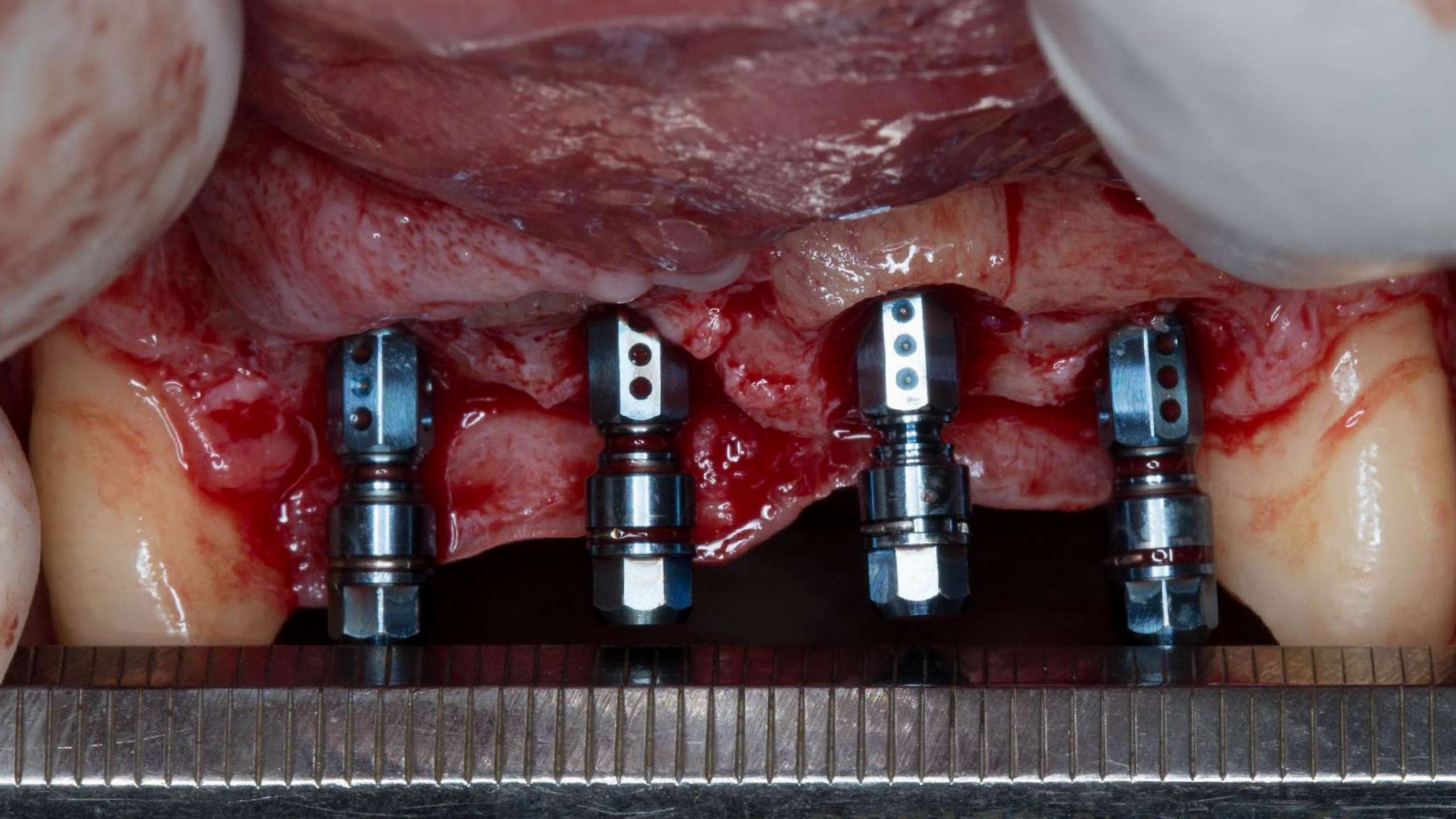





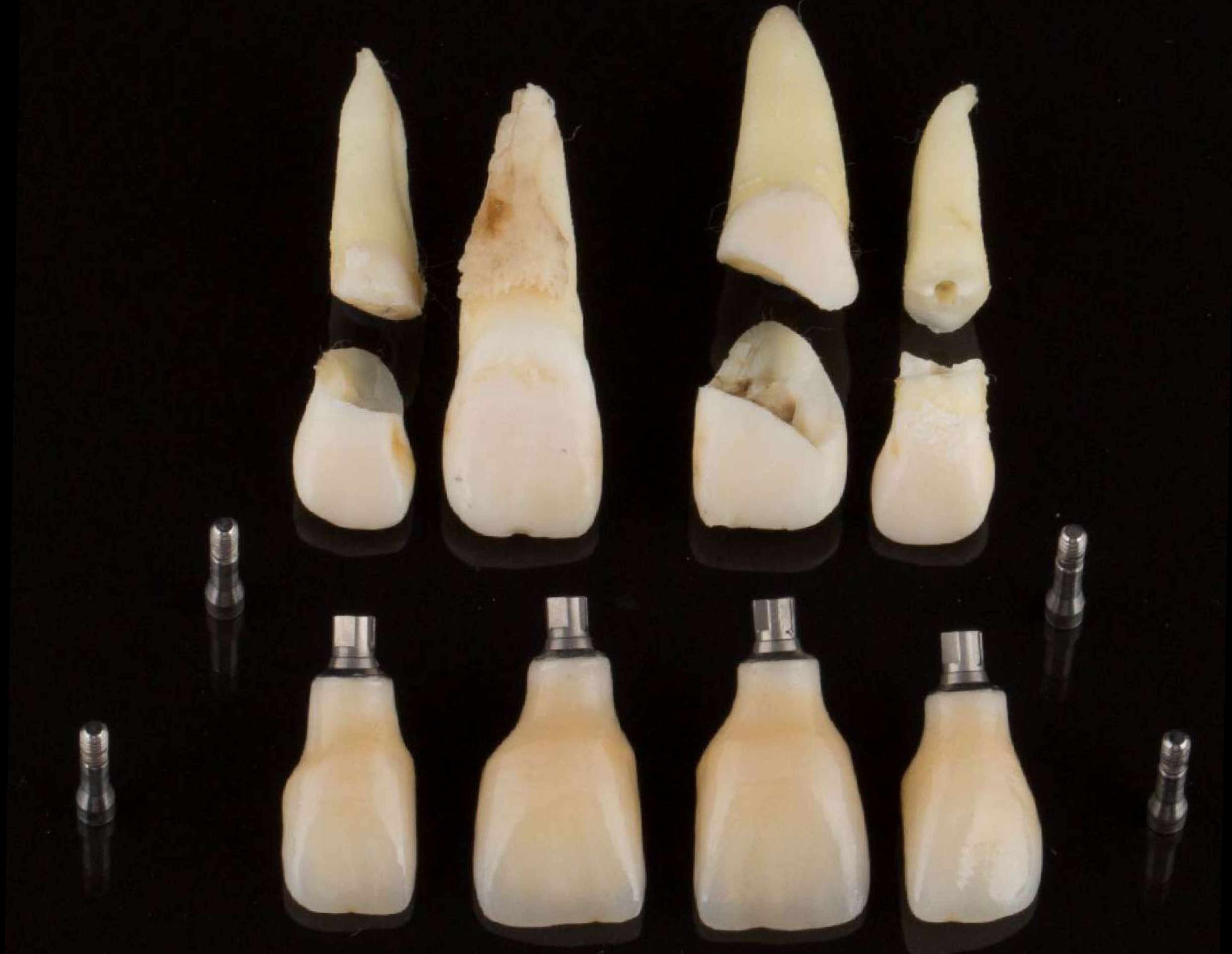


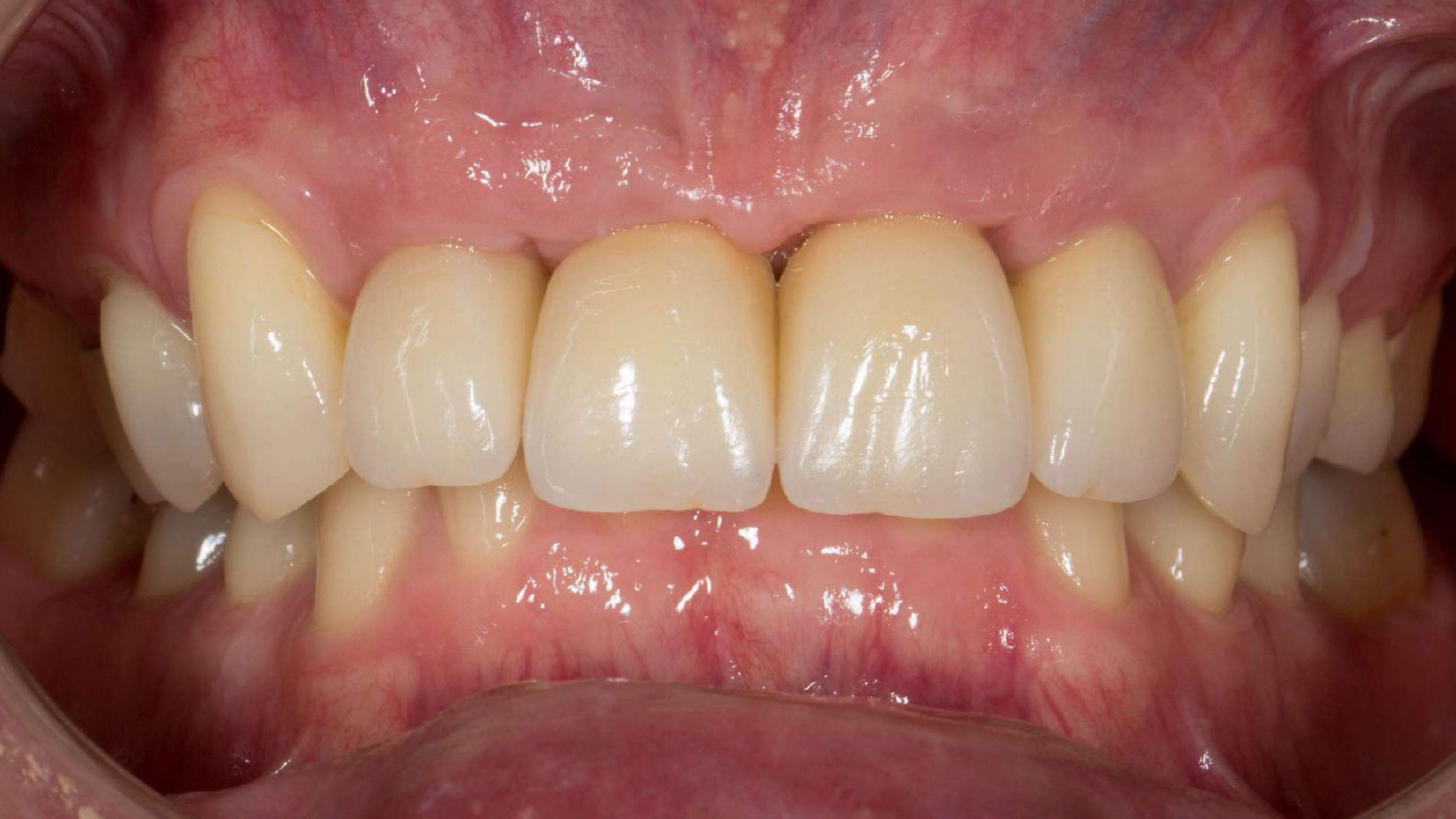


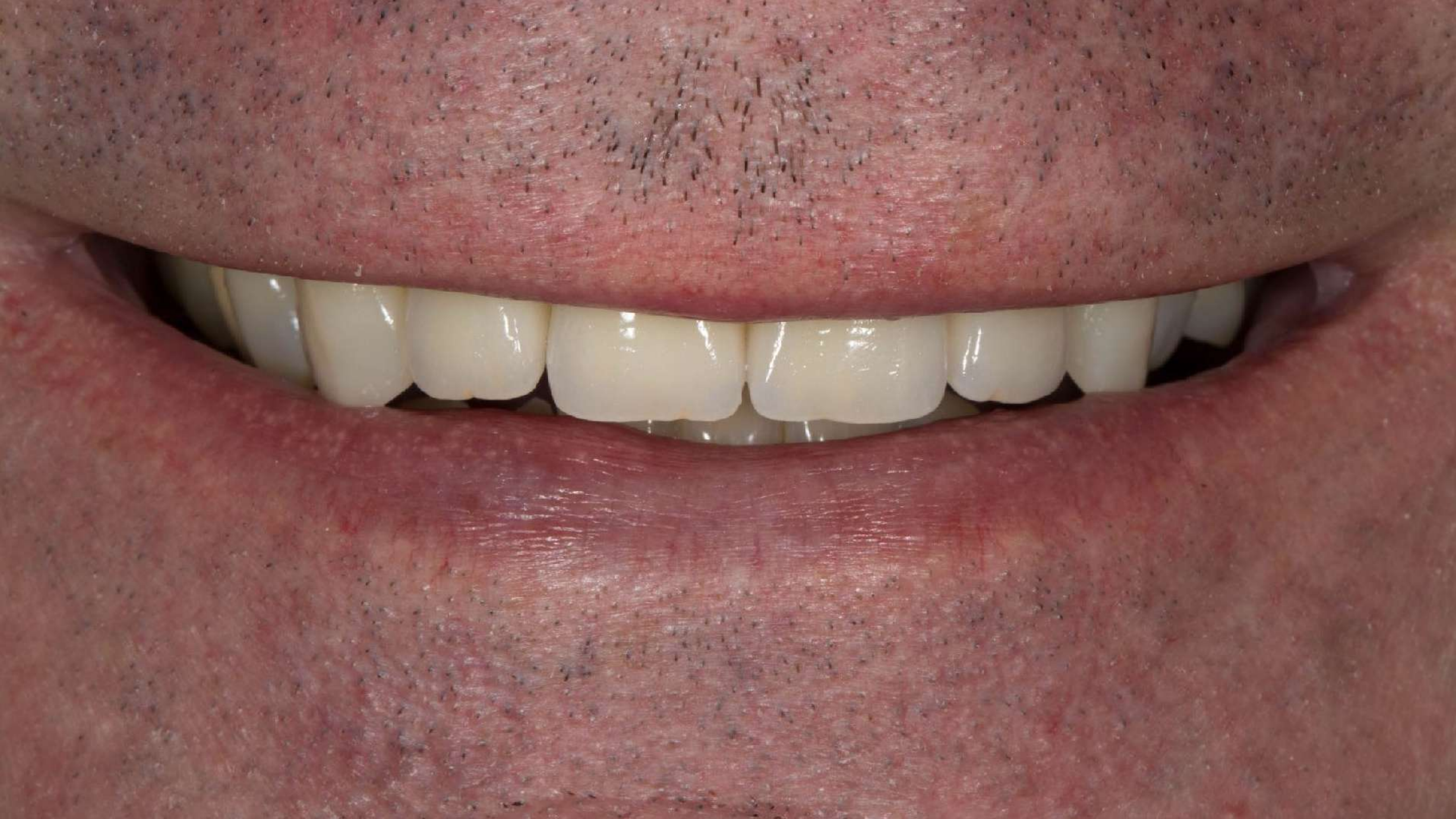




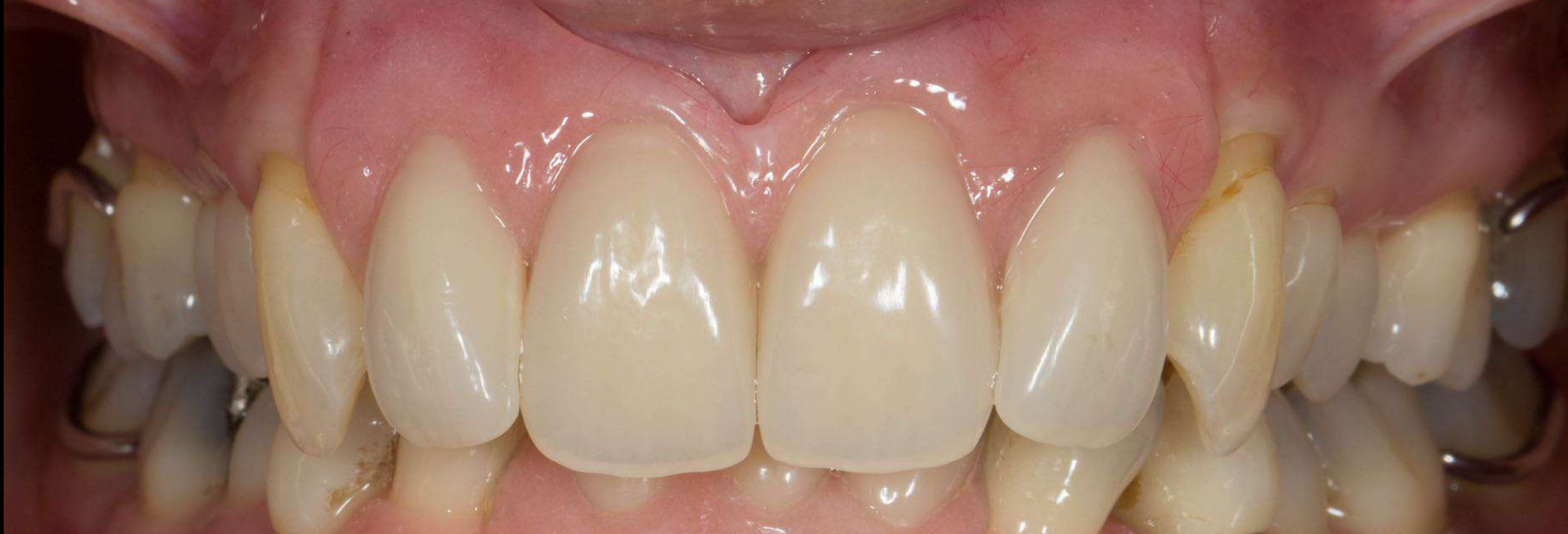

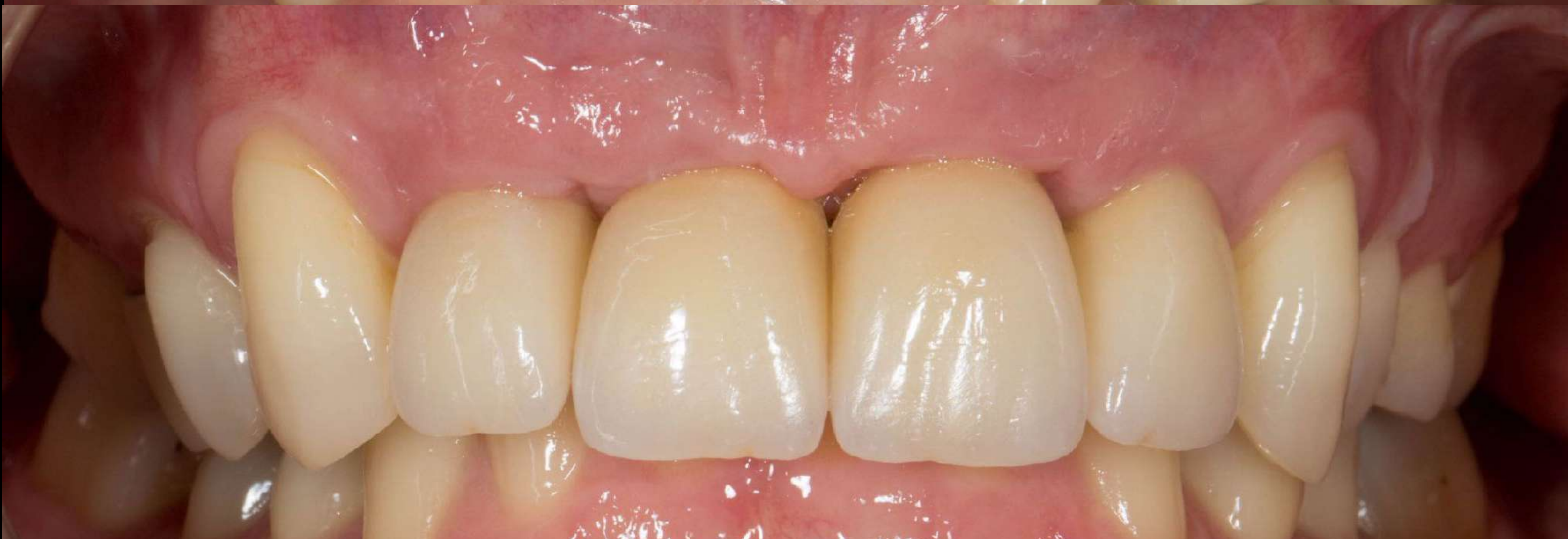Denture



Implant
crowns



A massive thank you!

A large group of approximately 15-20 people, mostly men, are gathered in a clinical or dental office setting. They are all smiling and waving their hands at the camera. Some are wearing dental scrubs (white, blue, and teal), while others are in casual or business-casual attire. The background shows dental equipment, including a large overhead light fixture and a sink area. The overall atmosphere is positive and celebratory.

Can't wait to get back to doing this!
education@finlaysutton.co.uk